

Use of the HIVAMAT® 200 with manual lymphatic drainage in the management of lower-limb lymphoedema and lipoedema

Isabel Teo, Anna Coulborn, DA Munnoch

Key words

HIVAMAT®200, manual lymphatic drainage; lipoedema; lymphoedema; oedema

Isabel Teo is specialist registrar in plastic surgery, Ninewells Hospital, Dundee, Scotland; Anna Coulborn is tissue viability nurse and lymphoedema nurse specialist, Eastbourne Wound Healing Centre, Eastbourne, UK; DA Munnoch is consultant plastic surgeon, Ninewells Hospital, Dundee, Scotland

Declaration of interest: None.

Lower limb oedema is attributed to increased fluid in the extracellular space, which may be due to local or systemic causes. Local causes include lymphoedema, lipoedema, deep vein thrombosis and venous disease. Systemic causes include cardiac failure, renal failure, hypoalbuminaemia and medications such as calcium-channel blockers, steroids and anti-inflammatory drugs (Gorman et al, 2000). The principles of oedema treatment are to first manage the precipitating cause if possible. If there is persistent fluid in the limbs, however, methods to encourage fluid to move back into the venous or lymphatic circulation are advocated (Gorman et al, 2000).

Lymphatic drainage

Manual lymphatic drainage (MLD) facilitates the drainage of accumulated extracellular fluids via the collecting lymphatic pathways. MLD is a standard lymphoedema treatment modality (Ezzo et al, 2015). Performed by an appropriately

Abstract

Background: Manual lymphatic drainage (MLD) is a well-recognised and traditional treatment modality for oedema. HIVAMAT® 200 is a novel device that uses an intermittent electrostatic field to stimulate blood and lymphatic flow, thereby reducing oedema. This study aims to compare the effects of MLD alone to HIVAMAT® 200 plus MLD. **Method:** Three females with lipoedema and two males with lymphoedema were recruited. The larger leg was treated with HIVAMAT® 200 plus MLD and the contralateral limb with MLD only over the course of 3 weeks. Efficacy of treatment was determined with measurements of leg volumes and high-definition ultrasound to analyse oedema. **Results:** The mean reduction in volume for the HIVAMAT® 200 plus MLD-treated legs was 902 ml (SD 793 ml) and the mean reduction in MLD-only legs was 707 ml (SD 630 ml). While there was greater improvement in the HIVAMAT® 200-treated limb, this was not statistically significant ($p=0.06$). Using high-definition ultrasound to analyse oedema, the limbs treated with HIVAMAT® 200 plus MLD showed significantly greater reduction in levels of oedema than the limbs treated with MLD alone ($p=0.017$). **Conclusion:** HIVAMAT® 200 reduces lower-limb oedema and is at least as efficacious as MLD in achieving volume reduction. Prospective studies with larger numbers of participants are required to further evaluate this.

qualified practitioner, the affected area is manually massaged in a distal to proximal direction to encourage excess fluid to return to the circulation system (Ezzo et al, 2015). The frequency and duration of treatment is tailored to individual patients. Compression, in the form of bandages or garments, is applied in between sessions and thereafter to minimise the re-accumulation of fluid.

MLD is hypothesised to stimulate lymphatic contractile function by tissue manipulation, and hence promote the clearance of lymph fluid from the affected areas. Tan et al (2011) injected indocyanine green intradermally into subjects and compared the pre-MLD lymphatic contractile function against post-MLD lymphatic function in healthy and lymphoedematous limbs. They found that the average lymph velocity increased in both lymphoedematous and asymptomatic limbs, which supports the hypothesis that MLD stimulates lymphatic contractile function.

HIVAMAT® 200

HIVAMAT® 200 (which stands for HIstological VARIable MAnual Technique), which is made by Physiomed Elektromedizin AG, is also known as Deep Oscillation® therapy. A special design makes it possible, using electrostatic attraction and friction, to produce mechanical vibrations in the body, not only at the skin surface but also in deeper tissues (Brenke and Siems, 1996; Boisnic and Branchet, 2013). The frequency can be varied within the 5–250 Hz range. The therapist applies an electrode to his or her own arm while the patient holds a small titanium bar, which connects both individuals to the equipment (voltage source). There is a vinyl film between the applicator and/or vinyl gloves are used. The patient functions as a dielectric. This results in a weakly conducting capacitive layer between the contact surfaces. In action, pulsed electrostatic attractions draw and pull the tissue towards the applicator/gloved hand and release it at the rhythm of the chosen frequency. The therapist sets the

pressure gradient, speed and direction of the movements. The patient can treat him- or herself with applicators if appropriate.

The treatment procedure is characterised by minimal external mechanical effect, which allows it to be used in cases of acute pain, soft tissue trauma and in the treatment of wounds. Numerous pilot studies have demonstrated pain reduction, minimisation of oedema, antifibrotic and anti-inflammatory effects, as well as improved wound healing (Gasbarro et al, 2006; Fistetto et al, 2011; Hernández Tápanes, 2012; Boisnic and Branchet, 2013). HIVAMAT is commonly used for the treatment of lymphoedema (Jahr et al, 2008). Deep Oscillation® has been shown by echographic image recording to penetrate to a depth of 8 cm (Hernández Tápanes et al, 2010).

Aim

The aim of this study was to evaluate whether HIVAMAT® 200, combined with MLD, is useful as an adjunctive treatment modality in lower limb swelling compared to the efficacy of MLD alone.

Methods

Patients who were referred for therapist-led treatment of lower limb swelling were considered for this study. The inclusion criteria included:

- Age >18 years
- Lower-limb swelling (unilateral or bilateral)
- The request for the treatment of excess fluid volume
- Informed consent to participate for the full 3 weeks of the study.

Exclusion criteria included previous treatment of any form on the participants' limbs. This study was approved by the local ethics committee.

The first five consecutive patients fulfilling the criteria were three females (lipoedema) and two males (lymphoedema). In each case, one leg was treated with HIVAMAT® 200 plus MLD, and the other with MLD over the course of 3 weeks. Efficacy of treatment was determined by measurements of leg volumes and high-definition ultrasound (HDU) scanning to analyse oedema.

Limb volume measurements and HDU scans to measure oedema were taken before, during and at the end of treatment (designated time 0, end of week 1 and end of week 3, respectively). Objective leg

Table 1. Effect of HIVAMAT® 200 plus manual lymphatic drainage on the study leg versus manual lymphatic drainage alone in the control leg in the 5 study subjects.

Subject	Age	Gender	Diagnosis	Study leg volume (cc)		Control leg volume (cc)	
				Time 0	Final	Time 0	Final
1	57	M	Right leg lymphoedema secondary to complications following right inguinal hernia and orchidectomy	12,402	12,190	12,351	10,911
2	56	F	Lipoedema	15,339	14,831	13,581	13,568
3	52	M	Primary lymphoedema of the right leg	16,940	15,217	13,068	12,241
4	47	F	Lipoedema	14,477	13,557	12,851	12,746
5	43	F	Lipoedema	16,354	14,781	15,593	14,443

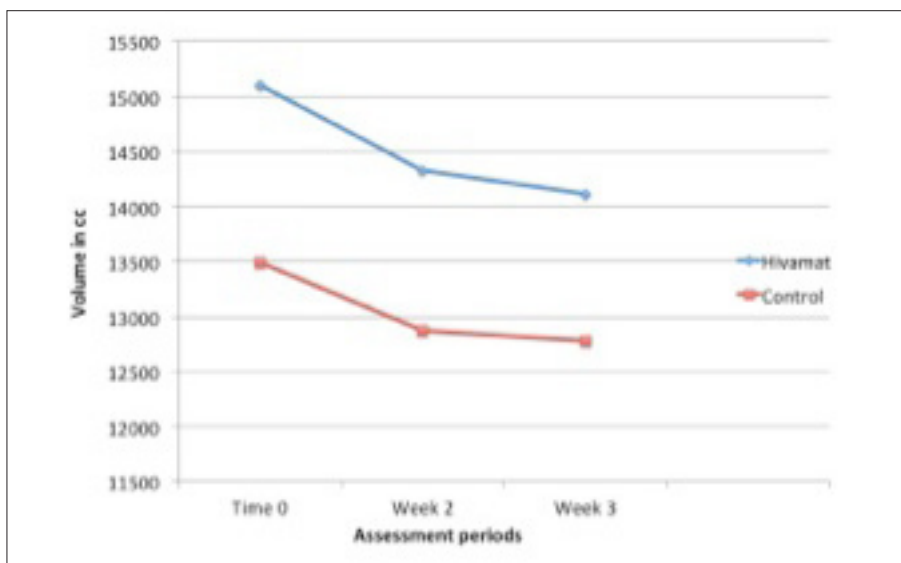


Figure 1. Mean volume of limbs treated with HIVAMAT® 200 plus manual lymphatic drainage versus manual lymphatic drainage only (control) before (Time 0), during and at the end of the assessment period.

volumes were determined by measuring the circumference of each limb at 4 cm intervals, beginning from the malleolus and advancing proximally to the groin. Truncated-cone measurements were utilised and the volume of the leg between two adjacent measurements (a segment) was calculated using the following formula to give a volume in millilitres:

$$V = 4/12 \pi (C11 + C11 + C22)$$

where V is the volume of a segment, and C1 and C2 are the measured adjacent circumferences.

The entire limb volume is calculated by adding up the volumes of all the segments. This is a validated method of limb volume measurement commonly used in clinical practice (Ridner et al, 2007; Schaverien et al, 2012; Teo and Munnoch, 2015).

The HDU scanner (Episcan Longport Inc; with a frequency of 20 MHz, which gives an axial resolution at 65 µm) is an assessment tool that provides quantitative information on the fluid content of the epidermis, dermis and subcutis. Each HDU scan is analysed using a form of pixel distribution analysis whereby pixels below certain intensities are classed as low echogenic pixels (LEPs). The ratio of LEPs to total pixel (TP) count reflects the dermal water content. This provides a quantitative assessment of the level of oedema in the tissue (Gniadecka, 1996; Gniadecka and Quistorff 1996). The scan is taken consistently at the mid thigh and mid calf, for values of the proximal and distal legs, and the distal and proximal readings averaged to represent the average LEP:TP ratio for the entire limb.

The larger leg in all patients was assigned

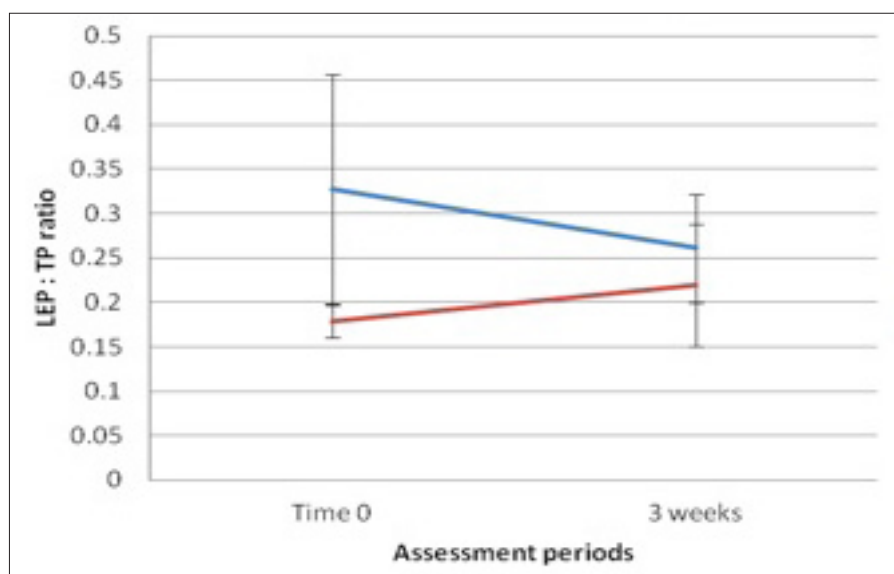


Figure 2. Analysis of the low echogenic pixels to total pixels (LEP:TP) ratio reflecting tissue oedema in the proximal legs. The LEP:TP ratio for HIVAMAT® 200 plus manual lymphatic drainage (blue line) showed a reduction in oedema, while manual lymphatic drainage only (red line) showed a slight increase in oedema.

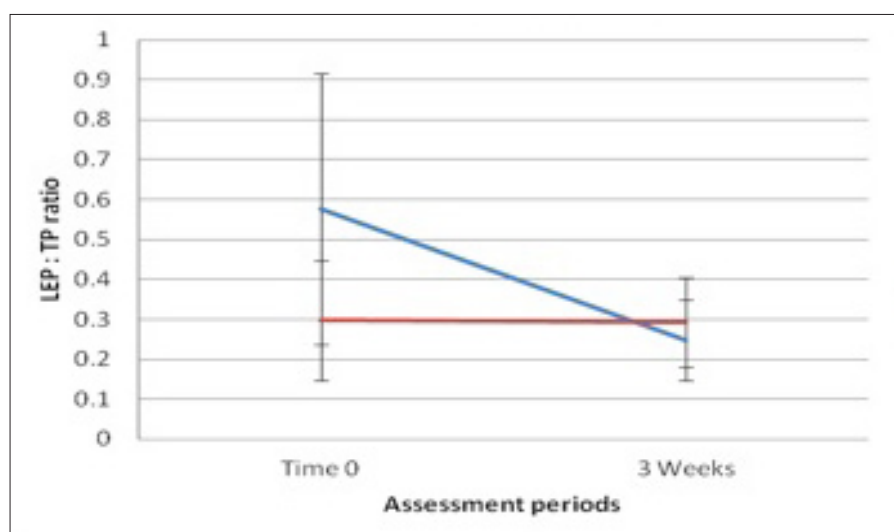


Figure 3. Low echogenic pixels to total pixels (LEP:TP) ratios of the distal leg demonstrating greater reduction of oedema in the distal limbs treated with HIVAMAT® 200 plus manual lymphatic drainage (blue line) compared to manual lymphatic drainage only (red line).

to receive HIVAMAT® 200 plus MLD and the smaller contralateral leg MLD only. Treatments were administered twice-weekly for the 3 weeks. HIVAMAT® 200 was applied at each session for 25 minutes at 200 Hz. Thigh-length compression garments (Class 2 or 3) were given to patients, to be worn continuously on both legs in the interim. All data were analysed using SPSS V20.

Results

Mean patient age was 51 years (range 43– 57 years). All three females had

lipoedema, one male had primary lymphoedema and one had secondary lymphoedema following complications after a right hernia repair and right orchidectomy. The volumes of each study leg versus the control (MLD-only) leg over the 3 weeks of treatment are given in *Table 1*.

The mean reduction in volume for the HIVAMAT® 200 plus MLD legs was 902ml (standard deviation 793 ml) and MLD-only legs was 707ml (standard deviation 630 ml). While there was greater improvement in the HIVAMAT®

200 plus MLD limbs (*Figure 1*), this did not reach statistical significance ($p=0.06$).

The HDU scans showed that the mean LEP:TP ratios improved for the proximal and distal legs, indicating a reduction in oedema in the HIVAMAT® 200 plus MLD legs. Interestingly there was an increase in LEP:TP for the legs treated with MLD only (*Figure 2*) in the proximal leg. *Figure 3* shows the LEP:TP ratios for the distal (HIVAMAT® 200-treated) leg, demonstrating greater reduction in oedema in the treatment this leg compared MLD only.

The overall LEP:TP ratio for each limb (taking the mean of the distal and proximal reading) and change from time 0 to week 3 was compared in the HIVAMAT® 200 plus MLD group versus the MLD-only group using t-test analysis. This showed a statistically significant improvement in the reduction of oedema in the HIVAMAT® 200 group ($p=0.017$).

Discussion

Lymphoedema and lipoedema

Lower-limb swelling can occur for a multitude of reasons, and can generally be attributed to increased deposition of fluid and/or fat. Lymphoedema is a common cause of lower limb swelling, in which an abnormality of lymphatic flow results in pooling of protein-rich lymph fluid in the interstitial tissues (Gorman et al, 2000). A study across a west London community in 2003, for example, reported a lymphoedema prevalence rate of 1.33/1,000 across all age groups (Moffatt et al, 2003). Lymphoedema may occur following trauma or infection or be secondary to malignancy or oncological treatment, such as nodal surgery or radiotherapy. Lymphoedema may also occur without any identifiable precipitating causes, when it is known as primary lymphoedema.

The standard treatment for lymphoedema is complete decongestive therapy (Huang et al, 2013), also known as decongestive lymphatic therapy, which should be provided by a qualified specialist practitioner (International Society of Lymphology, 2013). Decongestive lymphatic therapy consists of an initial reductive phase and subsequent maintenance phase. The initial phase consists of MLD, multilayer compression bandaging, therapeutic exercises, skin care

and education in self-management. The maintenance phase consists of lifelong self-delivered drainage, skin care and the use of compression garments (Huang et al, 2013).

Lipoedema is a bilateral and symmetrical limb condition that typically results in enlarged, painful lower limbs, although the upper limbs may be affected as well. It almost exclusively affects women and causes gross enlargement of the entire lower limb, with characteristic sparing of the ankles and feet (Langendoen et al, 2009). The aetiology is unknown but is postulated to be related to circulating oestrogens, as the onset is often associated with hormonal changes, such as puberty or pregnancy. There is increased deposition of fatty tissue with excess fluid (Langendoen et al, 2009). Földi and Földi (2006) performed an epidemiological study and estimated that 11% of the female population is affected.

The diagnosis of lipoedema is made on clinical grounds as described by Wold et al (1951):

- Almost exclusive occurrence in females
- Bilateral and symmetrical enlargement with minimal involvement of the feet
- Minimal pitting oedema
- Tenderness on pressure
- Easy bruising
- Persistent enlargement after elevation of the extremities or weight loss.

Assessing volume reduction treatment

There are numerous methods to assess response to volume reduction treatment and these include patient-reported outcome measures, such as reduction in heaviness and pain scores, episodes of cellulitis or quality of life questionnaires (Lopez Penha et al, 2014; van de Pas et al, 2015). More objective methods of assessing the success of treatment include volume measurement and ultrasound scans (Boyages et al, 2015).

Many techniques for volume measurement have been described. Magnetic resonance imaging, laser plethysmography (Stephan et al, 2000), computer-aided design and hand scanners are some of the current methods for limb volume measurement. The water displacement method is based on Archimedes' principle and involves

immersing the entire limb in water and calculating the volume of displaced fluid. This is considered the gold standard against which other volume techniques are compared (Sander et al, 2002; Karges et al, 2003; Ng and Munnoch, 2010) but has practical limitations with regards to equipment and patient factors. Girth measurement with a measuring tape is simple, quick, cost-effective and acceptable to patients. Karges et al (2003) compared water displacement and girth measurement and found both methods to be consistent and accurate. The authors use girth measurements in their clinical practice, find it clinically reliable, and hence suitable for the intentions of this study.

HDU scanning is a method of analysing the water content in tissues. It is simple, pain-free and provides a quantitative assessment of the level of oedema. The scan typically shows red pixels, which indicate tissue oedema (Figure 4), and blue pixels (Figure 5), which indicate healthy tissue. As mentioned in the methods section, each tissue scan is automatically analysed using a form of pixel distribution analysis, whereby pixels below a certain intensity are classed as LEP. The ratio of LEP:TP ratio has been shown to reflect dermal water content.

HIVAMAT 200's therapeutic Deep Oscillation® effects create cyclic movement through the entire depth of soft tissue from the skin, subcutaneous fat and muscles through to blood vessels and lymphatics (Fistetto et al 2011). This stimulates the mechanical pumping and redistribution of fluids. Deep Oscillation® is designed as an adjunct to surgical or other wound healing, sports medicine and respiratory diseases (Corneaux, 2011). Reinhold et al (2014) performed a study on 40 patients following osteosynthesis procedures on the extremities and spinal column. Patients were randomised to either Deep Oscillation® therapy or control. The found a significant pain-alleviating effect with Deep Oscillation®. Boisnic and Branchet (2013) conducted a clinical study of 20 subjects with periorbital bags or dark circles. They concluded that Deep Oscillation therapy was effective in reducing both dark circles and bags by an average of 40%. This was determined by

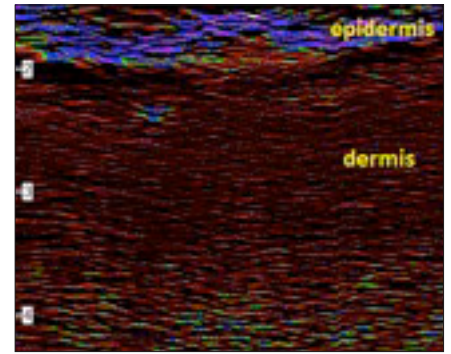


Figure 4. High-definition ultrasound scan showing a relative excess of red pixels compared to blue pixels, indicating oedema.

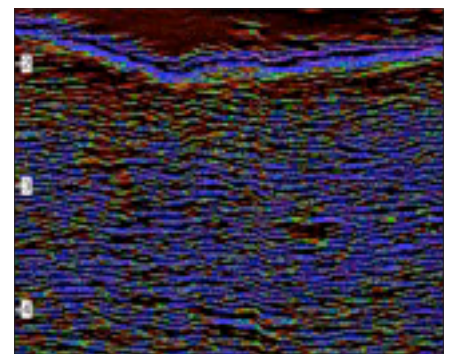


Figure 5. High-definition ultrasound scan showing reduction in red pixels and increase in blue pixels compared to Figure 4, indicating a reduction in oedema.

photography and dermatological scores, as well as ultrasound analysis. Jahr et al (2008) randomised 21 patients who had secondary lymphoedema of the breast following cancer treatment to either MLD supplemented with Deep Oscillation, or to MLD alone. They found that Deep Oscillation plus MLD was significantly better for relieving pain and swelling than MLD alone. Gasbarro et al (2006) analysed the effects of HIVAMAT 200 on the limbs of 20 patients and achieved a remarkably significant reduction in the circumference of the limbs and in the subcutis thickness. Other studies have found HIVAMAT 200 to be useful in the treatment of sports injuries, burns and epicondylitis (Brenke and Siems, 1996; Hernández Tápanes et al, 2010; Aliyev et al, 2012).

Limitations

There are several drawbacks to this study. The patient numbers are small and the assignment of the larger leg to HIVAMAT 200 plus MLD and smaller leg to MLD only incorporates a level of bias. While

both lipoedema and lymphoedema cause excess leg volume and oedema, the former is a bilateral condition and the latter often unilateral, making comparisons of the treatment and control leg distinct in these two diseases. The true efficacy of any treatment is highly reliant on patient compliance and the use of garments in the long term, which cannot be evaluated in a 3-week time period. Nonetheless, this pilot study provides valuable information on deep oscillation therapy.

Conclusion

This is the first prospective study comparing HIVAMAT 200 plus MLD versus MLD only in the lower limbs. Although our results suggest greater efficacy with Deep Oscillation therapy for volume reduction, this did not reach statistical significance. The data do, however, show that HIVAMAT 200 was more effective in reducing oedema than standard MLD alone. The results of this pilot study are encouraging, and HIVAMAT 200 could be a useful addition to practitioners' armamentarium when treating oedematous limbs.

Acknowledgements

AC designed the initial study and undertook treatments. IT and DAM reviewed all data, analysed the results and wrote the paper. The authors would like to thank Dr S Young who undertook the ultrasound analysis.

References

- Boisnic S, Branchet MC (2013) Anti-inflammatory and draining effect of the Deep Oscillation® device tested clinically and on a model of human skin maintained in survival condition. *Eur J Dermatol* 23(1): 59–63
- Boyages J, Kastanias K, Koelmeyer LA et al (2015) Liposuction for advanced lymphedema: a multidisciplinary approach for complete reduction of arm and leg swelling. *Ann Surg Oncol* 22(Suppl 3): 1263–70
- Benke R, Siems W (1996) Adjuvante Therapie beim Lymphödem. *Akt Lymphol* 20: 25–9. (Combination of lymphatic drainage together with HIVAMAT® 200 significantly better results than without DEEP OSCILLATION)
- Corneaux Z (2011) Dynamic fascial release and the role of mechanical/vibrational assist devices in manual therapies. *J Bodyw Mov Ther* 15(1): 35–41
- Ezzo J, Manheimer E, McNeely ML et al (2015) Manual lymphatic drainage for lymphedema following breast cancer treatment. *Cochrane Database Syst Rev* 21;5: CD003475. doi: 10.1002/14651858.CD003475.pub2
- Fistetto G, Iannitti T, Capone S, Torricelli F, Palmieri B (2011) Deep Oscillation: therapeutic-rehabilitative experiences with a new electrostatic device. *Minerva Med* 102(4): 277–88 [Article in Italian]
- Földi M, Földi E (2006) Lipedema. In: Földi M, Földi E, eds. *Textbook of Lymphology*. Elsevier, Munich: 417–27
- Gasbarro V, Bartoletti R, Tsolaki E et al (2006) Role of HIVAMAT® (Deep Oscillation) in the treatment of lymphoedema of the limbs. *The European Journal of Lymphology* 16(48): 13–5
- Gorman WP, Davis KR, Donnelly R (2000) Swollen lower limb. *BMJ* 320(7247): 1453–6
- Gniadecka M (1996) Localization of dermal edema in lipodermatosclerosis, lymphedema, and cardiac insufficiency. High-frequency ultrasound examination of intradermal echogenicity. *J Am Acad Dermatol* 35(1): 37–41
- Gniadecka M, Quistorff B (1996) Assessment of dermal water by high-frequency ultrasound: comparative studies with nuclear magnetic resonance. *Br J Dermatol* 135(2): 218–24
- Hernández Tápanes S (2012) DEEP OSCILLATION® therapy. Experiences in cervical, lumbago and epicondylitis. San Jose: EdiReh-Latina
- Hernández Tápanes S, Bravo Acosta T, Wilson Rojas R, Fernández Prieto B, Cabrera Morales M (2010) Valor de la Terapia con oscilaciones profundas en la cicatrización de las quemaduras AB. *Rev Cub MFR* 2(1) (Value of deep oscillation therapy in the healing of AB burns) [Article in Spanish] http://bvs.sld.cu/revistas/mfr/vol_2_1_10/mrf02210.htm (accessed 31.03.2016)
- Huang TW, Tseng SH, Lin CC (2013) Effects of MLD on breast cancer-related lymphedema: a systematic review and meta analysis. *World J Surg Oncol* 11:15
- International Society of Lymphology (2013) The diagnosis and treatment of peripheral lymphedema: 2013 Consensus Document of the International Society of Lymphology. *Lymphology* 46(1):1–11
- Jahr S, Schoppe B, Reissauer A (2008) Effect of treatment with low-intensity and extremely low-frequency electrostatic fields (Deep Oscillation) on breast tissue and pain in patients with secondary breast lymphoedema. *J Rehabil Med* 40(8): 645–50
- Karges JR, Mark BE, Stikeleather SJ, Worrell TW (2003) Concurrent validity of upper- extremity volume estimates: comparison of calculated volume derived from girth measurements and water displacement volume. *Phys Ther* 83(2): 134–45
- Langendoen SI, Habbema L, Nijsten TE, Neumann HA (2009) Lipoedema: from clinical presentation to therapy. A review of the literature. *Br J Dermatol* 161(5): 980–6
- Lopez Penha TR, van Bodegraven J, Winkens B et al (2014) The quality of life in long-term breast cancer survivors with breast cancer related lymphedema. *Acta Chir Belg* 114(4): 239–44
- Moffatt CJ, Franks PJ, Doherty DC et al (2003) Lymphoedema: an underestimated health problem. *QJM* 96(10): 731–8
- Ng M, Munnoch A (2010) Clinimetrics of volume measurement in the upper limb. Clinical Review. *Journal of Lymphoedema* 5(2): 62–7
- Reinhold J, Deeva I, Korkina L, Schaper K, Krummenauer F (2014) Randomised pilot study for quantification of benefit from the patient's point of view of deep oscillation treatment in primary wound healing. *Z Orthop Unfall* 152(3): 260–4 [Article in German]
- Ridner SH, Montgomery LD, Hepworth JT, Stewart BR, Armer JM (2007) Comparison of upper limb volume measurement techniques and arm symptoms between healthy volunteers and individuals with known lymphedema. *Lymphology* 40(1): 35–46
- Sander AP, Hajer NM, Hemenway K, Miller AC (2002) Upper-extremity volume measurements in women with lymphedema: a comparison of measurements obtained via water displacement with geometrically determined volume. *Phys Ther* 82(12): 1202–12
- Schaverien MV, Munro KJ, Baker PA, Munnoch DA (2012) Liposuction for chronic lymphoedema of the upper limb: 5 years of experience. *J Plast Reconstr Aesthet Surg* 65(7): 935–42
- Stephan D, Tavera C, Raponky J et al (2000) A new method for lower limb volume measurement – laser plethysmography: comparison with two commonly used methods. *Phlebology* 15(3-4):115–2
- Tan IC, Maus EA, Rasmussen JC et al (2011) Assessment of lymphatic contractile function after manual lymphatic drainage using near-infrared fluorescence imaging. *Arch Phys Med Rehabil* 92(5): 756–64
- Teo I, Munnoch DA (2015) Referral patterns to a surgical lymphedema service: 10 years of experience. *J Plast Reconstr Aesthet Surg* 68(10): 1395–401
- van de Pas CB, Biemans A, Boonen R, Viehoff PB, Neumann H (2015) Validation of the Lymphoedema Quality-of-Life Questionnaire (LYMQOL) in Dutch patients diagnosed with lymphoedema of the lower limbs. *Phlebology* pii: 0268355515586312. [Epub ahead of print]
- Wold LE, Hines EA, Allen EV (1951) Lipedema of the legs; a syndrome characterized by fat legs and edema. *Ann Intern Med* 34(5): 1243–50