


# The use of Prontosan® in combination with Askina® Calgitrol®: an independent case series



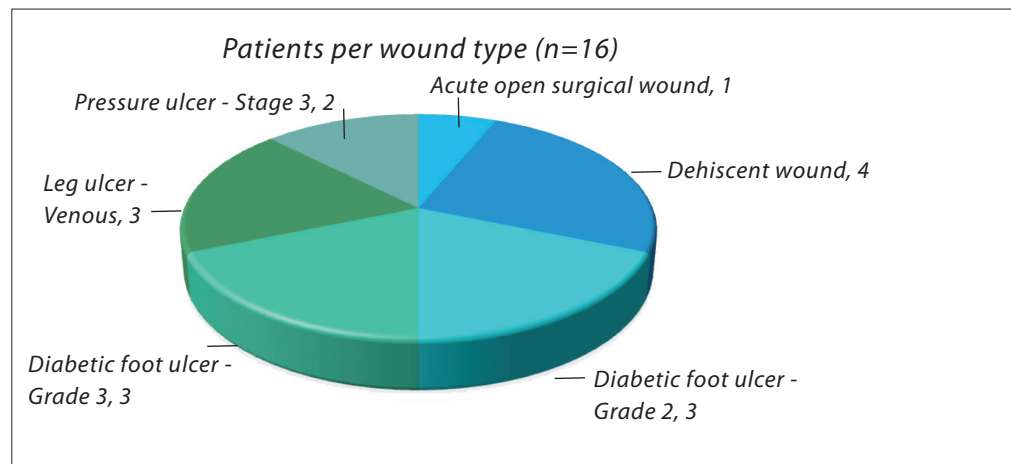
Author:  
Liezl Naude

Many patients with chronic wounds will develop infection (Landis et al, 2007; Sibbald et al, 2011). Worldwide consensus on the specific use of silver antimicrobials recommends that silver dressings should be used initially for a 'two-week challenge' (Wounds International, 2012). Sixteen different individual case studies were carried out to evaluate the efficacy of a biofilm remover/cleanser in gel form, Prontosan® (B Braun), together with the use of an ionic releasing silver alginate, Askina® Calgitrol® Paste (B Braun) or Askina® Calgitrol® Thin (B Braun), when used on infected wounds. This study was completed in an advanced wound management centre in Pretoria, South Africa, during 2016. Selection criteria included wounds showing clinical signs of infection with delayed healing for more than 2 weeks. The study results showed that 50% of the wounds' clinical signs of infection resolved within the 2-week antimicrobial challenge and by week 3, 81% of all clinical signs resolved. Ninety-three per cent of the wounds had improved wound progress and healing, and continued a healing trajectory path. All of the patients experienced a decrease in pain and improvement in their quality of life within 24 hours of their treatment. In conclusion, the use of an anti-biofilm wound cleanser product, such as Prontosan, together with a silver dressing or silver paste as an antimicrobial, demonstrated significant improvement in healing time and resolution of the infection proved to be cost effective within the clinical environment irrespective of the underlying aetiology and adjunctive treatment programme. The shorter healing time and resolution of infection within the 2–4 week period has resulted in a more than 60% cost reduction compared to the cost of treatment prior to application of the protocol.

*Liezl Naude is Wound Management Specialist Eloquent Health & Wellness, Pretoria, SA, Owner & Founder Eloquent Learning Health, Past President Wound Healing Association of Southern Africa, EXCO member World Alliance of Wound and Lymphoedema Care*

**M**any patients with chronic wounds will develop infection. Antimicrobial resistance and multiple drug resistance are an increasing problem across the globe and more and more mention is made of biofilm. Worldwide consensus recommends that silver dressings should be used initially for a "two-week challenge" (World Union of Wound Healing Societies [WUWHS], 2008; 2016; Wounds International, 2010). We know that antimicrobial and multi-drug resistance is increasing within the global healthcare landscape. This is of particular importance in the treatment of chronic, hard-to heal wounds where current

figures according to the World Union of Wound Healing Societies (WUWHS) put the presence of biofilm in 60%–100% of non-healing wounds (Wounds International, 2016). The management of biofilm and infection in chronic wounds is a primary objective of wound care. This, however, remains to be a complex and multi-faceted task (WUWHS, 2008; Wounds International, 2012; 2013). Biofilms can be defined as complex, heterogeneous, dynamic communities containing a multitude of bacteria and fungi (Wounds International, 2010). Within this community they synthesise and secrete a protective matrix, which has high levels of tolerance to antibodies,



**Figure 1.** Patients per wound type.

antibiotics, disinfectants and phagocytic inflammatory cells; thus increasing the level of difficulty in getting rid of the biofilm (Wounds International, 2010; 2016; Sibbald et al, 2015).

It is also important to remember that biofilms cannot be seen by the naked eye, so reliance on patient symptoms and history is important, which also adds to the multi-faceted complexity. By ensuring early treatment and prevention of biofilm formation with the use of regular debridement of chronic wounds and with the use of anti-biofilm products and antimicrobial dressings, chronic wounds are enabled to heal significantly faster (Wounds International, 2010; Sibbald et al, 2011; 2015). A study was undertaken at an out-patient wound care centre in Pretoria, South Africa, in order to test the application of the international consensus on the treatment of infected wounds by removing biofilm with the use of a surfactant cleanser and applying a silver antimicrobial dressing.

### Aim

The following case studies were carried out to evaluate the efficacy of a biofilm remover/cleanser in gel form — Prontosan® (B Braun) — together with the use of an ionic releasing silver alginate — Askina® Calgitrol® Paste (B Braun) or Askina® Calgitrol® Thin (B Braun) — when used on infected wounds (n=16).

### METHODS

Sixteen different individual cases were evaluated in an Advanced Wound Management Centre in Pretoria, South Africa in 2016. Patients selected for the study were from a wider demographic and included both male and female patients, underlying conditions and

previous treatment were not included in the study since this was done as a 'snapshot' study over a period of 2–4 weeks [Figure 1]. All of the cases identified involved chronic wounds and due to the nature of the wounds several of the patients had comorbidities, such as diabetes, rheumatoid arthritis, peripheral arterial disease, malignancy and immune deficiency, contributing to the complexity of these cases. Selection criteria included:

- Wounds showing clinical signs of infection (local/NERDS or systemic/STONES (Sibbald et al, 2011))
- Delayed wound healing for more than 2 weeks
- Aetiology included chronic wounds, such as diabetic foot ulcers, leg ulcers, pressure ulcers
- Malignant wounds and surgical and dehisced wounds that had delayed healing for more than 2 weeks.

### Treatment protocol

The following treatment protocol was followed for all wounds in the study:

- Wounds were soaked for 15–20 minutes with Prontosan gel or Prontosan irrigation solution moistened gauze. Both the gel and the soaked gauze was kept in place by using cling film, gel was wiped away with saline gauze and soaked Prontosan gauze was used to wipe the wound
- After wound cleansing, Calgitrol Thin or Calgitrol paste was applied depending on wound size and depth\*
- The secondary dressing applied varied from non-adhesive foam to high-absorbent composite dressing depending on exudate levels

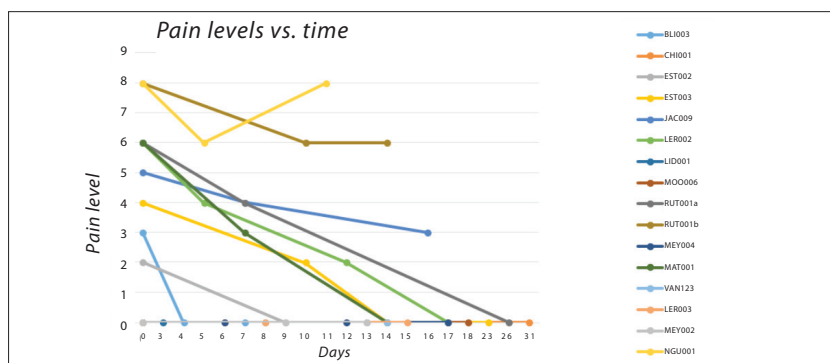


Figure 2. Pain level versus time.

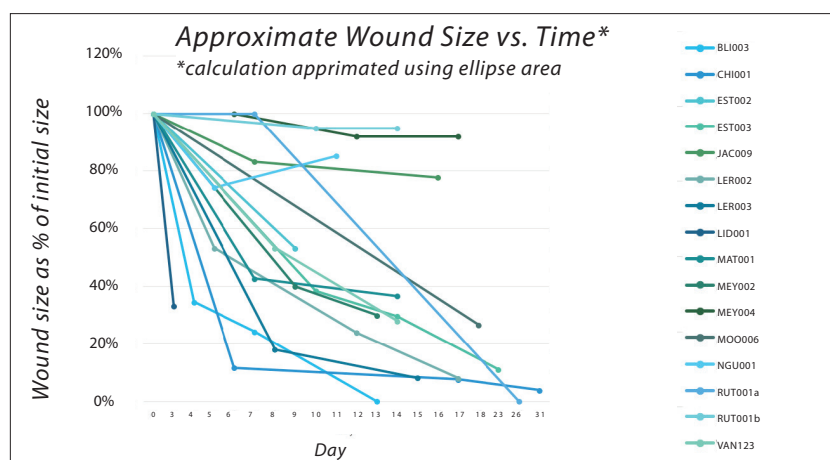


Figure 2. Approximate wound size versus time.

Figure 4. Yellow versus time.

- Gold standard treatment was still applied, i.e. offloading for diabetic ulcers and pressure ulcers, and compression bandaging for venous ulcers (Sibbald et al, 2011; 2015)
- Dressings were changed 2–3 times per week until signs of infection had cleared; no surgical debridement was carried out during the evaluation. Cleansing protocol with Prontosan was followed at each visit and the appropriate Calgitrol product was applied

■ Wounds were evaluated with regards to improvement in clinical signs of infection, quality of wound bed tissue, wound progress by measuring size and taking photographs. Pain was documented on a numerical rating scale.

\*Calgitrol Thin was used in wounds with high amounts of exudate and Calgitrol paste was used in wounds with low to moderate exudate.

## Results

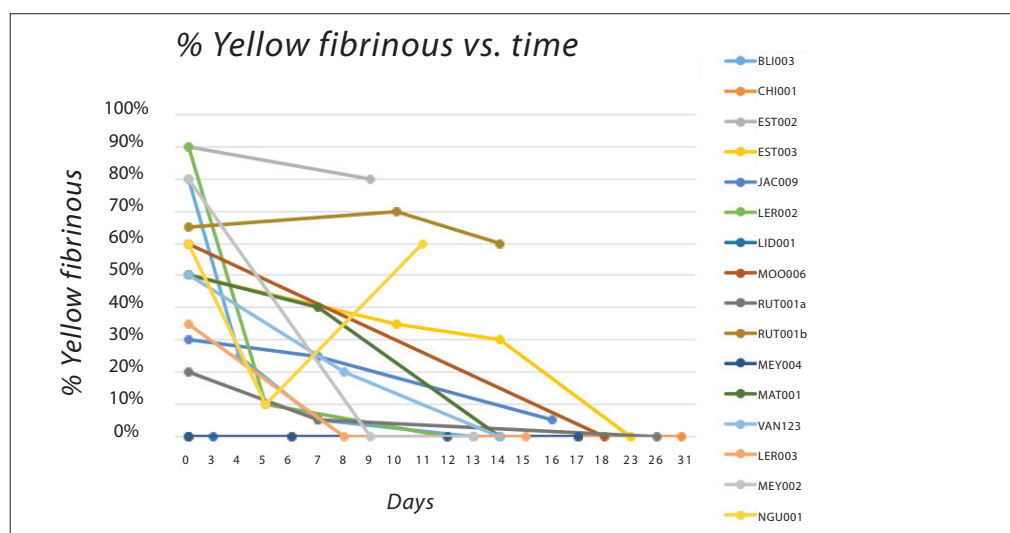
### Infection resolve time

All wounds showed a significant reduction in terms of clinical signs of infection within the first week of treatment. Some 50% of all wound infections were completely resolved by week 2. Eighty-one per cent of all wounds had no clinical signs of infection in less than 3 weeks. None of the patients were given any oral or intravenous antibiotics while on the study; all patients were only treated by using local antimicrobials. There was also a decrease in odour in all wounds.

### Decrease in yellow fibrin/slough

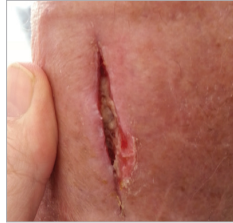One-hundred per cent of the wounds showed a significant decrease in fibrin/slough during the first week of the treatment period. The fast reduction in slough may be contributed to the use of the Prontosan as a wound cleanser, thus directly acting on the wound bed as a desloughing agent. At the same time, by removing the fibrin or slough, the silver antimicrobial could interact directly with the wound bed without the fibrinous barrier.

The wounds that did not progress after the first week were those with underlying pathology, such as the arterial insufficiency due to occlusion of the popliteal artery (NGU001\*\*) and the patient with malignancy (RUT001\*\*).

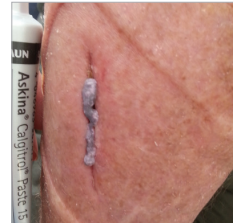

### Case study 1: Open surgical wound.

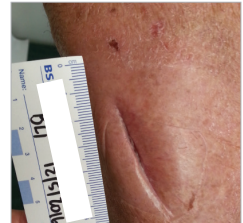Baseline – day 0



Calgitrol paste application



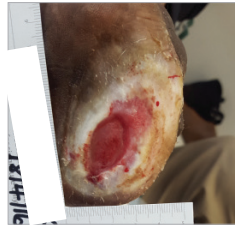
Wound closure – day 13



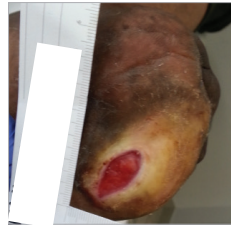A 72-year-old male patient developed severe cellulitis after puncture wound with rusty wire. He was admitted to hospital March 6, 2016 for intravenous antibiotics. The abscess was drained and negative-pressure wound therapy applied until April 26, 2016. The first consultation revealed an open ulcer with sloughy wound bed.

### Case study 2: Diabetic foot ulcer.

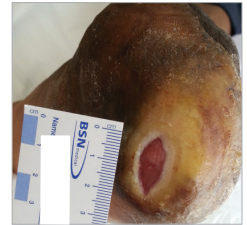
Baseline – day 0



Week 2



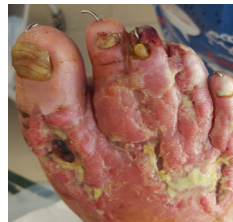Week 4



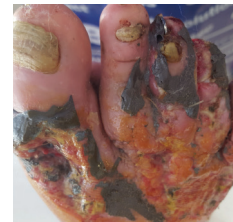A 65-year-old male patient with insulin-dependent diabetes and a history of previous amputations presented. The patient did not wear orthotics and missed two clinic appointments, resulting in skin breakdown.

### Case study 3: Dehisced surgical wounds.

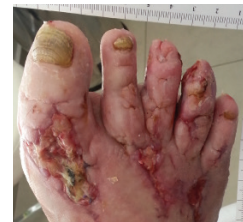Baseline – day 0



Calgitrol paste application



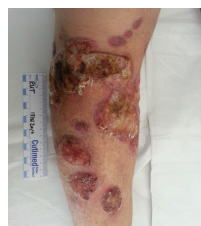Week 3



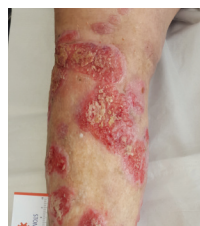A 76-year-old male patient with a history of rheumatoid arthritis, severe foot deformity. Patient had reconstructive surgery done 2 weeks prior to the first consultation. First visit bandages were maggot infested and clinical signs of infection were present. In this case, a combination of Calgitrol paste and Calgitrol thin was used according to the amount of exudate.

### Case study 4: Beta cell lymphoma with venous ulceration.

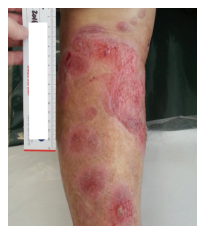Baseline – day 0



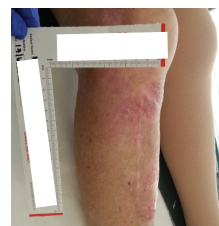Week 2



Week 3



Week 8



Patient with a history of cutaneous diffuse large B-cell lymphoma diagnosed in 2008. The patient had several treatments of chemotherapy and radiotherapy to treat the cancer. They had lower leg ulceration for several months.

## Pain level vs time

All wounds showed a significant decrease in pain levels within the first week. Some 6% of the patients did not follow the norm in showing signs of pain decrease; this was due to critical limb ischaemia requiring vascular surgery (NGU001) [Figure 2].

## Results summary

- At baseline and follow up 1-week and 2-week measurement, 100% of the wounds decreased in size
- 43% of wounds healed within the 2-week period [Figure 3].
- All wounds showed a reduction in slough within the 2-week challenge period [Figure 4]
- Fifty per cent of all wound infection was completely resolved by week 2. Eighty-one per cent of all wounds had no clinical signs of infection in less than 3 weeks
- All wounds showed a significant decrease in pain levels within the first week. Six per cent of the patients did not follow the norm in showing signs of pain decrease; this was due to critical limb ischaemia requiring vascular surgery (NGU001).

## Conclusion

Patient demographics, as well as contributing factors, did have an impact in this case series. Challenges faced included difficulty for patients to adhere to clinic scheduled visits, arterial insufficiency requiring vascular intervention, malignancy and complicated Charcot foot. Even with these challenges, it is remarkable to see that 81% of all cases showed significant improvement in all measured attributes and all anticipated outcomes were achieved.

The Prontosan biofilm remover/cleanser in gel form together with the use of an ionic releasing silver alginate (Askina Calgitrol Paste or Askina Calgitrol Thin) were easy to apply and remove. Wound exudate volume decreased and periwound maceration decreased in all wounds. The shorter healing time and resolution of infection within the 2–4 weeks period has resulted in a more than 60% cost reduction compared to the cost of treatment prior to application of the protocol. The results show that using a biofilm remover/cleanser together with an antimicrobial

is more effective in treating the infection (Wounds International, 2010; 2016; Attinger and Wolcott, 2012; Keast et al, 2014) than just using an antimicrobial alone.

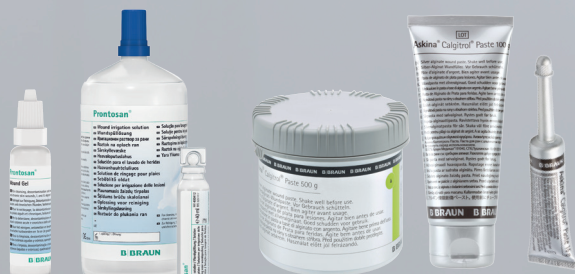The study also illustrated that systemic antibiotics can be avoided by using a combination approach of an anti-biofilm cleanser and silver antimicrobial. The results from this case series underscore the consensus guidelines with regards to the 2-week silver challenge (Wounds International, 2012; 2016) and also illustrates the value of removing biofilm prior to the application of an antimicrobial dressing. WINT

## References

- Attinger C, Wolcott R (2012) Clinically addressing biofilm in chronic wounds. *Adv Wound Care* 1(3): 127–32
- Keast D, Swanson T, Carville K et al (2014) Top ten tips: understanding and managing wound biofilm. *Wounds International* 5(2): 20–4
- Landis S, Ryan S, Woo K, Sibbald RG (2007) Infections in chronic wounds. (In) Krasner D, Rodeheaver GT, Sibbald RG. *Chronic Wound Care: A Clinical Source Book for Healthcare Professionals* (4th edn.) HMP Communications, Malevern pp 299–321
- Sibbald RG, Goodman L, Woo KY et al (2011) Special considerations in wound bed preparation 2011: an update. *Adv Skin Wound Care* 24(9): 415–36
- Wounds International (2012) *International Consensus: Appropriate use of Silver Dressings in Wounds*. Available at: [http://www.woundsinternational.com/media/issues/567/files/content\\_10381.pdf](http://www.woundsinternational.com/media/issues/567/files/content_10381.pdf) (accessed 09.02.2018)
- Wounds International (2010) *Biofilms Made Easy*. Wounds International 1(3): 1–6. Available at: [http://www.woundsinternational.com/media/issues/288/files/content\\_8851.pdf](http://www.woundsinternational.com/media/issues/288/files/content_8851.pdf) (accessed 09.02.2018)
- Wounds UK (2013) *Best Practice statement: The use of Topical Antimicrobial Agents in Wound Management*. Wounds UK, London. Available at: <http://bit.ly/2H1OqPv> (accessed 09.02.2018)
- World Union of Wound Healing Societies (2008) *Wound Infection in Clinical Practice. An International Consensus*. Wounds International, London. Available at: [http://www.woundsinternational.com/media/issues/71/files/content\\_31.pdf](http://www.woundsinternational.com/media/issues/71/files/content_31.pdf) (accessed 09.02.2018)
- World Union of Wound Healing Societies (2016) *Position document Management of Biofilm*. Wounds International, London. Available at: [http://www.wuwhs2016.com/files/WUWHS\\_Biofilms\\_web.pdf](http://www.wuwhs2016.com/files/WUWHS_Biofilms_web.pdf) (accessed 09.02.2018)
- Sibbald RG, Elliott JA, Ayello EA, Somayaji R (2015) Optimizing the moisture management tightrope with wound bed preparation 2015. *Adv Skin Wound Care* 28(10): 466–76; quiz 477–8

# NOTHING'S GONNA STOP YOU NOW.

Fight wound infection effectively  
with Prontosan® and Askina® Calgitrol® Paste.



Prontosan®

Askina® Calgitrol® Paste

Take wound bed preparation seriously with Prontosan® and combine it with Askina® Calgitrol® Paste for a broad antimicrobial effectiveness.