



POSITION DOCUMENT



Wound bed preparation in practice

Wound bed preparation: science applied to practice

Wound bed preparation for diabetic foot ulcers

Wound bed preparation for venous leg ulcers

MANAGING EDITOR

Suzie Calne

SENIOR EDITORIAL ADVISOR

Christine Moffatt

Professor and Co-director, Centre for Research and Implementation of Clinical Practice, Wolfson Institute of Health Sciences, Thames Valley University, London, UK

CONSULTANT EDITOR

Madeleine Flanagan

Principal Lecturer, Department of Continuing Professional Development, Faculty of Health and Human Sciences, University of Hertfordshire, UK

EDITORIAL ADVISORS

Vincent Falanga

Professor of Dermatology and Biochemistry, Boston University; Chairman and Training Program Director, Roger Williams Medical Centre, Providence, Rhode Island, USA

Marco Romanelli

Consultant Dermatologist, Department of Dermatology, University of Pisa, Italy

J Javier Soldevilla Ágreda

Professor of Geriatric Care, EUE University of La Rioja, Logroño, Spain

Luc Téot

Assistant Professor of Surgery, University Hospital, Montpellier, France

Peter Vowden

Consultant in General Surgery, Department of Vascular Surgery, Bradford Royal Infirmary, UK

Ulrich E Ziegler

Senior Consultant and Plastic Surgeon, Department of Plastic and Hand Surgery, University of Wuerzburg, Germany

EDITORIAL PROJECT MANAGER

Kathy Day

SUB-EDITOR

Ann Shuttleworth

DESIGNER

Jane Walker

PRODUCTION

Kathy Day

PRINTED BY

Viking Print Services, UK

PUBLISHING DIRECTOR

Jane Jones

FOREIGN EDITION TRANSLATIONS

Alden Translations, Oxford, UK

PUBLISHED BY MEDICAL EDUCATION PARTNERSHIP LTD

53 Hargrave Road, London N19 5SH, UK
Tel: +44(0)20 7561 5400 E-mail: info@mepltd.co.uk

EUROPEAN WOUND MANAGEMENT ASSOCIATION

Secretariat: PO BOX 864, London SE1 8TT, UK
Tel: +44 (0)20 7848 3496 www.ewma.org

Supported by an educational grant from Smith & Nephew.



The views expressed in this publication are those of the authors and do not necessarily reflect those of Smith & Nephew.



© MEDICAL EDUCATION PARTNERSHIP LTD, 2004

All rights reserved. No reproduction, copy or transmission of this publication may be made without written permission. No paragraph of this publication may be reproduced, copied or transmitted save with written permission or in accordance with the provisions of the Copyright, Designs & Patents Act 1988 or under the terms of any license permitting limited copying issued by the Copyright Licensing Agency, 90 Tottenham Court Road, London W1P 0LP.

To reference this document cite the following:

European Wound Management Association (EWMA). Position Document: *Wound Bed Preparation in Practice*. London: MEP Ltd, 2004.

Wound bed preparation in practice

CJ Moffatt

The last two decades have focused on improving the healing rates of patients with a wide range of chronic wounds. It is now realistic to expect that, with evidence-based care, many wounds will heal uneventfully within a reasonable timeframe. Despite overall improvements, however, there remains a small but significant proportion of chronic wounds that fail to heal even with the highest standard of care. The management of these wounds has therefore come under scrutiny and attention has turned to the factors that influence their healing and to the preparation of the wound bed.

Wound bed preparation is not a static concept, but a dynamic and rapidly evolving one. Falanga, in reviewing the evolution of the concept in the first article in this document, describes the development of TIME. This is a model comprising the four components that underpin wound bed preparation (Tissue management, Inflammation and infection control, Moisture balance, Epithelial (edge) advancement). Falanga suggests that the TIME framework offers clinicians a comprehensive approach where basic science can be applied to develop strategies that maximise the potential for wound healing.

This EWMA position document seeks to advance understanding of the concepts of wound bed preparation by examining how the components of TIME are translated into the practical management of different wound types, each presenting with unique clinical challenges.

The article by Edmonds, Foster and Vowden shows that for the diabetic foot ulcer, the emphasis within the TIME framework is on tissue management in the form of radical and repeated debridement of the wound, and that inflammation and infection control play significant and complex roles in these wounds. In contrast, the article by Moffatt, Morison and Pina shows that for venous leg ulcers, the emphasis is on restoring and maintaining moisture balance, while tissue management and infection control are less prominent issues. These articles illustrate that the TIME framework is not linear: different wounds require attention to the different elements. The framework also recognises that one intervention can impact on more than one element of TIME. Debridement, for example, can be used as an intervention for tissue management, but can also impact on inflammation and infection control.

The wound bed preparation model is dependent on effective and accurate patient and wound assessment. Using this approach clinicians can develop skills in the early identification of patients with non-healing wounds and the strategies that may influence progress, rather than leaving patients unhealed for prolonged periods without intervention. This position document reinforces the importance of integrating TIME into an overall programme of care that addresses all other aspects of the patient's treatment. Venous ulcers, for example, will not heal without compression; nor will diabetic foot ulcers without pressure offloading and diabetic control.

This shift in our thinking about wounds should promote an increasing interest in the development of targeted interventions that can be used within the wound bed preparation model. These range from basic interventions such as elevating the limb to improve moisture balance in venous leg ulcers, or covering the wound to reduce the risk of infection in diabetic foot ulcers, to the more complex use of advanced therapies to stimulate epithelial (edge) advancement.

As our understanding increases it will be possible to correctly target more advanced and expensive technologies at those patients who will benefit from their use. Indeed, TIME provides a framework for the cost-effective introduction of these treatments.

Wound bed preparation offers great potential to improve the lives of patients with intractable wounds and to empower health professionals at all levels to effectively manage complex non-healing. In addition, using the TIME framework as part of an ongoing, holistic wound management strategy has the potential to reduce the financial burden placed on health services by the treatment of this small but costly group of patients.

Wound bed preparation: science applied to practice

V Falanga

INTRODUCTION

Recent advances in molecular science have improved our understanding of wound healing and brought about new technical opportunities in wound management. Advanced therapies such as the use of growth factors¹, the ability to grow cells *in vitro*², and the development of bioengineered tissue³ have enhanced these opportunities. Wound bed preparation offers clinicians a comprehensive approach to removing barriers to healing and stimulating the healing process in order to maximise the benefits of such advances. This paper describes how the components of wound bed preparation are applied to practice.

COMPONENTS OF WOUND BED PREPARATION

Wound bed preparation offers opportunities for the management of chronic wounds⁴. These range from addressing basic aspects such as management of infection, necrotic tissue and exudate to more complex management, for example, of phenotypic changes in wound cells. This is where cells within and around the wound become senescent (age) and unresponsive to certain treatments and require re-engineering of the chronic wound using such treatments as biological agents (eg cell therapy) to reconstitute the dermal structure.

There are four components to wound bed preparation, which address the different pathophysiological abnormalities underlying chronic wounds. These components form a framework that offers clinicians a comprehensive approach to chronic wound management that is distinct from those used for acute injury. Based on the work of the International Wound Bed Preparation Advisory Board⁵, an acronym has been formed using the names of the components in the English language; the framework has been named TIME⁶. In order to maximise their value across different disciplines and languages, the EWMA wound bed preparation editorial advisory board has further developed the terms (Table 1).

The TIME framework aims to optimise the wound bed by reducing oedema and exudate, reducing the bacterial burden and, importantly, correcting the abnormalities contributing to impaired healing. This should facilitate the normal endogenous process of wound healing, providing the underlying intrinsic and extrinsic factors affecting the wound's failure to heal have also been addressed.

The TIME framework is not linear; during the process of healing different elements of the framework will require attention. Figure 1 shows TIME applied to practice using the example of an open, chronic, slow-healing wound. In addition, clinicians can use the TIME framework to evaluate the role of therapeutic interventions. A single intervention can impact on more than one element of the framework, for example debridement will not only remove necrotic tissue but will also reduce bacterial load.

Tissue management

The presence of necrotic or compromised tissue is common in chronic non-healing wounds, and its removal has many beneficial effects. It takes away non-vascularised tissue, bacteria and cells that impede the healing process (cellular burden), thus providing an environment that stimulates the build-up of healthy tissue. In the light of recent studies about senescence of wound cells and their unresponsiveness to certain signals⁵, the fact that debridement removes the cellular burden and allows a stimulatory environment to be established is particularly important. Unlike acute wounds, which usually only require debridement once if at all, chronic wounds may require repeated debridement.

Table 1 | Evolution of the TIME framework

TIME acronym	Terms proposed by EWMA advisory board
T = Tissue, non-viable or deficient	Tissue management
I = Infection or inflammation	Inflammation and infection control
M = Moisture imbalance	Moisture balance
E = Edge of wound, non-advancing or undermined	Epithelial (edge) advancement

Professor of Dermatology and Biochemistry, Boston University, Chairman and Training Program Director, Roger Williams Medical Centre, Providence, Rhode Island, USA.

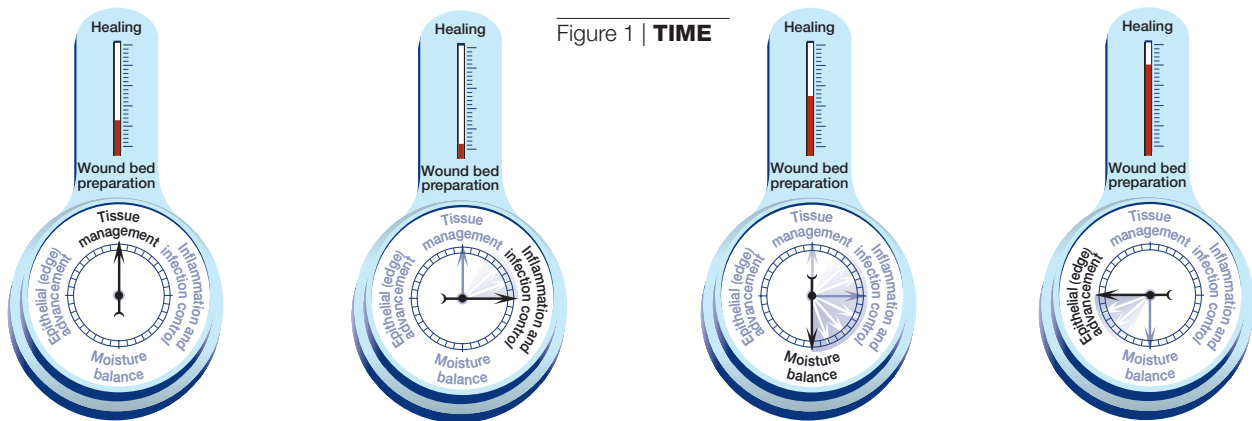


Figure 1 | **TIME**

1a | Represents an open chronic, slow-healing wound, covered with necrotic tissue requiring debridement

1b | The wound has become critically colonised or infected, slowing healing. Antimicrobial agents and further debridement are required

1c | As a result of infection and/or inflammation the wound is producing more exudate and attention now focuses on moisture balance

1d | As the critical colonisation or infection resolves and moisture balance is achieved, attention should move to epithelial (edge) advancement

Inflammation and infection control

Chronic wounds are often heavily colonised with bacterial or fungal organisms. This is due in part to the fact that these wounds remain open for prolonged periods, but is also related to other factors such as poor blood flow, hypoxia and the underlying disease process⁷. There is little question that clinical infection resulting in failure to heal must be treated aggressively and promptly. Evidence shows that a bacterial burden of 10^6 organisms or more per gram of tissue seriously impairs healing⁸, although the reason for this is poorly understood.

Recently, there has been increasing interest in the possible presence of biofilms in chronic wounds and their role in impaired healing or recurrence. Biofilms are bacterial colonies surrounded by a protective coat of polysaccharides; such colonies become more easily resistant to the action of antimicrobials⁹. However, intensive investigation is needed to determine the role of biofilms in delayed healing of chronic wounds.

Moisture balance

Experimental evidence indicating that keeping wounds moist accelerates re-epithelisation is one of the major breakthroughs of the last 50 years^{10,11} and led to the development of a vast array of moisture-retentive dressings that promote ‘moist wound healing’¹². Most evidence for moist wound healing was developed in experiments on acute wounds, but the findings were quickly extrapolated to chronic wounds. Contrary to what had been conventional wisdom, keeping the wound moist does not increase infection rates^{13,14}.

It is not clear whether moisture-retentive dressings work mainly by keeping the wound fluid in contact with the wound. One reason for this uncertainty is that this fluid appears to have different properties in acute and chronic wounds. For example, fluid collected from acute wounds will stimulate the *in vitro* proliferation of fibroblasts, keratinocytes, and endothelial cells^{15,16}. Conversely, fluid from chronic wounds will block cellular proliferation and angiogenesis¹⁷ and contains excessive amounts of matrix metalloproteinases (MMPs)^{18,19} capable of breaking down critical extracellular matrix proteins, including fibronectin and vitronectin¹⁹. There is no doubt that some MMPs play a key role in wound healing – for example, interstitial collagenase (MMP-1) is important for keratinocyte migration²⁰. However, it has been suggested that excessive activity (or maldistribution) of other enzymes (MMP-2, MMP-9) impair healing²¹.

Excessive wound fluid does not have to contain abnormal or inappropriately activated MMPs to be detrimental. Normal components of plasma, if continuously present, can lead

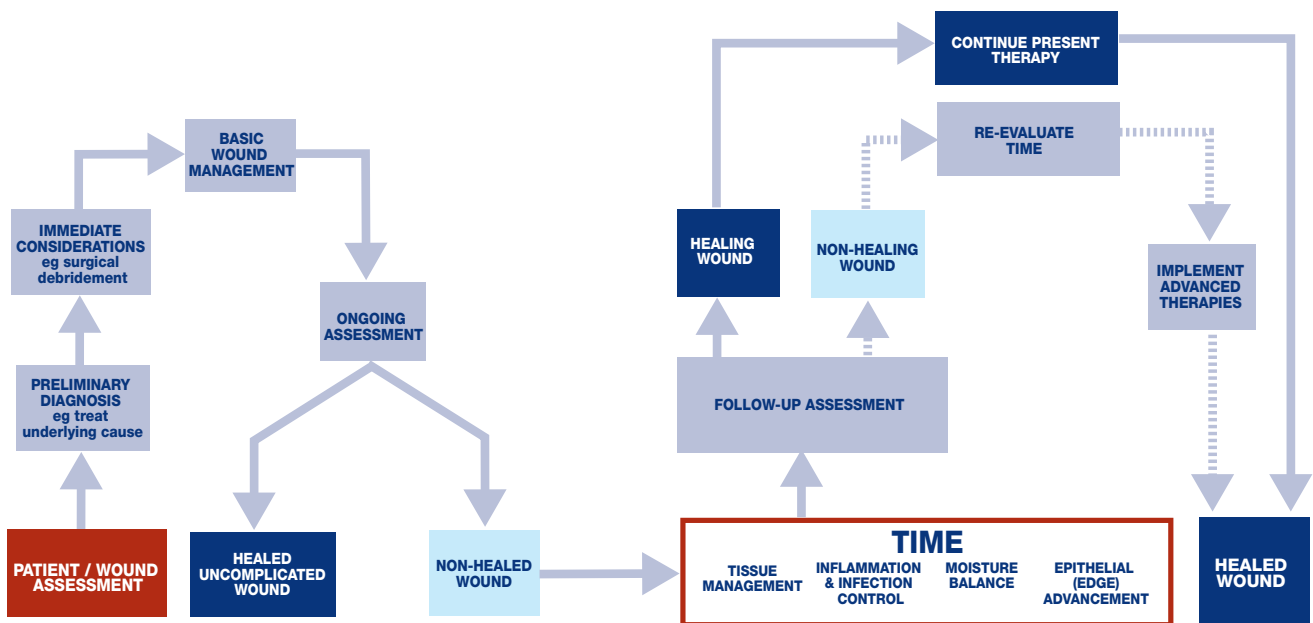


Figure 2 | Pathway showing how wound bed preparation is applied to practice

Epithelial (edge) advancement

KEY POINTS

1. Wound bed preparation is not a static concept but a dynamic and rapidly evolving one.
2. There are four components to wound bed preparation, which address the different pathophysiological abnormalities underlying chronic wounds.
3. The TIME framework can be used to apply wound bed preparation to practice.

to what has been hypothesised as ‘growth factor trapping’. This theory was developed in the context of venous ulcers, but may apply to a variety of chronic wounds. The hypothesis is that certain macromolecules and even growth factors are bound or ‘trapped’ in the tissues, which could result in unavailability or maldistribution of critical mediators, including cytokines²². Trapping of growth factors and cytokines, as well as matrix material, however limited, has the potential to cause a cascade of pathogenic abnormalities, and dressings may play an important role in modulating these factors.

Effective healing requires the re-establishment of an intact epithelium and restoration of skin function. However, the process of epithelialisation may be impaired either indirectly, such as when faults in the wound matrix or ischaemia inhibit keratinocyte migration, or directly due to regulatory defects, impaired cellular mobility or adhesion within the keratinocytes.

Impaired epithelialisation at cellular level

The healing process involves well-defined phases. However, chronic wounds do not seem to have defined timeframes for healing and fail to progress sequentially through the phases. For example, it has been stated that diabetic ulcers are ‘stuck’ in the proliferative phase. Indeed, there is evidence of impaired metabolism of certain matrix proteins including fibronectin, which affects tissue accumulation and remodelling in diabetic foot ulcers²³.

There is increasing evidence that the resident cells of chronic wounds have undergone phenotypic changes that impair their capacity to proliferate and move²⁴. The extent to which this is due to senescence is not known, but the response of diabetic ulcer fibroblasts to growth factors seems to be impaired, requiring a sequence of growth factors²⁴. Similar observations have been made in other chronic wounds. For example, fibroblasts from venous and pressure ulcers show diminished ability to proliferate and their decreased proliferative capacity correlates with a failure to heal²⁵⁻²⁷ and reduced response to platelet-derived growth factor (PDGF)²⁸. It is not known whether this phenotypic abnormality of wound cells is only observed *in vitro* or whether it plays a role in impaired healing.

Impaired blood flow and hypoxia

There is a substantial body of data indicating that low levels of oxygen tension as measured at the skin surface correlate with inability to heal²⁹. It should be noted that ischaemia is not the same as hypoxia. Interestingly, low levels of oxygen tension can stimulate fibroblast proliferation and clonal growth, and can actually enhance the transcription and synthesis of a number of growth factors^{30,31}. It is possible that low oxygen tension serves as a potent initial stimulus after injury, while prolonged hypoxia, as seen in chronic wounds, can lead to a number of abnormalities including scarring and fibrosis³², as well as delayed edge migration and poor restoration of epithelial function.

CONCLUSION

The TIME framework offers a model that recognises the relationship of pathogenic abnormalities which impair healing to the application of existing therapies and procedures. Wound bed preparation should not be seen in isolation from holistic wound assessment, which encompasses the patient's psychosocial needs as well as underlying and associated aetiologies (Figure 2). Used in this way, if all elements of the framework are successfully addressed, many wounds should move towards healing.

Greater therapeutic boldness is required and one of the challenges for clinicians is to recognise when therapeutic interventions should be introduced to accelerate healing.

Considerable progress has been made and a number of therapeutic approaches are now available. It is hoped that continued advances, combined with effective wound management, will accelerate the healing of chronic wounds to an extent that is not currently possible.

References

- Harding KG, Morris HL, Patel GK. Science, medicine and the future: healing chronic wounds. *BMJ* 2002; 324(7330): 160-163.
- Navsaria HA, Myers SR, Leigh IM, McKay IA. Culturing skin *in vitro* for wound therapy. *Trends Biotechnol* 1995; 13(3): 91-100.
- Boyce ST. Design principles for composition and performance of cultured skin substitutes. *Burns* 2001; 27(5): 523-533.
- Falanga V. Classifications for wound bed preparation and stimulation of chronic wounds. *Wound Repair Regen* 2000; 8: 347-352.
- Schultz GS, Sibbald RG, Falanga V, et al. Wound bed preparation: a systematic approach to wound management. *Wound Repair Regen* 2003; 11(2): Suppl S1-S28.
- Flanagan M. *The Philosophy of Wound Bed Preparation in Clinical Practice*. Smith and Nephew Medical, 2003.
- Hunt TK, Hopf HW. Wound healing and wound infection: what surgeons and anesthesiologists can do. *Surg Clin North Am* 1997; 77(3): 587-606.
- Robson MC. Wound infection: a failure of wound healing caused by an imbalance of bacteria. *Surg Clin North Am* 1997; 77(3): 637-650.
- Zegans ME, Becker HI, Budzik J, O'Toole G. The role of bacterial biofilms in ocular infections. *DNA Cell Biol* 2002; 21(5-6): 415-420.
- Winter G. Formation of scab and the rate of epithelialisation of superficial wounds in the skin of the young domestic pig. *Nature* 1962; 193: 293-294.
- Hinman CAMH. Effect of air exposure and occlusion on experimental human skin wounds. *Nature* 1963; 200: 377-378.
- Ovington LG. Wound care products: how to choose. *Adv Skin Wound Care* 2001; 14(5): 259-264.
- Hutchinson JJ. Infection under occlusion. *Ostomy Wound Manage* 1994; 40(3): 28-30, 32-33.
- Hutchinson JJ, Lawrence JC. Wound infection under occlusive dressings. *J Hosp Infect* 1991; 17(2): 83-94.
- Katz MH, Alvarez AF, Kirsner RS, et al. Human wound fluid from acute wounds stimulates fibroblast and endothelial cell growth. *J Am Acad Dermatol* 1991; 25(6 Pt 1): 1054-1058.
- Schaffer MR, Tantry U, Ahrendt GM, et al. Stimulation of fibroblast proliferation and matrix contraction by wound fluid. *Int J Biochem Cell Biol* 1997; 29(1): 231-239.
- Bucalo B, Eaglstein WH, Falanga V. Inhibition of cell proliferation by chronic wound fluid. *Wound Repair Regen* 1993; 1: 181-186.
- Wysocki AB, Staiano-Coico L, Grinnell F. Wound fluid from chronic leg ulcers contains elevated levels of metalloproteinases MMP-2 and MMP-9. *J Invest Dermatol* 1993; 101(1): 64-68.
- Trengove NJ, Stacey MC, MacAuley S, et al. Analysis of the acute and chronic wound environments: the role of proteases and their inhibitors. *Wound Repair Regen* 1999; 7(6): 442-452.
- Pilcher BK, Dumin JA, Sudbeck BD, et al. The activity of collagenase-1 is required for keratinocyte migration on a type I collagen matrix. *J Cell Biol* 1997; 137(6): 1445-1457.
- Yager DR, Zhang LY, Liang HX, et al. Wound fluids from human pressure ulcers contain elevated matrix metalloproteinase levels and activity compared to surgical wound fluids. *J Invest Dermatol* 1996; 107(5): 743-748.
- Falanga V, Eaglstein WH. The 'trap' hypothesis of venous ulceration. *Lancet* 1993; 341(8851): 1006-1008.
- Loots MA, Lamme EN, Zeegelaar J, et al. Differences in cellular infiltrate and extracellular matrix of chronic diabetic and venous ulcers versus acute wounds. *J Invest Dermatol* 1998; 111(5): 850-857.
- Loots MA, Lamme EN, Mekkes JR, et al. Cultured fibroblasts from chronic diabetic wounds on the lower extremity (non-insulin-dependent diabetes mellitus) show disturbed proliferation. *Arch Dermatol Res* 1999; 291(2-3): 93-99.
- Hehenberger K, Heilborn JD, Brismar K, Hansson A. Inhibited proliferation of fibroblasts derived from chronic diabetic wounds and normal dermal fibroblasts treated with high glucose is associated with increased formation of l-lactate. *Wound Repair Regen* 1998; 6(2): 135-141.
- Stanley A, Osler T. Senescence and the healing rates of venous ulcers. *J Vasc Med Biol* 2001; 13(6): 1206-1211.
- Kim B-C, Kim HT, Park SH, et al. Fibroblasts from chronic wounds show altered TGF- β Type II receptor expression. *J Cell Physiol* 2003; 195: 331-336.
- Agren MS, Steenfors HH, Dabelsteen S, et al. Proliferation and mitogenic response to PDGF-BB of fibroblasts isolated from chronic venous leg ulcers is ulcer-age dependent. *J Invest Dermatol* 1999; 112(4): 463-469.
- Fife CE, Buyukkacir C, Otto GH, et al. The predictive value of transcutaneous oxygen tension measurement in diabetic lower extremity ulcers treated with hyperbaric oxygen therapy: a retrospective analysis of 1,144 patients. *Wound Repair Regen* 2002; 10(4): 198-207.
- Kourembanas S, Hannan RL, Faller DV. Oxygen tension regulates the expression of the platelet-derived growth factor-B chain gene in human endothelial cells. *J Clin Invest* 1990; 86(2): 670-674.
- Falanga V, Qian SW, Danielpour D, et al. Hypoxia upregulates the synthesis of TGF- β 1 by human dermal fibroblasts. *J Invest Dermatol* 1991; 97(4): 634-637.
- Falanga V, Zhou L, Yufit T. Low oxygen tension stimulates collagen synthesis and COL1A1 transcription through the action of TGF- β 1. *J Cell Physiol* 2002; 191(1): 42-50.

Wound bed preparation for diabetic foot ulcers

M Edmonds¹, AVM Foster², P Vowden³

INTRODUCTION

The processes involved in wound bed preparation have influenced diabetic foot ulcer management for some time. Diabetic foot ulcers occur when trauma leads to an acute wound, which progresses to a chronic wound due to extrinsic and intrinsic factors. This paper uses the concept of wound bed preparation and the TIME framework (Tissue management, Inflammation and infection control, Moisture balance and Epithelial (edge) advancement) to describe the management of these ulcers, with the aim of creating a well-vascularised wound bed surrounded by intact skin with an advancing epithelial edge that progresses to healing and produces a stable scar.

BEFORE TIME

Diabetic foot ulcers require an integrated, multidisciplinary management programme that treats the whole patient and combines effective wound care with pressure offloading and diabetic control. They present a unique challenge as the impact of diabetes extends beyond glycaemic control, affecting protein synthesis, white cell function, oxygen transportation and utilisation and growth factor availability¹. These complications are compounded by poor glycaemic control, and exacerbated by neuropathy, cheiroarthropathy (diabetic changes affecting the skin and joints) and peripheral vascular disease. Suppression of neutrophil function further aggravates the situation by increasing the risk of infection.

When managing ulceration in the diabetic foot the underlying pathophysiology must be established to identify whether there is evidence of peripheral neuropathy and/or peripheral vascular disease (ischaemia). The underlying physical cause of the wound must also be identified and, if possible, eliminated or corrected. In addition three basic elements must be addressed:

- Pressure control: offloading and weight redistribution and/or callus removal
- Restoration or maintenance of pulsatile blood flow
- Metabolic control.

Unless these elements are addressed, wound care is more likely to fail and the patient will be at increased risk of amputation or recurrent ulceration. Education should also be given to ensure the patient understands the aims of treatment.

TISSUE MANAGEMENT Sharp debridement

The diabetic foot does not tolerate sloughy, necrotic tissue, and debridement is therefore an important component of ulcer management. Debridement serves several functions: it removes necrotic tissue and callus, reduces pressure, allows full inspection of the extent of the wound, facilitates drainage and stimulates healing. Studies by Steed *et al*² confirmed that patients with diabetic neuropathic foot ulcers which underwent regular sharp debridement did better than those whose ulcers had less debridement.

With the exception of ulcers requiring extensive debridement by a surgeon while the patient is under general anaesthetic, the gold standard method is sharp debridement. This can remove the unhealthy components of a chronic foot wound, stimulating the wound bed by creating an acute injury in a chronic wound environment³. Regular sharp debridement may be necessary to prevent the wound from reverting to a purely chronic state.

It is important to recognise the characteristics of wound tissue in order to undertake debridement safely and effectively. Healthy tissue is pink or red, and either shiny and smooth or with 'rosettes' on the surface, while new epithelium can be seen growing from the wound edge and is pink or pearly white. Non-viable tissue may:

- Be yellow, grey, blue, brown or black
- Have a soft or slimy consistency
- Form a hard, 'leathery' eschar.

Debridement is indicated where there is accumulation of callus, slough, fibrous tissue or obviously non-viable tissue. However, it is important to achieve the right balance in the amount of tissue removed. Removing too much will prolong the healing process, while if too little is removed, the wound's chronic status will continue.

1. Consultant Physician, Diabetic Foot Clinic, King's College Hospital NHS Trust, London, UK.

2. Lead Clinical Specialist Podiatrist, Diabetic Foot Clinic, King's College Hospital NHS Trust, London, UK.

3. Consultant in General Surgery, Department of Vascular Surgery Bradford Royal Infirmary, Bradford, UK.

It is important to clearly distinguish between the diabetic neuropathic foot, in which the blood supply is good, and the diabetic neuroischaemic foot, in which it is poor. Aggressive sharp debridement (to healthy, bleeding tissue) can be performed on neuropathic ulcers to remove callus, slough, necrosis and non-viable tissue. However, while neuroischaemic ulcers benefit from the removal of non-viable tissue, they should be debrided with extreme caution to minimise damage to viable tissue. Sharp debridement can also help to prevent or manage infection, which can be improved if sinuses are opened, sloughy infected tissue removed and fluid-filled cavities drained.

In the neuropathic foot, wet necrosis caused by infection can be treated with intravenous antibiotics and surgical debridement. This approach may be used in the neuroischaemic foot, but if the ischaemia is severe, revascularisation should be performed. If vascular intervention is not possible, surgery should not be undertaken unless unavoidable. Instead, an attempt should be made to convert wet necrosis to dry necrosis using intravenous antibiotics and by appropriate wound care such as the use of iodine products⁴. Some cases do well with a dry managed eschar and may proceed to auto-amputation.

Larval therapy

Although sharp debridement is the gold standard treatment for diabetic foot lesions, on occasions if the foot is too painful for the patient to tolerate sharp debridement or the patient has expressed a preference, larvae of the greenbottle fly can achieve relatively rapid, atraumatic removal of necrotic material⁵. The larvae may be used to remove slimy slough in painful ulcers in the neuroischaemic foot. They are not recommended as the sole agent for debriding the neuropathic foot as they do not remove callus, which is essential for healing. They may, however, reduce the bacterial load.

INFLAMMATION AND INFECTION CONTROL

INDICATORS OF INFECTION IN DIABETIC FOOT ULCERS

- Ulcer base yellowish grey
- Blue discoloration of surrounding tissues
- Fluctuance (softness) or crepitus (crackling, grating) on palpation
- Purulent exudate
- Sloughing of ulcer and surrounding tissue
- Sinuses with undermined or exposed bone
- Abscess formation
- Odour
- Wound breakdown
- Delayed healing

Note: classic signs of infection (pain, erythema, heat and purulence) may be absent or reduced due to sensory neuropathy and/or ischaemia

Infection is a threat to the diabetic foot as high-risk patients are immunocompromised, while in those who have poor metabolic control white cell function is impaired. It is implicated in most cases that result in major amputation⁶. Staphylococci and streptococci are the most common pathogens, although gram-negative and anaerobic organisms occur in approximately 50% of patients, and infection is often polymicrobial⁷. Bacterial species that are not pathogenic may cause a true infection in a diabetic foot as part of mixed flora, and poor immune response seen on occasions in diabetic patients means that even bacteria regarded as skin commensals may cause severe tissue damage.

While increased bacterial burden slows healing, the host-bacteria relationship is complex as many wounds are colonised with a stable bacterial population. If the bacterial burden increases, it may result in increased exudate as clinical infection develops. The signs of inflammation and infection are absent or reduced in many diabetic patients, such as those who lack the protective pain sensation and/or have a poor blood supply to the feet, and may be masked in patients with a severe autonomic neuropathy.

Cellulitis and osteomyelitis

Cellulitis covers a spectrum of presentations, including local infection of the ulcer, spreading cellulitis, sloughing of soft tissue and vascular compromise of the skin. When vascular compromise occurs there is an inadequate supply of oxygen to the soft tissues, causing a blue discoloration.

When infection spreads there is widespread, intense erythema, swelling and lymphangitis. Regional lymphadenitis may occur with malaise, 'flu-like' symptoms and rigors. Pain and throbbing usually indicate pus within the tissues, but these symptoms are often absent in the neuropathic foot. Palpation may reveal fluctuance (a soft, saturated feeling) or crepitus (a crackly, grating feeling), which suggest abscess formation. Often there is generalised sloughing of the ulcer and surrounding subcutaneous tissues, which liquefy and disintegrate.

If a sterile probe inserted into the ulcer reaches bone, this suggests osteomyelitis. In the initial stages plain X-ray may be normal and localised loss of bone density and cortical outline may not be apparent until at least 14 days later.

Bacterial management

Bacterial management involves topical therapy, which consists of cleansing agents and antimicrobials, and systemic antibiotics. Saline is the cleansing agent of choice as it does not interfere with microbiological samples or damage granulating tissue⁸. Cetrimide-based cleansing agents are not recommended as their cytotoxic action may impede healing⁸. Three antimicrobials are commonly used:

- Iodine is effective against a wide spectrum of organisms and current consensus suggests that slow-release iodine formulations are useful for antisepsis without impairing healing and have been used successfully on diabetic foot ulcers⁴
- Silver compounds are applied as silver sulphadiazine or may be impregnated into dressings. *In vitro* silver is effective against *Staphylococcus aureus* including methicillin-resistant *Staphylococcus aureus* (MRSA) and pseudomonas species⁹
- Mupirocin is active against gram-positive infections including MRSA. Its use should be limited to 10 days, and it should not be used as a prophylactic⁸.

Systemic antibiotic treatment is always indicated in the presence of cellulitis, lymphangitis and osteomyelitis. Infection in the neuroischaemic foot is often more serious than in the neuropathic foot, which has a good blood supply. A positive swab in a neuroischaemic foot ulcer therefore has more serious implications and influences antibiotic policy.

General principles of bacterial management

At initial presentation of infection it is important to prescribe wide-spectrum antibiotics and take cultures
Deep swabs or tissue should be taken from the ulcer after initial debridement
Ulcer swabs should be taken at every follow-up visit if suspicion of infection remains
Diabetic patients respond poorly to sepsis, therefore even bacteria regarded as skin commensals can cause severe tissue damage
Gram-negative bacteria isolated from an ulcer swab should not automatically be considered insignificant
Blood cultures should be sent if fever and systemic toxicity are present
The wound should be inspected regularly for early signs of infection
Microbiologists have a crucial role; laboratory results should be used to guide antibiotic selection
Timely surgical intervention is important in the presence of severe infection or abscess formation

MOISTURE BALANCE

RATIONALE FOR COVERING ULCERS

- To protect the wound from noxious stimuli
- To prevent infestation with insects
- To keep the wound warm
- To protect the wound from mechanical trauma
- To reduce the risk of infection

Wound and peri-wound moisture balance is critical and must be linked to the overall treatment plan. The value of moist wound healing in the diabetic foot ulcer has not been proven and there is an increasing argument that hydration is, for example, inappropriate in neuroischaemic ulceration if a decision has been made to mummify the digit or ulcer⁸. Excessive hydration may also macerate the plantar skin and reduce its effectiveness as a bacterial barrier.

There is no robust evidence that any one dressing performs significantly better on the diabetic foot than others. However, it is useful if the dressing is easy to remove, absorbent and able to accommodate pressures of walking without disintegrating.

If possible, dressings should be removed by the healthcare professional every day for wound inspection, as the only signs of infection may be visual when patients lack the protective pain sensation. However, the ulcer should be covered with a sterile, non-adherent dressing at all times except when being inspected or debrided.

EPITHELIAL (EDGE) ADVANCEMENT

It is important that the edges of neuropathic ulcers are 'saucerised' and all callus, dried exudate and accumulated slough, necrosis or non-viable cellular debris are debrided, removing potential physical barriers to the growth of epithelium across the ulcer bed. In patients with necrotic ulcers or necrotic digits the area of necrosis adjoining healthy tissue frequently gives rise to problems: the demarcation line between gangrene and viable tissue (the edge) frequently becomes the site of infection⁸. This may be because debris accumulates at this site and covers healthy skin, which then becomes macerated and prone to infection. Similar problems can be observed when a healthy toe is touching a gangrenous toe and becomes macerated at the point of contact, then infected. It may be that healing is stimulated by debriding the edge of the wound, and by preventing contact between healthy tissues and gangrene using dry dressings between the toes.

'Die-back' is similar to the above, but is an abnormal response to over-aggressive sharp debridement. It involves necrosis of tissue at the wound edge and extends through previously healthy tissue. Clinical experience suggests this is a particular problem in patients with severe nephropathy or end-stage renal failure.

In addition to edge-specific problems, epithelial (edge) advancement may be affected by extrinsic and intrinsic factors. Extrinsic factors include repeated trauma (not sensed due to neuropathy), ischaemia and poor metabolic control and intrinsic factors include deficiency of growth factors, abnormal extracellular matrix components with excess protease and reduced fibroblast activity.

Treatment of extrinsic factors

In the neuropathic foot, the aim is to redistribute plantar pressures evenly by applying some form of cast, adapted footwear or padding¹⁰. In the neuroischaemic foot the aim is to protect the vulnerable margins of the foot, where ulcers usually develop, through revascularisation and pressure redistribution. Crutches, wheelchairs and Zimmer frames may be useful to aid offloading for both neuropathic and neuroischaemic patients.

Ischaemia can be treated by angioplasty or arterial bypass¹¹. If lesions are too widespread for angioplasty, arterial bypass may be considered if the ulcer does not respond to conservative treatment¹².

While the influence of blood glucose control on wound healing is debatable¹³, it is important to control blood glucose, blood pressure and lipids and to encourage the patient to stop smoking. In patients with type 2 diabetes, oral hypoglycaemic therapy should be optimised, and if this is unsuccessful insulin should be initiated. Those with neuroischaemic ulcers should be given statin and anti-platelet therapy, while those aged over 55 years who have peripheral vascular disease should also benefit from an ACE inhibitor to prevent further vascular episodes¹⁴.

When managing hypertension in the presence of leg ischaemia there is a fine balance between maintaining a pressure that improves perfusion of the limb and reducing it enough to limit the risk of cardiovascular complications. In patients with evidence of cardiac failure aggressive treatment will improve tissue perfusion and reduce swelling of the feet. If renal impairment is present, treatment is essential to avoid lower limb swelling.

Treatment of intrinsic factors

Growth factor abnormalities

Skin biopsies from the edge of foot ulcers in non-diabetic and diabetic subjects have shown increased expression of transforming growth factor (TGF) beta 3 in the epithelium. However, expression of TGF-beta 1 was not increased, and this could explain impaired healing¹⁵. Lack of expression of insulin-like growth factor (IGF) 1 in diabetic skin and foot ulcers and in dermal fibroblasts may also contribute to delayed wound healing. However, IGF-2 was highly expressed in normal and diabetic skin as well as in diabetic foot ulcers, particularly at the ulcer edge¹⁶.

Hyperglycaemia and impaired insulin signalling may result in poor wound healing by reducing glucose utilisation of skin keratinocytes as well as skin proliferation and differentiation¹⁷. Glycation of basic fibroblast growth factor (FGF) 2 significantly reduces its activity and thus its ability to bind to tyrosine kinase receptor and activate signal transduction pathways¹⁸.

Free radicals may be important in the pathogenesis of diabetes-related healing deficit. A protective membrane antioxidant agent has been shown to significantly improve impaired wound healing in diabetic mice through stimulation of angiogenesis¹⁹.

Extracellular matrix and protease activity

In non-diabetic patients dermal wounds heal by contraction and granulation tissue formation, rather than re-epithelialisation. Contraction provides 80-90% of wound closure and speeds healing by reducing the amount of scar tissue required²⁰. In contrast, closure is predominantly the result of granulation and re-epithelialisation in diabetic wounds²¹. Simple epithelial repair is not hindered in superficial wounds, but is severely impaired in deeper wounds requiring collagen formation. However, surgical wounds in patients with diabetes probably heal normally⁸.

Advanced therapies

Treatment of extrinsic factors will manage mechanical, vascular and metabolic factors, but if the wound does not respond to the simple wound management strategy outlined above supplementary treatments such as alternative advanced wound healing products (Table 1) may be introduced. Vacuum assisted closure, a topical negative pressure therapy, has also been used to achieve closure of diabetic ulcers, and has been shown on other chronic wound types to reduce bacterial colonisation and diminish oedema and interstitial fluid²².

The use of advanced products will, however, be prohibitive for many practitioners. Comprehensive studies will need to be undertaken to evaluate the cost-effectiveness of these therapies before they become acceptable for general use.

Table 1 | **Advanced therapies**

Tissue-engineered products		
Description	Activity	Research
Engineered skin constructs (neonatal allogeneic fibroblasts/keratinocytes)	Produce growth factors and stimulate angiogenesis	56% of diabetic foot ulcers (DFU) healed* compared to 39% of controls ²³ 50.8% of DFU healed completely* compared to 31.7% of controls ²⁴
Growth factors		
Description	Activity	Research
Platelet-derived growth factor	Attracts neutrophils, macrophages and fibroblasts. Stimulates fibroblast proliferation	Licensed for DFU; 50% of ulcers healed* compared to 35% of controls ²⁵
Bioactive dressings/treatments		
Description	Activity	Research
Esterified hyaluronic acid	Delivers multifunctional hyaluronic acid to the wound	Pilot studies have shown promising results in treating neuropathic DFUs, especially with sinuses ²⁶
Protease modulating matrix	Stimulates angiogenesis by inactivating excess proteases	37% of DFUs healed compared to 28% of controls ^{27,28}

*Achieved statistical significance

AFTER TIME

Each wound is different and requires an individual approach to care. However, within the overall umbrella of wound bed preparation a care strategy for a generic wound type can be defined. For the diabetic foot ulcer the emphasis is on radical and repeated debridement, frequent inspection and bacterial control, and careful moisture balance to prevent maceration. This, linked to pressure control and the management of blood glucose and perfusion, should result in healing.

Diabetic foot ulceration is both a life- and limb-threatening condition. In the case of the diabetic foot, ulceration is an indication of a foot at risk. Recurrent ulceration rates are high and patients are at increased risk of amputation. Management must involve the patient in care and this requires effective education and a foot review programme that addresses the initial cause of ulceration and gives the patient access to appropriate and acceptable footwear.

KEY POINTS

1. Effective management of diabetic foot ulcers requires a multidisciplinary approach and patient involvement. It combines wound care, pressure offloading and diabetic control.
2. Inflammation and infection control is a vital priority to avoid severe tissue damage and amputation.
3. Tissue management in the form of radical and repeated debridement is the main focus of wound bed preparation in the treatment of neuropathic diabetic foot ulcers. This intervention must be used with caution in the neuroischaemic foot.

References

1. Vowden P, Vowden K. The management of diabetic foot ulceration. In: Falanga V (ed.) *Cutaneous Wound Healing*. London: Martin Dunitz 2001; 319-341.
2. Steed DL, Donohoe D, Webster MW, et al. Effect of extensive debridement and treatment on healing of diabetic foot ulcers. *J Am Coll Surg* 1996; 183: 61-64.
3. Koeveker GB. Surgical debridement of wounds. In: Falanga V (ed.) *Cutaneous Wound Healing*. London: Martin Dunitz 2001; 233-245.
4. Apelqvist J, Ragnarson Tennvall G. Cavity foot ulcers in diabetic patients; a comparative study of cadexomer iodine ointment and standard treatment. An economic analysis alongside a clinical trial. *Acta Derm Venereol* 1996; 76: 231-235.
5. Rayman A, Stansfield G, Woollard T, et al. Use of larvae in the treatment of the diabetic necrotic foot. *Diabetic Foot* 1998; 1: 7-13.
6. Pecoraro RE, Reiber GE, Burgess EM. Pathways to diabetic limb amputation: basis for prevention. *Diabetes Care* 1990; 13(5): 513-521.
7. Bowler PG, Duerden BI, Armstrong DG. Wound microbiology and associated approach to wound management. *Clin Microbiol Rev* 2001; 14: 244-269.
8. Edmonds ME, Foster AVM, Sanders L. *A Practical Manual of Diabetic Footcare*. Oxford: Blackwell Publishing, 2004.
9. Ug A, Ceylan O. Occurrence of resistance to antibiotics, metals, and plasmids in clinical strains of *Staphylococcus spp.* *Arch Med Res* 2003; 34(2): 130-136.
10. Armstrong DG, Nguyen HC, Lavery LA, et al. Offloading the diabetic foot wound: a randomised clinical trial. *Diabetes Care* 2001; 24: 1019-1022.
11. Faglia E, Mantero M, Caminiti M, et al. Extensive use of peripheral angioplasty, particularly infrapopliteal, in the treatment of ischaemic diabetic foot ulcers: clinical results of a multicentric study of 221 consecutive diabetic subjects. *J Int Med* 2002; 252(3): 225-232.
12. Kalra M, Gliviczki P, Bower TC, et al. Limb salvage after successful pedal bypass grafting is associated with improved long-term survival. *J Vasc Surg* 2001; 33(1): 6-16.
13. Black E, Vibe-Petersen J, Jorgensen LN, et al. Decrease of collagen deposition in wound repair in type 1 diabetes independent of glycaemic control. *Arch Surg* 2003; 138(1): 34-40.
14. Heart Outcomes Prevention Evaluation Study Investigators. The effects of ramipril on cardiovascular and microvascular outcomes in people with diabetes mellitus: results of the HOPE study and MICRO-HOPE sub study. *Lancet* 2000; 355: 253-259.
15. Jude EB, Blakytyn R, Bulmer J, et al. Transforming growth factor-beta 1, 2, 3 and receptor type I and II in diabetic foot ulcers. *Diabet Med* 2002; 19(6): 440-447.
16. Blakytyn R, Jude EB, Martin Gibson J, et al. Lack of insulin-like growth factor-1 (IGF-1) in the basal keratinocyte layer of diabetic skin and diabetic foot ulcers. *J Pathol* 2000; 190(5): 589-594.
17. Spravchikov N, Szyakov G, Gartsbein M, et al. Glucose effects on skin keratinocytes: implications for diabetes skin complications. *Diabetes* 2001; 50(7): 1627-1635.
18. Duraisamy Y, Slevin M, Smith N, et al. Effect of glycation on basic fibroblast growth factor-induced angiogenesis and activation of associated signal transduction pathways in vascular endothelial cells: possible relevance to wound healing in diabetes. *Angiogenesis* 2001; 4(4): 277-288.
19. Galeano M, Torre V, Deodato B, et al. Raxofelast, a hydrophilic vitamin E-like antioxidant, stimulates wound healing in genetically diabetic mice. *Surgery* 2001; 129(4): 467-477.
20. King L. Impaired wound healing in patients with diabetes. *Nurs Stand* 2001; 15(38): 39-45.
21. Albertson S, Hummel RP, Breeden M, Greenhalgh DG. PDGF and FGF reverse the healing impairment in protein-malnourished diabetic mice. *Surgery* 1993; 114(2): 368-372.
22. Banwell PE, Teot L. Topical negative pressure (TNP): the evolution of a novel wound therapy. *J Wound Care* 2003; 12(1): 22-28.
23. Redekop WK, McDonnell J, Verboom P, et al. The cost effectiveness of Apligraf treatment of diabetic foot ulcers. *Pharmacoeconomics* 2003; 21(16): 1171-1183.
24. Edmonds ME, Foster AVM, McColgan M. Dermagraft: a new treatment for diabetic foot ulcers. *Diabet Med* 1997; 14: 1010-1011.
25. Sibbald RG, Torrance G, Hux M, et al. Cost-effectiveness of becaplermin for non-healing neuropathic diabetic foot ulcers. *Ostomy Wound Manage* 2003; 49(11): 76-84.
26. Edmonds M, Foster A. Hyalofill: a new product for chronic wound management. *Diabetic Foot* 2000; 3(1): 29-30.
27. Ghatnekar O, Willis M, Persson U. Cost-effectiveness of treating deep diabetic foot ulcers with Promogran in four European countries. *J Wound Care* 2002; 11(2): 70-74.
28. Veves A, Sheehan P, Pham HT. A randomised, controlled trial of Promogran (a collagen/oxidised regenerated cellulose dressing) vs standard treatment in the management of diabetic foot ulcers. *Arch Surg* 2002; 137(7): 822-827.

Wound bed preparation for venous leg ulcers

C Moffatt¹, MJ Morison², E Pina³

INTRODUCTION

For most patients with venous leg ulceration the application of high compression bandaging in combination with simple non-adherent dressings is sufficient to stimulate autolytic debridement, control moisture balance and encourage healing within 24 weeks¹. The challenge for effective wound bed preparation is the early detection of those ulcers unlikely to heal by simple compression therapy alone, and for which additional therapeutic interventions may accelerate or facilitate healing. This paper uses the TIME framework (Tissue management, Inflammation and infection control, Moisture balance and Epithelial (edge) advancement) to explore the concept of wound bed preparation for venous leg ulcers.

BEFORE TIME

Venous ulceration results from venous insufficiency or obstruction. Oedema occurs and it is well recognised that graduated, sustained multi-layer compression is the cornerstone of care. Wound bed preparation will not be successful unless the following management principles are taken into account, along with effective patient education and concordance with therapy²:

RISK FACTORS FOR DELAYED HEALING²

- Ulcer duration >6 months
- Ulcer size >10cm²
- Reduced mobility
- Severe pain
- Psychosocial: living alone, social support, clinical depression
- Gender (male)
- Poor general health

- Correct the cause of the ulcer by managing the underlying venous disease (surgical intervention where necessary)
- Improve venous return using high compression therapy
- Create the optimum local environment at the wound site
- Improve the wider factors that may delay healing
- Maintain ongoing assessment to identify changing aetiology
- Maintain a healed limb through a lifetime of compression therapy.

There is currently no internationally agreed standard healing rate of an uncomplicated venous ulcer: reported healing at 12 weeks ranges from 30% to over 75%^{3,4}. Although a number of risk factors for delayed healing are recognised, there are many possible reasons why healing rates vary so widely. However, the percentage of wound reduction during the first three to four weeks of treatment can be used to predict subsequent healing, with a 44% reduction in initial area at week 3 correctly predicting healing in 77% of cases⁵.

TISSUE MANAGEMENT Necrotic tissue

The majority of uncomplicated venous ulcers have relatively little necrotic tissue on the wound surface and do not require debridement. However, it may be beneficial for more complex ulcers, for example where severe infection, uncontrolled oedema and wound dessication may cause tissue necrosis. In addition, ulcers of long duration may develop a chronic fibrinous base, which is pale, shiny and adherent. Removal of this layer using sharp debridement under local anaesthetic may promote healing, but care must be taken to avoid damaging deeper structures⁶. It should be noted that clinicians must be appropriately qualified before undertaking surgical or sharp debridement.

Ulcers lying behind the malleoli are particularly prone to slough development and heal slowly. Limited sharp debridement using forceps and scissors is often sufficient as slough is usually superficial, while simple methods of increasing local pressure to the wound, such as the use of foam shapes or firm padding cut to the contour of the area, can stimulate healing⁷. Adapting the method of compression can also be helpful; for example, an extra layer of bandaging will increase pressure to this area, although care should be taken to ensure there is adequate padding to the dorsum of the foot.

For more adherent slough, debridement using enzymatic preparations may be considered as a practical alternative⁸. Larval therapy can also be considered as an alternative to sharp debridement, although application under compression may be associated with practical challenges. Autolytic debridement using dressings with a high water content, such as hydrogels and hydrocolloids, is slow and clinical experience suggests this is not an effective form of debridement under compression. Although maintenance debridement is recommended for wound bed preparation, this is rarely indicated with venous leg ulcers⁹.

1. Professor and Co-director, Centre for Research and Implementation of Clinical Practice, Thames Valley University, London, UK.

2. Professor of Health and Nursing, School of Social and Health Sciences, University of Abertay, Dundee, UK.

3. Coordinator, National Infection Control Programme, Instituto Nacional de Saúde Dr Ricardo Jorge, Lisboa, Portugal.

Surrounding skin

Surrounding skin problems, such as callus formation and hyperkeratosis, may interfere with healing. The development of hard callus or scabs, for example, may become a source of pressure beneath compression and require careful removal using fine forceps, avoiding trauma to the vulnerable underlying epithelium. Clinical experience suggests that soaking in warm water with emollient for more than 10 minutes can facilitate tissue removal. Bleeding after debridement may be resolved by the application of a haemostat such as an alginate and compression.

INFLAMMATION AND INFECTION CONTROL

Bacteria may stimulate a persisting inflammation leading to the production of inflammatory mediators and proteolytic enzymes. Amongst many other effects this causes extracellular matrix (ECM) degradation and inhibition of re-epithelialisation¹⁰. Bacterial burden must therefore be controlled to facilitate healing or to maximise the effectiveness of newer therapeutic techniques such as bioengineered skin or growth factors.

The diagnosis of wound infection is a clinical skill based on careful history taking and clinical observation. Infection in venous ulcers is usually localised and there may be cellulitis. On rare occasions, particularly where the patient is immunocompromised, systemic infection may develop. Leucocytosis and acute-phase reactants such as erythrocyte sedimentation rate and C-reactive protein are not reliable since these patients are constantly challenged by minor illnesses and peripheral lesions that may elevate these indices. It is therefore necessary to be aware of other signs often presenting in these wounds, such as an increase in the intensity or change in the character of pain (see Box)¹¹⁻¹³.

INDICATORS OF INFECTION IN VENOUS ULCERS^{11,12}

- Increased intensity and/or change in character of pain
- Discoloured or friable granulation tissue
- Odour
- Wound breakdown
- Delayed healing

Note: The classical signs and symptoms of infection (pain, erythema, heat and purulence) may be reduced¹³ or masked by dermatological problems

Microbiological diagnosis should be limited to situations where there is a clear indication that the bacterial load is implicated in delayed healing. Quantification of bacteria by wound biopsy has been considered the gold standard but surface sampling is easier and less costly, and it is increasingly suggested that bacterial synergistic interaction is more important than the precise number, as a greater diversity (i.e. more than four species) is associated with non-healing^{14,15}. Anaerobic organisms are considered to have at least as great a negative impact on healing as aerobes¹⁴. *Staphylococcus aureus* and *Pseudomonas aeruginosa* are the bacteria most commonly isolated in infected leg ulcers, but are also found in non-infected wounds. Haemolytic streptococci are not commonly found in leg ulcers, but can be a particular cause for concern and can lead to massive tissue damage if not recognised and treated effectively and promptly¹³. It is, however, difficult to define the role of individual species in polymicrobial infections^{14,15}. Other organisms such as mycobacteria, fungi and viruses as well as parasites such as *Leishmania* may be implicated in a differential diagnosis¹⁶.

Treatment

It is essential to enhance host resistance by correcting the underlying vascular disease and eliminating or reducing risk factors including smoking, heart failure, oedema, pain, malnutrition and the effects of medications such as steroids and immunosuppressive agents. While management of infection is determined by local wound characteristics, clearing devitalised tissue and foreign bodies is the first step to restoring bacterial balance. This can be achieved through exudate control, cleansing with sterile saline and sharp debridement where indicated, or other methods of debridement including larval therapy¹⁷.

Antimicrobial treatments

In wounds that exhibit local signs of infection or fail to heal in spite of appropriate care, topical antiseptics should be considered. In addition to the choice of product, the form and system of delivery are important¹⁸. Antiseptic solutions are not indicated because of toxicity^{19,20}.

The role of antiseptics was recently reappraised²¹; a number of new sustained slow-release formulations of iodine and silver were found to reduce bacterial burden safely and efficiently. When selecting antiseptic-containing dressings²², in addition to

antibacterial properties, other characteristics such as moisture retention, absorption of endotoxins²³, reduction of inflammation²⁴ and pain relief²⁵ should be considered.

Antiseptics are preferable because resistance is not yet a clinical problem, although concern has been raised about the possibility of selecting antimicrobial-resistant strains²⁶. If no improvement is observed in two weeks antiseptic treatment should cease, the wound should be reassessed and systemic antibiotics may be considered. Topical antibiotics can deliver high concentrations to the wound while minimising the risk of systemic toxicity; however, cutaneous sensitisation, inactivation, inhibition of healing as well as a selection of resistant strains have been reported²⁷ and they are therefore not recommended. Metronidazole gel has been used to manage odour and reduce anaerobic colonisation²⁸, while fusidic acid and mupirocin are active against gram-positive bacteria including methicillin-resistant *Staphylococcus aureus*. Polymyxin B, neomycin and bacitracin should not be used because of allergy. Systemic antibiotics should be used when there are signs of systemic invasion, cellulitis, or when active infection cannot be managed using local therapies.

MOISTURE BALANCE

Venous leg ulcers usually produce copious exudate, which can delay healing and cause maceration of the surrounding skin²⁹. Chronic exudate causes the breakdown of extracellular matrix proteins and growth factors, prolongs inflammation, inhibits cell proliferation, and leads to the degradation of tissue matrix³⁰⁻³². Its management is therefore vital to wound bed preparation³³.

The removal of oedema using sustained compression therapy is fundamental to achieving moisture balance². Compression helps to optimise local moisture balance by reducing exudate production and tissue maceration and to ensure adequate tissue perfusion by improving venous return.

Compression therapy can be achieved using a variety of methods such as bandages, hosiery and intermittent pneumatic compression². Choice of method depends on resources available, patient mobility, the size and shape of the affected leg and patient preference. If venous ulcers continue to produce copious exudate and there are signs of oedema, compression may be inadequate. Bandages may need to be changed more frequently if soiled by excessive exudate or if the limb circumference is reduced markedly, when remeasuring of the ankle circumference may be necessary.

To assist the action of compression, patients should be advised to avoid standing for long periods and to elevate their legs above heart level when sitting or lying down. These steps can make a sufficient difference to allow healing in an otherwise static ulcer.

Venous ulcers require basic moist wound healing principles, as dryness of the ulcer bed is rarely a problem. Simple measures such as washing the lower limbs and effective skin care are important.

Dressing selection should take account of a number of factors. They should minimise tissue trauma, absorb excess exudate, manage slough/necrotic tissue and be hypo-allergenic. Where possible adhesive dressings should be avoided as they increase the risk of allergic reactions or contact dermatitis³⁴. Dressing performance may be affected by compression, especially those designed to deal with high levels of exudate, as compression may affect the lateral flow of fluid within the dressing³⁵.

Hydration and protection of the skin using paraffin-based products or zinc paste is a fundamental aspect of care. However, these must be removed regularly by washing or they may form a thick layer preventing removal of dead keratinocytes and promoting the development of varicose eczema and hyperkeratosis.

Maceration may occur around the margins of venous ulceration and is manifested as white, soggy tissue³⁵. Areas of erythema may also be present where exudate is in contact with vulnerable skin. This can lead to the development of irritant dermatitis and new areas of ulceration³⁶.

PREVENTING MACERATION

- Use paraffin-based products or zinc paste as a barrier
- Select appropriately sized dressing capable of handling high exudate levels such as foams and capillary action dressings
- Carefully position the dressing so that exudate does not run below the wound
- Silver and iodine products can be used if excess exudate is caused by infection
- Avoid hydrocolloids and films

EPITHELIAL (EDGE) ADVANCEMENT

If the epidermal margin fails to migrate across the wound bed there are many possible reasons, including hypoxia, infection, desiccation, dressing trauma, overgrowth of hyperkeratosis and callus at the wound margin. Careful clinical observation can help to determine the cause, although this will not reveal defects in the underlying cell biology.

The presence of islands of epithelium originating from hair follicles and evidence of edge stimulation at the wound margin are useful indicators of healing. However, newly formed epithelial cells can be difficult to identify as they are partly translucent and may be hidden by slough, fibrous tissue or exudate.

Advanced therapies

Despite adequate wound bed preparation using standard methods some wounds fail to heal or heal slowly. This may be the consequence of a disordered healing response resulting from inappropriate cytokine, growth factor, protease and reactive oxygen species production by cells within granulation tissue, which leads to non-resolving inflammation, poor angiogenesis, ECM degradation and non-migration of epithelial cells from the wound margin. Treatment, leading to reversal of these defects, allows initiation of healing, as shown by modification of the ECM structure, which precedes re-epithelialisation in leg ulcers³⁷.

Based on this knowledge a number of advanced treatment strategies have been devised that show interesting results with recalcitrant wounds (Table 1). They are, however, only likely to be successful if applied to a well-prepared wound bed⁹.

Tissue engineering

Grafting of autologous skin to a prepared wound bed has been used to stimulate healing for many years³⁸. However, this suffers from the disadvantage of donor site pain, scarring and the possibility of infection. Recent advances in cell culture

Table 1 | **Advanced therapies**

Tissue-engineered products		
Description	Activity	Research
Engineered skin constructs (neonatal allogeneic fibroblasts/keratinocytes)	Produce growth factors and stimulate angiogenesis	More effective than conventional venous leg ulcer (VLU) therapy in a clinical trial ⁴⁴ Activity demonstrated in VLU ⁴⁵ . Results of ongoing trials awaited with interest
Growth factors		
Description	Activity	Research
Granulocyte monocyte colony stimulating factor	Activates monocytes, stimulates proliferation and migration of keratinocytes, modulates fibroblasts	Enhanced healing rates with VLU ⁴⁶
Keratinocyte growth factor	Stimulates proliferation of keratinocytes and migration of keratinocytes and fibroblasts	Enhanced healing rates with VLU ⁴⁷
Bioactive dressings/treatments		
Description	Activity	Research
Esterified hyaluronic acid	Delivers multifunctional hyaluronic acid to the wound	Pilot study demonstrates initiation of healing in VLU ⁴⁸
Protease modulating matrix	Stimulates angiogenesis by inactivating excess proteases	62% of VLU improved over 8 weeks compared to 42% in control group ⁴⁹

techniques allow expansion of cells *in vitro*, which are then used to populate biocompatible scaffolds to act as a carrier and substitute for split-thickness skin grafts. Cells may be either autologous or from allogeneic donors. This treatment has the added advantage that the transplanted cells interact in the healing process by producing growth factors that may also act to stimulate healing³⁹.

Growth factors

The growth factor networks that regulate healing may become degraded⁴⁰ and disorganised in the chronic wound⁴¹. This leads to the concept that supplying exogenous growth factors to the wound microenvironment may stimulate healing. Many have been evaluated but platelet-derived growth factor is, to date, the first growth factor to be licensed for topical application and only in diabetic ulcers⁴².

Bioactive dressings/treatments

Modern wound dressings developed to maintain a moist wound environment have recently evolved into a new generation of products that interact with the wound to stimulate healing. Examples are protease modulating dressings, which claim to stimulate healing by inactivating excess proteases⁴³ and a range of products, based on esterified hyaluronic acid, which deliver multifunctional hyaluronic acid to the wound²⁹.

Protease inhibitors

A novel synthetic inhibitor of protease activity has recently been described¹⁰ that inhibits ECM-degrading enzymes without affecting those proteases required for normal keratinocyte migration. This suggests it will be feasible in the future to develop highly specific pharmacologic agents to treat defects of non-healing wounds.

CONCLUSION

The general aims of wound bed preparation are as relevant to the management of venous leg ulcers as any other wound type. However, its different elements do not have equal emphasis. Debridement is rarely an issue; the main priority in the management of venous ulcers is to achieve moisture balance by improving venous return using sustained compression. Edge stimulation is intrinsically linked to moisture balance, as without optimal moisture balance epidermal migration will not occur.

In addition to problems of limited resources, it is usually unnecessary to use advanced wound care products with venous leg ulcers. The challenge in managing these wounds is to predict, perhaps as early as the fourth week of standard care, which ulcers will fail to heal rapidly, as these patients benefit the most from alternative care strategies. In addition, further longitudinal studies are needed to evaluate their efficacy and cost-effectiveness in particular clinical situations so that they can be targeted at the patients most likely to benefit from these strategies.

KEY POINTS

1. Most venous leg ulcers will heal with the application of high compression bandaging and simple non-adherent dressings.
2. The challenge is to predict as early as the fourth week of standard care which ulcers will benefit from wound bed preparation and the use of advanced therapies.
3. Using the TIME framework, it can be seen that the main priority with venous leg ulcers is to achieve moisture balance. Although tissue management and infection control are rarely an issue, rigorous attention must be paid to these components if there are problems with healing or where advanced therapies are required.

References

- Effective Healthcare. Compression therapy for venous leg ulcers. *Effective Healthcare Bulletin* 1997; 3(4).
- European Wound Management Association (EWMA). Position document: *Understanding Compression Therapy*. London: MEP Ltd, 2003.
- Harper DR, Nelson EA, Gibson B, et al. A prospective randomised trial of Class 2 and Class 3 elastic compression in the prevention of venous ulceration. *Phlebology* 1995; Suppl 1: 872-873.
- Moffatt CJ, Franks PJ, Oldroyd M, et al. Community clinics for leg ulcers and impact on healing. *BMJ* 1992; 305: 1389-1392.
- Flanagan M. Wound measurement: can it help us to monitor progression to healing? *J Wound Care* 2003; 12(5): 189-194.
- Vowden KR, Vowden P. Wound debridement, Part 2: sharp techniques. *J Wound Care* 1999; 8(6): 291-294.
- Moffatt CJ, Harper P. *Leg Ulcers: Access to clinical education*. New York: Churchill Livingstone, 1997.
- Westerhof W, van Ginkeel CJ, Cohen EB, Mekkes JR. Prospective randomised study comparing the debriding effect of krill enzymes and a non-enzymatic treatment in venous leg ulcers. *Dermatologica* 1990; 181(4): 293-297.
- Schultz GS, Sibbald RG, Falanga V, et al. Wound bed preparation: a systematic approach to wound management. *Wound Repair Regen* 2003; 11(2): Suppl S1-S28.
- Fray MJ, Dickinson RP, Huggins JP, Ocleston NL. A potent, selective inhibitor of matrix metalloproteinase-3 for the topical treatment of chronic dermal ulcers. *J Med Chem* 2003; 46(16): 3514-3525.
- Cutting K, Harding K. Criteria for identifying wound infection. *J Wound Care* 1994; 3(4): 198-201.
- Gardner SE, Frantz RA, Doebbeling BN. The validity of the clinical signs and symptoms used to identify chronic wound infection. *Wound Repair Regen* 2001; 9(3): 178-186.
- Thomson PD, Smith DJ. What is infection? *Am J Surg* 1994; 167(Suppl 1A): 7S-11S.
- Bowler PG. Wound pathophysiology, infection and therapeutic options. *Ann Med* 2002; 34: 419-427.
- Trengove NJ, Stacey MC, McGeachie DF, Mata S. Qualitative bacteriology and leg ulcer healing. *J Wound Care* 1996; 5(6): 277-280.
- Cardenas GA, Gonzalez-Serva A, Cohen C. The clinical picture: multiple leg ulcers in a traveller. *Cleve Clin J Med* 2004; 71(2): 109-112.
- Beasley WD, Hirst G. Making a meal of MRSA: the role of biosurgery in hospital-acquired infection. *J Hosp Inf* 2004; 56: 6-9.
- Eaglestein WH, Falanga V. Chronic wounds. *Surg Clin North Am* 1997; 77(3): 689-700.
- Mertz PM, Alvarez OM, Smerbeck RV, Eaglestein WH. A new *in vivo* model for the evaluation of topical antiseptics on superficial wounds. *Arch Dermatol* 1984; 120: 58-62.
- Hansson C, Faergemann J. The effect of antiseptic solutions on microorganisms in venous leg ulcers. *Acta Derm Venereol (Stockh)* 1995; 75: 31-33.
- Drosou A, Falabella A, Kirsner RS. Antiseptics on wounds: an area of controversy. *Wounds* 2003; 15(5): 149-166.
- Wright JB, Lam K, Olson ME, et al. Is antimicrobial efficacy sufficient? A question concerning the benefits of new dressings. *Wounds* 2003; 15(5): 133-142.
- Ovington LG. Bacterial toxins and wound healing. *Ostomy Wound Manage* 2003; 49 (7A Suppl): 8-12.
- Fumal I, Braham C, Paquet P, et al. (2002) The beneficial toxicity paradox of antimicrobials in leg ulcer healing impaired by a polymicrobial flora: a proof-of-concept study. *Dermatol* 2002; 204(Suppl 1): 70-74.
- Sibbald RG, Torrance GW, Walker V, et al. Cost-effectiveness of Apligraf in the treatment of venous ulcers. *Ostomy Wound Manage* 2001; 47(8): 36-46.
- Russell AD. Biocide use and antibiotic resistance: the relevance of laboratory findings to clinical and environmental situations. *Lancet Infect Dis* 2003; 3(12): 794.
- Degreef HJ. How to heal a wound fast. *Dermatol Clin* 1998; 16(2): 365-375.
- Witkowski JA, Parish LC. Topical metronidazole gel. The bacteriology of decubitus ulcers. *Int J Dermatol* 1991; 30(9): 660-661.
- Chen WY, Abatangelo G. Functions of hyaluronan in wound repair. *Wound Repair Regen* 1999; 7(2): 79-89.
- Falanga V, Grinnell F, Gilchrist B, et al. Workshop on the pathogenesis of chronic wounds. *J Invest Dermatol* 1994; 102(1): 125-127.
- Trengove NJ, Stacey MC, MacAuley S, et al. Analysis of the acute and chronic wound environments: the role of proteases and their inhibitors. *Wound Repair Regen* 1999; 7(6): 442-452.
- Barrick B, Campbell EJ, Owen CA. Leukocyte proteinases in wound healing: roles in physiologic and pathologic processes. *Wound Repair Regen* 1999; 7(6): 410-422.
- Ennis WJ, Meneses P. Wound healing at the local level: the stunned wound. *Ostomy Wound Manage* 2000; 46(1A Suppl): 39S-48S.
- Cameron J. Skin care for patients with chronic leg ulcers. *J Wound Care* 1998; 7(9): 459-462.
- Cutting K. The causes and prevention of maceration of the skin. *J Wound Care* 1999; 8(4): 200-201.
- Vowden K, Vowden P. Understanding exudate management and the role of exudate in the healing process. *Br J Nurs* 2003; 12(20): (Suppl) S4-S13.
- Herrick SE, Sloan P, McGurk M, et al. Sequential changes in histologic pattern and extracellular matrix deposition during the healing of chronic venous ulcers. *Am J Pathol* 1992; 141(5): 1085-1095.
- Kantor J, Margolis DJ. Management of leg ulcers. *Semin Cutan Med Surg* 2003; 22(3): 212-221.
- Martin TA, Hilton J, Jiang WG, Harding K. Effect of human fibroblast-derived dermis on expansion of tissue from venous leg ulcers. *Wound Repair Regen* 2003; 11(4): 292-296.
- Yager DR, Chen SM, Ward SI, et al. Ability of chronic wound fluids to degrade peptide growth factors is associated with increased levels of elastase activity and diminished levels of proteinase inhibitors. *Wound Repair Regen* 1997; 5: 23-32.
- Agren MS, Eaglestein WH, Ferguson MW, et al. Causes and effects of chronic inflammation in venous leg ulcers. *Acta Derm Venereol Suppl (Stockh)* 2000; 210: 3-17.
- Guzman-Gardeazabal E, Leyva-Bohorquez G, Salas-Colin S, et al. Treatment of chronic ulcers in the lower extremities with topical becaplermin gel .01%: a multicenter open-label study. *Adv Ther* 2000; 17(4): 184-189.
- Cullen B, Smith R, McCulloch E, et al. Mechanism of action of Promogran, a protease modulating matrix, for the treatment of diabetic foot ulcers. *Wound Repair Regen* 2002; 10(1): 16-25.
- Fivenson D, Scherschun L. Clinical and economic impact of Apligraf for the treatment of non-healing venous leg ulcers. *Int J Dermatol* 2003; 42(12): 960-965.
- Roberts C, Mansbridge J. The scientific basis and differentiating features of Dermagraft. *Can J Plast Surg* 2002; 10(Suppl A): 6A-13A.
- Da Costa RM, Ribeiro Jesus FM, Aniceto C, Mendes M. Randomised, double-blind, placebo-controlled, dose-ranging study of granulocyte-macrophage colony stimulating factor in patients with chronic venous leg ulcers. *Wound Repair Regen* 1999; 7(1): 17-25.
- Robson MC, Phillips TJ, Falanga V, et al. Randomised trial of topically applied Repifermin (recombinant human keratinocyte growth factor-2) to accelerate wound healing in venous ulcers. *Wound Repair Regen* 2001; 9(5): 347-352.
- Colletta V, Dioguardi D, Di Lonardo A, et al. A trial to assess the efficacy and tolerability of Hyalofill-F in non-healing venous leg ulcers. *J Wound Care* 2003; 12(9): 357-360.
- Vin F, Teot L, Meaume S. The healing properties of Promogran in venous leg ulcers. *J Wound Care* 2002; 11(9): 335-341.

WOUND BED PREPARATION

 A clinical concept led by **smith&nephew**

TIME* - defining the principles of wound bed preparation

The TIME principles provide a systematic approach to the management of wounds. TIME is based on intervention in four clinical areas and aims to establish an optimal well vascularised wound bed that facilitates the effectiveness of other therapeutic measures.

TIME - Clinical observations:

- Tissue - non-viable or deficient
- Infection or inflammation
- Moisture imbalance
- Edge of wound - non advancing or undermined

*Courtesy of International Advisory Board on Wound Bed Preparation
Schultz GS, Sibbald RG, Falanga V et al (2003) Wound Rep Reg: 11:1-28

www.smith-nephew.com

www.woundbedpreparation.com