

# Topical oxygen therapy used to improve wound healing in a large retrospective study of wounds of mixed aetiology

### Authors:

Hanna Kaufman, Maxim Gurevich, Eran Tamir, Elad Keren, Lipkin Alexander and Greif Edward

Chronic wounds are one of the most prevalent and costly conditions in developed countries and are a heavy burden on patient quality of life. Treating the underlying metabolic demands of tissue can help wound healing, including delivering supplemental oxygen to hypoxic wound tissue. In this large 200-patient retrospective study, it is demonstrated that topically administered oxygen can increase healing in chronic wounds of all aetiologies. Topical oxygen was most effective in venous ulcers (VLUs), and achieved an average VLU closure of 52% over the study period. Longer treatment times were associated with more effective wound healing, as evidenced by an average wound closure of 67.9% in VLUs treated for >25 days. Portable topical oxygen delivery devices provide an effective therapeutic option for home-based wound care during the COVID-19 pandemic and beyond.

**Hanna Kaufman** is Head of Department; Northern District Trauma & Wound Clinics Division, Maccabi Health Care Services, Haifa, Israel; **Maxim Gurevich** is Orthopedic Surgeon, Department of Orthopedic Surgery, Hillel Yaffe Medical Center, Hadera, Israel; **Eran Tamir** is Orthopedic Surgeon, Department of Orthopedic Surgery, Assaf Harofeh Medical Center, Foot and Ankle Unit, Be'er Ya'akov, Israel; **Elad Keren** is Orthopedic Surgeon, Maccabi Health Care services and Orthopedic Department, Soroka Medical Center, Beersheba, Israel; **Lipkin Alexander** is Senior Orthopedic Surgeon, Department of Chronic Wounds Maccabi Health Care Services, Rishon Lezion, Israel and Wolfson Medical Center, Foot and Ankle unit, Holon, Israel; **Greif Edward** is Senior Orthopaedic Surgeon, Head of Diabetic Foot Service, Department of Orthopaedics, Carmel Medical Center, Haifa, Israel; Head of Multidisciplinary Center for Diabetic Foot and Non Healing Wounds, Hashalom, Maccabi Health Care Services, Tel Aviv, Israel

**W**ound healing follows a complex series of sequential steps, involving multiple cell types and signalling pathways (Oliveira et al, 2020). The metabolic demands of cells involved in repairing the skin defect and in preventing infection are high, including an increased need for oxygen. Unfortunately, wounds are common in tissues where oxygen may already be depleted: diabetic foot ulcers, pressure ulcers, venous stasis and arterial ulcers all involve compromised haemodynamics and lower-tissue oxygen delivery (Gordillo and Sen, 2003; Frykberg and Banks, 2015). These wounds may become chronic without essential nutrients to feed tissue regeneration and may not heal for months (or years) despite the best efforts of clinicians (Frykberg and Banks, 2015; Oliveira et al, 2020).

In fact, wounds are one of the most prevalent and costly pathologies in developed countries, accounting for healthcare expenditures of US\$97bn in the US (Nussbaum et al, 2018) and £5.3bn in the UK, annually (Guest et al, 2015). While many advanced wound products exist to

control infection and moisture etc in the acute wound healing stage, addressing the underlying causes of failure-to-heal in chronic wounds is the next great leap in wound care.

Oxygen is an essential part of wound healing, with important roles in the energetics of wound contracture, the formation of granulation tissue and in healing by secondary intention (Kallianen et al, 2003). Due to increased cellular metabolism and immune cell function consume oxygen rapidly in a healing wound, therapies designed to supplement wound O<sub>2</sub> are used increasingly frequently, albeit with mixed reports of effectiveness.

Until recently, hyperbaric oxygen therapy (in which the patient sits in a pressurised oxygen chamber for several hours a week) was the preferred method of supplemental oxygen delivery, but the COVID-19 pandemic has shifted as much non-emergency care to smaller clinics and the home, such that hyperbaric therapy may not be as accessible for chronic wound patients going forward (Rogers et al, 2020). Smaller pressurised chambers (in which

Table 1. Study inclusion and exclusion criteria.

Inclusion criteria	Exclusion criteria
<p>a. The subjects are women and men, aged 18 and over.</p> <p>b. The subject has a chronic non-healing wound.</p> <p>c. Subject's wound is free from spreading infection.</p> <p>d. The subject is able to obey protocol requirements.</p>	<p>a. The subject is unable to use NATROX® device (charging and replacing batteries on a daily basis).</p> <p>b. The subject has a fully necrotic wound, or it is clinically necessary to cover the wound with a gel or cream that will prevent oxygen from reaching the wound surface.</p> <p>c. The subject receives therapy for active malignant disease, or if the subject has past history of malignancy within the wound.</p> <p>d. The subject is pregnant or breastfeeding.</p> <p>e. The subject has other concomitant states, which the researcher believes may jeopardise his/her safety.</p> <p>f. Simultaneous participation in another clinical trial, which includes a drug for clinical trial or preparation that may disrupt the current experiment.</p>

Table 2. Study population wound characteristics.

		Healed (% of n)	Healing (% of n)	Slow responders (% of n)	Non-responders (% of n)
Wound type	Arterial (n=32)	5 (16%)	5 (16%)	8 (25%)	14 (44%)
	DFU (n=31)	8 (26%)	10 (32%)	6 (19%)	7 (23%)
	Pressure ulcer (n=13)	4 (31%)	3 (23%)	3 (23%)	3 (23%)
	Venous (n=99)	34 (34%)	25 (25%)	22 (22%)	18 (18%)
	Other (n=25)	5 (20%)	9 (36%)	2 (8%)	9 (36%)
Wound duration prior to study commencement	1 month (n=29)	5 (17%)	9 (28%)	6 (20%)	9 (31%)
	2-6 months (n=83)	27 (33%)	20 (24%)	13 (16%)	23 (28%)
	7-11 months (n=24)	7 (29%)	6 (25%)	4 (17%)	7 (29%)
	12-24 months (n=36)	14 (39%)	4 (11%)	9 (25%)	9 (25%)
	>24 months (n=19)	3 (16%)	10 (53%)	4 (21%)	2 (11%)

the affected limb only is enclosed) have been shown to significantly increase rates of healing in large placebo-controlled trials (Niederauer et al, 2018; Frykberg et al, 2020), without the side effects or contraindications of hyperbaric oxygen. Outpatient wearable technologies like the NATROX Oxygen Wound Therapy system have shown great promise in healing both diabetic foot ulcers (Yu et al, 2016) and venous ulcers (Kaufman et al, 2018), and offer the distinct advantage of portability and continuous delivery of oxygen therapy. These smaller, nimble and evidence-based oxygen therapeutics offer significant hope to wound care clinicians struggling to treat patients effectively during the pandemic.

In this work, we report results from a large multi-centre study on chronic wound of mixed aetiology treated using the NATROX® Oxygen Wound Therapy system (Inotec AMD). Our goal was to further elucidate the conditions under which topical oxygen is most effective in healing chronic wounds. Venous leg ulcers were the most successfully treated chronic wound type in our study, and treatment time >25 days made significant impacts on wound closure of even long-term chronic wounds. These results add to a growing body of evidence that topical oxygen is an important tool to help kick-start healing in chronic, hard-to-heal wounds.

## Materials and methods

The data for this study were taken from Maccabi Healthcare Services database, where patient information and wound progression are routinely and consistently monitored. All included patients had been previously treated with best practice wound care but their wounds had failed to heal. Subsequently, these patients were treated with topical oxygen therapy (NATROX) for chronic wounds of any aetiology. Inclusion and exclusion criteria for 200 patients recruited under ethics board approval are listed in *Table 1*.

For the purposes of recruitment, there was no restriction placed on wound chronicity, upper wound size limit or Ankle-Brachial Pressure Index (ABPI) level. Wounds continued to receive best practice wound care in conjunction with topical oxygen therapy and their wounds were photographed and measured with an analogue ruler to assess wound healing as per standard practice. The following data were collated for each study participant: age, sex, smoking status, alcohol consumption status, existing wound (in months), starting date, wound length and width measurement, as well as wound location,

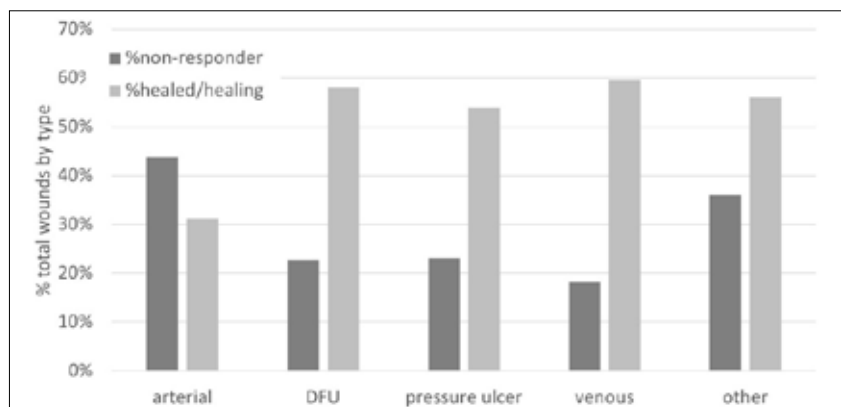


Figure 1. Wounds grouped according to healing status.

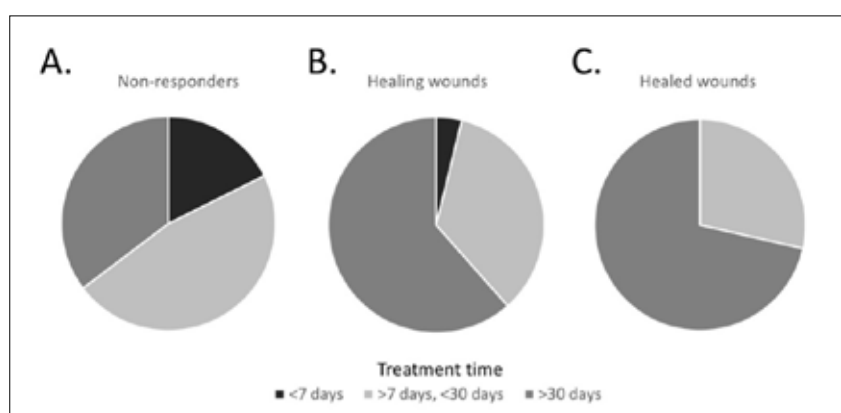


Figure 2. Treatment time affects outcome.

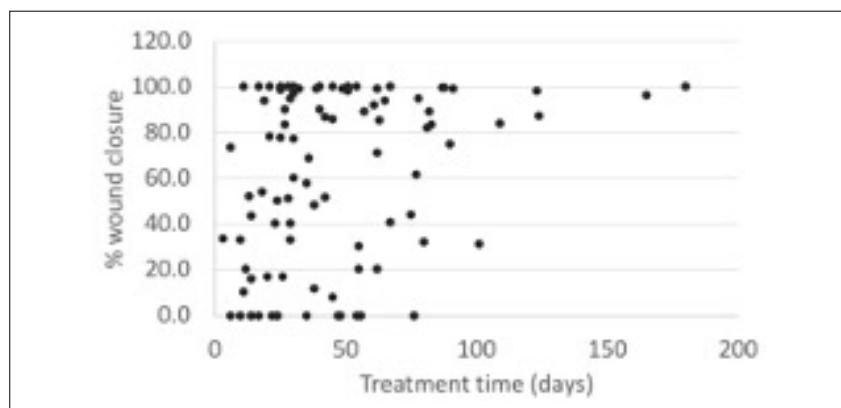


Figure 3. Percent wound closure in chronic venous leg ulcers treated with topical oxygen therapy over time.

end of treatment date, treatment duration, wound measurements by the end of treatment, comorbidities, additional indications, photos, whether the wound has closed, patient consent.

## Results

This trial included a large sample size of 200 patients with chronic wounds of diverse aetiology [Table 2]. Venous ulcers were the most common wound type among study participants (representing 50% of total chronic wounds), followed by arterial ulcers (16% of

participants) and diabetic foot ulcers (DFUs, 15% of participants). The average age of study participants was  $69.3 \pm 15.0$  years, and 61.5% of the study population was over 65 years old. The majority (61%) of study participants were men, and wounds had been open for an average of  $10.7 \pm 15.7$  months prior to study initiation.

In utilising a large and diverse sample of wound types, the author was able to determine the conditions under which topical oxygen therapy was most effective. All wounds in this trial were deemed non-healing prior to the commencement of therapy. Due to the heterogeneous nature of the wounds sampled in our large cohort, wounds were grouped into four categories for analysis: 1) wounds that were >90% healed (“healed”); 2) wounds that transitioned from non-healing to “healing” following topical oxygen therapy (>50% closed); 3) wounds that were “slow responders” (closed <50%, but >10% in the study period); or 4) wounds that were <10% closed (“non-responders”).

The characteristics of wounds in each category were then compared, focusing on the differences in characteristics of wounds that had healed/were healing versus non-responders, in order to determine the optimal conditions under which topical oxygen is most effective. There was no significant difference in the length of time wounds had been open prior to therapy (healed wounds open for  $9.6 \pm 9.9$  months, non-responder wounds open for  $6.9 \pm 6.6$  months,  $P=0.1$ ; Table 2). Wounds were then grouped by type and it was determined how many wounds of a given type fell into our three categories [Figure 1]. Topical oxygen was effective in healing DFUs, pressure ulcers and “other” chronic wounds, but was most effective in healing chronic venous leg ulcers (60% VLU in the healed/healing group versus 18% in the non-responder group), and an overall reduction in VLU wound area of 52% was achieved with topical oxygen therapy. Arterial ulcers were the least likely to respond to topical oxygen therapy, although 31% of total previously non-healing arterial ulcers still healed or were healing during the study period.

An interim analysis (at 100 patients enrolled; Kaufman et al, 2018) indicated that chronic wounds treated for >25 days showed a significantly better response to therapy than those treated for a shorter time. Therefore, the entire cohort of 200 wounds was examined for treatment time and performed a sub-analysis for treatment times of healed/healing wounds versus non-responders. Chronic wounds of

all aetiologies that healed were treated for an average of 46 days ( $\pm 30.5$  days), significantly longer than the 29.3 ( $\pm 18.8$  days) than unhealed wounds were treated ( $P=0.002$ ; *Figure 2*). As a case in point, VLUs treated for  $>25$  days achieved an average reduction in area of 67.9% ( $\pm 35.3\%$ ), almost double the reduction in area seen in VLUs treated for  $<25$  days (36.6%  $\pm 36.4\%$ ) [*Figure 3*]. This difference may also mean that the “slow responder” category would have progressed to healed/healing if treatment time had been extended further. While some types of chronic wounds were quicker to respond to topical oxygen than others, these results confirm that extended treatment times are critical to the success of topical oxygen therapy.

### Discussion

Wound healing requires dynamic interactions between cells, proteases, growth factors and extracellular matrix components. Adequate oxygen is central to the wound healing cascade, supplying cellular energy in the form of ATP for fibroblast proliferation, collagen deposition, and angiogenesis (Vas and Papanas, 2019). These high metabolic demands can turn healing tissue hypoxic even in the absence of vascular problems, such that supplemental oxygen is often used as an adjunctive wound therapy, particularly in chronic wounds in which the healing cascade has stalled.

Moreover, supplying oxygen in adequate amounts promotes angiogenesis and the formation of higher tensile strength collagen during wound healing, which may reduce both scarring and the risk of wound recurrence (Tawfick and Sultan, 2009). At face value, oxygen could benefit chronic wounds of many aetiologies. However, not all wounds respond to supplemental oxygen equally and a shotgun approach to its therapeutic use has done harm to its reputation by diluting positive effects with non-responders. The goal of the study was to contribute to a better understanding of the therapeutic conditions under which topical oxygen works best using a large diverse sample of chronic wounds.

The most prevalent wounds in our study were venous leg ulcers (VLUs). VLUs account for 80% of all leg ulcers, and are especially common in older individuals (Kirsner and Vivas, 2015). There are approximately 2.2 million VLUs in the US annually, with an associated estimated treatment cost of US\$14.9bn/year (Kirsner et al, 2020). In the UK, venous ulcer prevalence has been estimated to be 0.3% of the population, costing the NHS £400m per year (Tawfick and Sultan, 2009).

As the world's population ages, the prevalence of VLUs is set to rise accordingly, with correspondingly high morbidity in patients suffering from chronic wounds. Venous ulcers arise due to chronic venous insufficiency and the resulting venous hypertension can cause leakage of macromolecules like fibrinogen into the tissue (Falanga et al, 1987; Kirsner and Vivas, 2015). There, fibrinogen polymerises to form fibrin 'cuffs' around capillaries, which limit nutrient and oxygen diffusion into tissues, and cause hypoxia that leads to ulceration. While most often treated with elevation or compression to decrease venous pressure, some VLUs remain recalcitrant to therapy.

Moreover, rates of recurrence as high as 70% at one year suggest that alternative therapies are necessary to promote healing and prevent ulcer recurrence. We achieved an average of 52% reduction in highly chronic VLU surface area with topical oxygen therapy (68% surface area reduction with treatment  $>25$  days), including full wound closure in 33% of long-term chronic VLUs. While complete healing may be an obvious endpoint, using topical oxygen therapy prior to revascularisation may be a helpful adjunctive treatment to reduce wound size prior to surgery. These results add to a growing body of evidence confirming the effectiveness of topical oxygen therapy in the treatment of chronic venous ulcers (Tawfick and Sultan, 2009; 2013; Kaufman et al, 2018).

Beyond identifying a clear benefit to topical oxygen therapy in chronic VLUs, this study also confirmed that longer treatment times achieved better wound healing outcomes. Confirming results of the author's interim analysis at 100 patients (Kaufman et al, 2018), 33% of wounds treated for  $>25$  days in the second cohort of 100 patients achieved wound closure (vs. only 14% of wounds treated for  $<25$  days). In a study of VLUs treated with the AOTI HyperBox device, Tawfick et al (2013) reported a median time to full healing of 57 days for topical oxygen-treated wounds.

Similarly, Copeland and Purvis (2017) found a link between treatment time and healing in a large retrospective chart review of 4,127 wounds treated with topical oxygen. Wound that healed were treated for a median of 82 days with the GWR Medical O2Boot or O2Sacral device, longer than wounds that did not heal. In contrast to both devices from GWR Medical and the HyperBox device, the NATROX Oxygen Wound Therapy system system is designed for use as a portable device on an outpatient basis. Given the clear increase in effectiveness of

longer treatment regimes, having an outpatient-based device (particularly during the COVID-19 pandemic) is advantages for healthcare providers, healthcare systems in times of crisis, and patient quality of life.

## Limitations

This study included a large sample size, which included wounds of diverse aetiology, size and duration prior to study commencement. The sample was predominantly venous ulcers, which limited the ability to assess the effect of topical oxygen of wounds of other aetiologies.

## Conclusions

Topical oxygen was found to be an effective adjunctive therapy for chronic venous leg ulcers in a large study of 200 participants. Treatment time >25 days was found to be significantly associated with both significant reduction in wound area and wound healing outcomes. This study adds to a growing body of evidence confirming that topical oxygen therapies are effective in chronic wounds and may be particularly effective in the treatment of chronic non-healing DFUs, pressure ulcers and venous ulcers.

WINT

## References

- Copeland K, Purvis AR (2017) A retrospective chart review of chronic wound patients treated with topical oxygen therapy. *Adv Wound Care (New Rochelle)* 6(5): 143–52
- Falanga V, Moosa HH, Nemeth AJ et al (1987) Dermal pericapillary fibrin in venous disease and venous ulceration. *Arch Dermatol* 123(5): 620–3
- Frykberg RG, Franks PJ, Edmonds M et al (2020) A multinational, multicenter, randomized, double-blinded, placebo-controlled trial to evaluate the efficacy of cyclical topical wound oxygen (TWO2) therapy in the treatment of chronic diabetic foot ulcers: the tW02 study. *Diabetes Care* 43(3): 616–24
- Frykberg RG, Banks J (2015) Challenges in the treatment of chronic wounds. *Adv Wound Care (New Rochelle)* 4(9): 560–82
- Gordillo GM, Sen CK (2003) Revisiting the essential role of oxygen in wound healing. *Am J Surg* 186(3): 259–63

- Guest JF, Ayoub N, McIlwraith T et al (2015) Health economic burden that wounds impose on the National Health Service in the UK. *BMJ Open* 5(12): e009283
- Kalliainen LK, Gordillo GM, Schlanger R, Sen CK (2003) Topical oxygen as an adjunct to wound healing: a clinical case series. *Pathophysiology* 9(2): 81–7
- Kaufman H, Gurevich M, Tamir E et al (2018) Topical oxygen therapy stimulates healing in difficult, chronic wounds: a tertiary centre experience. *J Wound Care* 27(7): 426–33
- Kirsner RS, Vivas AC (2015) Lower-extremity ulcers: diagnosis and management. *Br J Dermatol* 173(2): 379–90
- Kirsner RS, Delhougne G, Searle RJ (2020) A cost-effectiveness analysis comparing single-use and traditional negative pressure wound therapy to treat chronic venous and diabetic foot ulcers. *Wound Manag Prev* 66(3): 30–6
- Niederauer MQ, Michalek JE, Liu Q et al (2018) Continuous diffusion of oxygen improves diabetic foot ulcer healing when compared with a placebo control: a randomised, double-blind, multicentre study. *J Wound Care* 27(Sup9): S30–S45
- Nussbaum SR, Carter MJ, Fife CE et al (2018) An economic evaluation of the impact, cost, and Medicare Policy implications of chronic nonhealing wounds. *Value Health* 21(1): 27–32
- Oliveira A, Simoes S, Ascenso A, Reis CP (2020) Therapeutic advances in wound healing. *J Dermatolog Treat* 1–21
- Rogers LC AD, Capotorto J, Fife CE et al (2020) Wound center without walls: the new model of providing care during the COVID-19 pandemic. *Wounds* 32(7): 178–85
- Tawfik W, Sultan S (2009) Does topical wound oxygen (TWO2) offer an improved outcome over conventional compression dressings (CCD) in the management of refractory venous ulcers (RVU)? A parallel observational comparative study. *Eur J Vasc Endovasc Surg* 38(1): 125–32
- Tawfik WA, Sultan S (2013) Technical and clinical outcome of topical wound oxygen in comparison to conventional compression dressings in the management of refractory nonhealing venous ulcers. *Vasc Endovascular Surg* 47(1): 30–7
- Vas PR, Papanas N (2019) Editorial and mini-review: topical oxygen therapy for diabetic foot ulcerations - avenue towards new hope? *Rev Diabet Stud* 15: 71–3
- Yu J, Lu S, McLaren AM et al (2016) Topical oxygen therapy results in complete wound healing in diabetic foot ulcers. *Wound Repair Regen* 24(6):1066–72

## Declaration

This study was supported through an unrestricted research grant