

Moving the chronic wound along the healing trajectory



Author:
Emilio Galea

Chronic wounds are an ever-growing challenge for clinicians and represent a huge burden on healthcare resources (Harding, 2002). They have been referred to as a silent epidemic that is affecting a large number of people in the world population (Gottrup, 2004). However, due to a better understanding of what makes a wound chronic, several new treatments that offer better outcomes for the patient and a broader choice for the clinician have been developed (Harding, 2002). A sterile, non-adherent, slough-trapping, poly-absorbent fibre dressing with the technologie lipido-colloïde (TLC) healing matrix to promote wound healing and enable pain-free dressing changes, which can be used for gentle desloughing, has been developed by Urgo. The slough-trapping fibres (poly-absorbent) have been shown to bind and trap the slough within the dressing, providing safe and effective desloughing (Kelly et al, 2013), while the silver lipido-colloid matrix in the antimicrobial version, has been established in its efficacy in the management of chronic wounds presenting with a risk of infection as demonstrated through previous randomised controlled trials (Harding et al, 2012; Lazareth et al, 2012).

In the author's previous article 'A Breakthrough in the Management of Neuro-Ischaemic Diabetic Foot Ulcers' (Galea, 2018), the emphasis was placed on the detrimental effect of elevated levels of matrix metalloproteinases (MMPs) in chronic wounds. The result of altered activities of proteases and their inhibitors lead to an altered healing process and the balance in regulation between the two appears to be disrupted in chronic wounds (Enoch and Price, 2004). However, other attributes are present that may lead to a wound being stuck in the inflammatory phase (Velnar et al, 2009).

Slough

A common presentation in chronic wounds is the presence of a viscous adherent layer of debris (Young, 2014). In acute wounds, slough is the product of components of phagocytosis and occurs as a consequence of the inflammatory phase (Hart, 2002; Attinger et al, 2006). Once this process is complete, the cells go through apoptosis and are seen on the wound surface as slough (Velnar et al 2009).

The moist, devitalised tissue present in chronic wounds is mainly composed of leukocytes, pathogenic microorganisms (such as bacteria), tissue debris, dead tissue, a mixture of serum proteins (e.g. fibrin, proteinaceous material albumin, immunoglobulins, deoxyribonucleo-protein) and denatured extracellular matrix proteins, serous exudate and pus (dead white blood cells, e.g. neutrophils) (Walcott et al, 2010; Brown, 2013; Percival and Sulaiman, 2015). This material provides the ideal environment for bacteria to multiply and can prolong the inflammatory phase (Dowsett and Ayello, 2004).

The detrimental contribution of slough to the wound comprises the prevention of normal wound healing, mimicking and/or hiding infection, attracting microorganisms to the site, increasing risk of infection, containing biofilm, preventing swabbing for microbiological analyses, increasing odour and exudate, and preventing practitioners from assessing the extent and size of the wound (Percival and Sulaiman, 2015). Slough also impedes granulation tissue formation and, ultimately, epithelialisation (Liu et al, 2017).

The solution for slough

Debridement has been defined as “the process in which all materials incompatible with healing are removed from a wound” (Cornell et al, 2010). However, Strohal et al (2013) went further into the definition and explain it as “the act of removing necrotic material, eschar, devitalised tissue, serocrusts, infected tissue, hyperkeratosis, slough, pus, haematomas, foreign bodies, debris, bone fragments or any other type of bioburden from a wound with the objective to promote wound healing”.

Interestingly, Strohal et al (2013) identified that delay in managing slough might be a primary cause of delayed wound healing. Key opinion leaders deliberated the possibility of including a new term — ‘desloughing’ — to be used with debriding, as this would encourage clinicians to focus more on the prompt removal of slough. Desloughing has been defined as “the process that is used to separate slough from the underlying granulation tissue of the wound, a term associated with the removal of slough using wound dressings” (Percival and Suleman, 2015). Desloughing may be interpreted in two different avenues; that is, either natural or assisted (Milne, 2015). Autolysis may be achieved by the action of enzymes, which are produced by white blood cells (Milne, 2015), however, when the natural autolytic process is overwhelmed by the amount of tissue damage, resulting in chronicity, assisted desloughing would be indicated (Grothier, 2015; Percival and Suleman, 2015).

Surgical excision has been defined as the most direct method of debridement and desloughing, however, alternative methods, such as mechanic, enzymatic, autolytic or biologic, may be used in patients who do not have access to a licensed clinician or other reasons, e.g. pain (Stead 2004).

An available solution for desloughing

Recently, an absorbent cohesive dressing (UrgoClean®, Urgo Medical) has been specifically developed for the desloughing phase of the healing process (Meaume et al, 2014). UrgoClean is suitable for sloughy and exuding wounds, and consists of a pad or ribbon of polyacrylate non-woven fibres, with an acrylic core that absorbs exudate and entraps slough (Eloy et al, 2010). The pad is coated with a soft-adherent lipido-colloid layer (TLC Technology) that promotes healing and enables atraumatic removal (Trudigan et al, 2014).

An initial non-comparative exploratory clinical study in the local management of chronic wounds from the desloughing phase, including 50 patients with leg or pressure ulcers, provided promising

results that appeared to be similar to those reported in the literature for the reference dressings in this field (Meaume et al, 2012). However, the non-controlled nature of this pilot study led to design an additional clinical study aimed at objectively determining the performance of this dressing. This randomised, controlled, open-labelled clinical study, involved 159 patients (UrgoClean [$n=83$]; Hydrofiber® (Aquacel) [$n=76$]), and was conducted in 37 centres in Europe, with a duration of 6 weeks (follow-up up to 24 weeks) (Meaume et al, 2014).

After 6 weeks of treatment, the relative reduction in surface area was -34.1% for the UrgoClean group and -34.4% for the Hydrofiber group after 6 weeks of treatment with the values of the one-sided 95% confidence interval (CI) and the level margin of 12%, the non-inferiority hypothesis is accepted for the UrgoClean dressing ($P=0.01$ and $P<0.025$ for the per-protocol (PP) and Intention-to-treat (ITT) analysis populations, respectively). The non-inferiority of UrgoClean compared to the reference dressing in terms of reduction in wound surface area was demonstrated with a very high level of confidence. However, a relative reduction in slough of -65.3% and -42.6%, respectively, in the UrgoClean and Hydrofiber groups was observed, demonstrating a difference in means of 22.69, which is significant ($P=0.013$), in favour of UrgoClean. After 6 weeks of treatment, the percentage of desloughed wounds in the UrgoClean group was significantly greater than the percentage of desloughed wounds in the Hydrofiber group ($P=0.033$). This significant difference in favour of the UrgoClean group for the percentage of desloughed wounds is consistent with the significant difference observed for the relative reduction in slough after 6 weeks of treatment.

This randomised controlled trial (RCT) confirmed that UrgoClean showed similar efficacy and safety compared to Hydrofiber, but presented better autolytic properties in the management of ulcers at the sloughy stage. UrgoClean, therefore, represents a promising therapeutic option within the current range of autolytic dressings available.

Although the hydrofiber dressings control moisture levels on wounds that might aid in the autolytic debridement, these types of dressings are classified and indicated for moisture and exudate control, rather than autolytic debridement agents (Gibbs, 2010). On the contrary, UrgoClean is a desloughing dressing with additional exudate management capabilities (Kelly et al, 2013).

Biofilm

Biofilms have been defined as complex microbial

communities containing bacteria and fungi and it has been suggested that almost all chronic wounds have biofilm communities on at least part of the wound bed (Philips et al, 2012). In chronic wounds, biofilm is composed of multispecies (microorganisms) communities held together and attached to the wound bed (Bjarnsholt et al, 2008). Biofilms increase the microorganism tolerance to the immune system, antimicrobials and environmental stresses, as the extracellular polymeric substance (EPS) that encapsulates the bacteria prevents large molecules and inflammatory cells from penetrating deeply into the biofilm matrix (Guiot et al, 2002).

Mature biofilm may also act as a diffusion barrier even to small molecules like antimicrobial agents (Guiot et al, 2002). A chronic inflammatory response is initiated in an attempt for the wound to rid itself from the biofilm — abundant neutrophils and macrophages surround biofilms and secrete high levels of reactive oxygen species and MMPs that impair healing (Philips et al, 2012).

The solution for effective wound biofilm management needs to include mechanical, enzymatic or physical degradation of the biofilm matrix and the disruption of biofilm (Alavi et al, 2012; Walcott, 2015) along with antimicrobial therapy (Snyder et al, 2017).

An effective way how to disrupt chronic wound biofilm

UrgoClean Ag® is similar to the previously discussed dressing with the inclusion of silver sulfate in the TLC matrix; a silver complex that, in contact with the wound exudate, breaks down and releases the Ag⁺ ion — the controlled supply of Ag⁺ at the surface into the lipido-colloid gel, guarantees a constant antibacterial activity strictly in contact with the wound (Adolphus et al, 2015). Studies on the effects of silver dressings on experimental models of biofilms suggested that silver could reduce bacterial adhesion and destabilise the biofilm matrix (International Consensus, 2012). The poly-absorbent fibers proceed to the mechanical de-structuration of the bacterial biofilm EPS by absorbing water from the biofilm, which disrupts and weakens it; Ag⁺ ions provide the antimicrobial action within the biofilm and, finally, the fibres provide a mechanical action to drain and retain wound residues (bacteria, exudate, sloughy tissue etc.) within the dressing (Bisson, 2013).

The anti-biofilm activity of UrgoClean Ag against *Staphylococcus aureus* (MRSA) and *Pseudomonas aeruginosa* was determined using *in vitro* models.

In the first study (Desroche et al, 2016), the application of the silver polyabsorbent dressing resulted in a significant decrease of the biofilm population by a log reduction of 4.6, after 24 hours of exposure, which was maintained for 7 days, with reduction values up to 4 log (reduction of biofilm superior to 99.99%). The second study (Desroche et al, 2017) evaluated the *in vitro* anti-biofilm activity of UrgoClean Ag compared to a carboxymethylcellulose (CMC) dressing, which combines ionic silver, a metal chelating agent and a surfactant (Hydrofiber Ag + Extra).

In this *in vitro* model, after 24 hours of exposure, UrgoClean Ag demonstrated higher anti-biofilm activities than the CMC dressing. In these conditions, the anti-biofilm efficacy of the poly-absorbent silver dressing was shown to be 50 times stronger on MRSA biofilm and 100 times stronger on *P. aeruginosa* biofilm than the CMC dressing. The combined action of polyacrylate fibres (mechanical action) and TLC-Ag matrix (bactericidal activity) of this poly-absorbent silver dressing has been shown to enable a more rapid disruption of *in vitro* biofilms.

Furthermore, a prospective, multicentre, non-comparative clinical trial was conducted involving patients that were considered at high-risk of infection (Dalac et al, 2016). They were treated for a maximum period of 4 weeks (UrgoClean Ag), and followed by the physician on a weekly basis. The primary efficacy criterion of the trial was the relative wound surface area reduction at the end of the 4 weeks of treatment. Wound surface area, mostly covered by sloughy tissue, was reduced by 32.5%. A total of 54.1% were considered debrided (as defined by >30% of sloughy tissue covering the wound bed). The relative reduction of sloughy tissue was of 62.5% (median value) versus baseline with only 20% of the wound surface area still covered by sloughy tissue (median value) versus 70% at baseline. The promotion of the wound healing process was shown through the wound surface area reduction, the rapid decrease of the inflammatory signs and of the sloughy tissue, a good safety profile and a high acceptability. The authors concluded that these clinical data support that the UrgoClean Ag is a credible therapeutic alternative for the management of wounds at risk of infection with inflammatory signs suggesting heavy bacterial load (Snyder et al, 2017).

Visual evidence

Case 1

A 57-year-old female in Thailand with type 2 diabetes mellitus, hypertension, ischaemic heart disease, triple vessel disease and peripheral vascular disease presented on May 15, 2017 with

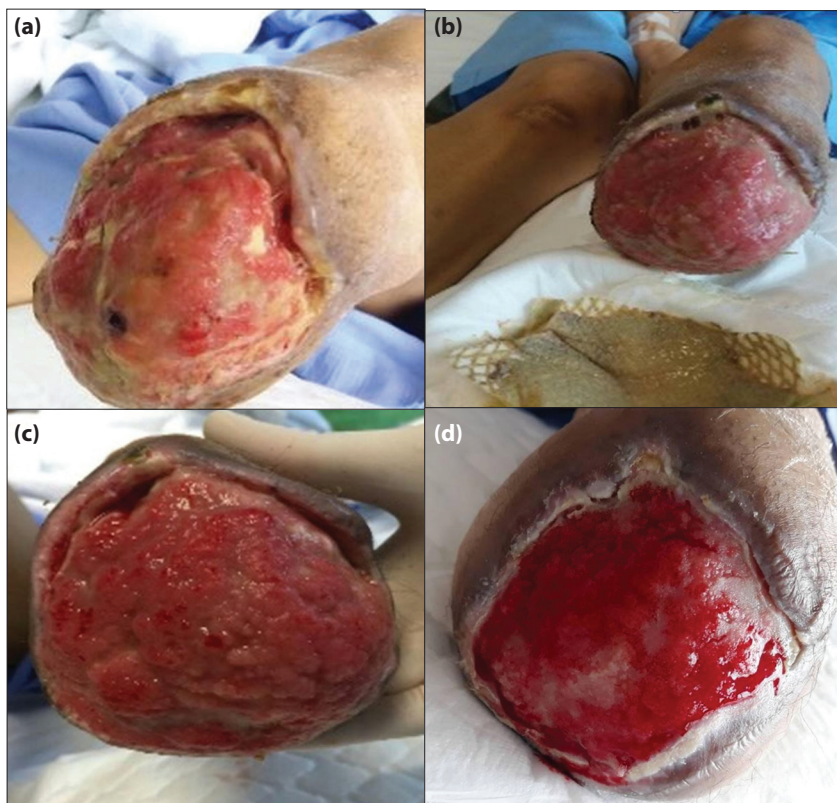


Figure 1. (a) Day one (b) Day 2 (c) Day 10 (d) Day 27.

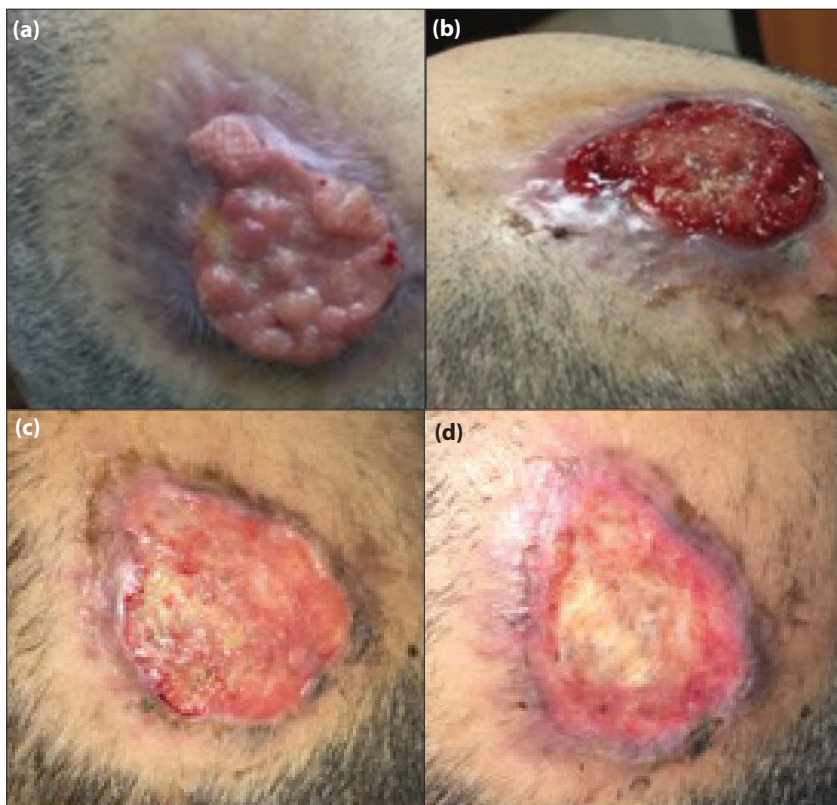


Figure 2. (a) On presentation, 18/3/2018 (b) Second day after first dressing change, 20/3/2018 (c) Wound on 29/3/2018 (d) Wound on 08/04/2018.

a wet gangrene of the third and fourth toe of the left lower limb, which resulted in a below-knee amputation on the June 3, 2017. A balloon angioplasty was performed post amputation. The patient was re-admitted with an infected stump on August 9, 2017 (*Pseudomonas* identified). Dressing changes were carried out using UrgoClean Ag (daily dressing for first week, alternate days thereafter). Slough and infection were eradicated within 10 days — grafting was not performed at this stage due to patient comorbidities [Figure 1 (a-d)]. Case came courtesy of Dr Chonlatorn, King Chulalongkorn Memorial Hospital (Bangkok, Thailand).

Case 2

A 67-year-old male from Kuwait, who works as a chef, presented with an infected pressure injury in March 2018. He had a history of ischaemic heart disease, hypertension and diabetes. The patient had been previously admitted for a coronary artery bypass graft, but ended up staying as an inpatient for 3 months due to several complications. He was discharged home with a hospital acquired pressure injury on the scalp. The patient was referred to plastic surgery outpatients department on March 18, 2018 (after 6 months) with unhealthy, infected granulating tissue [Figure 2a-d]. Surgical/sharp debridement carried a risk of uncontrolled bleeding as patient was on anticoagulation medication. Therefore, UrgoClean Ag was opted for use as a mechanical deslougher. The dressing was changed every 2 days. Within 17 days, the wound reduced in size by 50%, with no pain or exudate and had visual evidence of epithelialisation. Case came courtesy of Dr Muneera Ben Nakhi and Dr Hazem Eltayeb, Plastic Surgery Unit, Adan Hospital, Kuwait.

Conclusion

It is crucial that healthcare professionals are able to identify the problems associated with slough on the wound bed, as well as the clinical signs and symptoms of wound infection, as well as having the knowledge to manage them in a timely and appropriate manner. This may impact the patient's quality of life by reducing pain, exudate and anxiety, prevent further wound complications and move the wound towards the normal healing trajectory.

Previously published studies that were discussed in this article have proven the efficacy of a poly-absorbent fibre dressing with and without silver. Moreover, the two clinical cases discussed demonstrated that the dressing can be effectively used when other methods of desloughing, such as surgical and/or sharp debridement, is not

possible and confirmed continuing reduction in clinical signs of infection and the percentage of slough present, resulting in positive outcomes for healthcare professionals and the patient. **WME**

References

- Adolphus K, Toner L, Stephen-Haynes J, Deeth M (2015) *An Open-label, Non-comparative, Multicentre Evaluation of the Performance of a Hydro-Desloughing*. Poster presentation: Wounds UK Annual Conference 2016, November 14–16, 2016, Harrogate, UK. Available from: <https://bit.ly/2tT18va> (accessed: 04.07.2018)
- Alavi MR, Stojadinovic A, Izadjoor MJ (2012) An overview of biofilm and its detection in clinical samples. *J Wound Care* 21(8): 376–83
- Attinger CE, Janis JE, Steinberg J et al (2006) Clinical approach to wounds: débridement and wound bed preparation including the use of dressings and wound healing adjuvants. *Plast Reconstr Surg* 117(7 Suppl): 72S–109S
- Bisson J (2013) Effects of TLC-Ag dressings on skin inflammation. *J Dermatol* 40(6): 463–70
- Brown A (2013) The role of debridement in the healing process. *Nurs Times* 109(40): 16–9
- Bjarnsholt T, Kirketerp-Møller K, Jensen PØ et al (2008) Why chronic wounds will not heal: a novel hypothesis. *Wound Repair Regen* 16(1): 2–10
- Cornell RS, Meyr AJ, Steinberg JS, Attinger CE (2010) Debridement of the noninfected wound. *J Vasc Surg* 52(3, Suppl): 31S–6S
- Dalac S, Sigal L, Addala A et al (2016) Clinical evaluation of a dressing with poly absorbent fibres and a silver matrix for managing chronic wounds at risk of infection: a non comparative trial. *J Wound Care* 25(9): 531–8
- Desroche N, Dropet C, Janod P, Guzzo J (2016) Antibacterial properties and reduction of MRSA biofilm with a dressing combining polyabsorbent fibres and a silver matrix. *J Wound Care* 25(10): 577–84
- Desroche N, Dropet C, Janod P, Guzzo J (2017) *Comparison of In Vitro Biofilm Activities of a New Poly-Absorbent Dressing with Silver Matrix and Silver Containing CMC Dressing*. Poster presentation at the European Wound Management Association, The Netherlands, May 3–5 2017.
- Dowsett C, Ayello E (2004) TIME principles of chronic wound bed preparation and treatment. *Br J Nurs* 13(15 Suppl): S16–23
- Eloy R, Clermont G, Nicot D, Morel N (2010) *Mechanism of Action of UrgoClean*. Poster presentation. Available at: <https://bit.ly/2tT18va> (accessed 05.07.2018)
- Enoch S, Price P (2004) Cellular, molecular and biochemical differences in the pathophysiology of healing between acute wounds, chronic wounds and wounds in the aged. *World Wide Wounds* 13: 1–17
- Galea E (2018) A breakthrough in the management of neuro-ischaemic diabetic foot ulcers. *Diabetic Foot Journal Middle East* 4(1): 46–9
- Grothier L (2015) Improving clinical outcomes and patient experience through the use of desloughing. *Br J Comm Nurs* 29(9 Suppl): S25–31
- Guiot E, Georges P, Brun A et al (2002) Heterogeneity of diffusion inside microbial biofilms determined by fluorescence correlation spectroscopy under two-photon excitation. *Photochem Photobiol* 75(6): 570–8
- Gottrup F (2004) A specialized wound-healing center concept: importance of a multidisciplinary department structure and surgical treatment facilities in the treatment of chronic wounds. *Am J Surg* 187(5): S38–43
- Harding K (2002) Healing chronic wounds. *BMJ* 324(7330): 160
- Harding K, Gottrup F, Jawien A et al (2012) A prospective, multi-centre, randomised, open label, parallel, comparative study to evaluate effects of AQUACEL® Ag and Urgotul® Silver dressing on healing of chronic venous leg ulcers. *Int Wound J* 9(3): 285–94
- Hart J (2002) Inflammation. 1: Its role in the healing of acute wounds. *J Wound Care* 11(6): 205–9
- Hess CT (2011) Checklist for factors affecting wound healing. *Adv Skin Wound Care* 24(4): 192
- International consensus (2012) *Appropriate Use of Silver Dressings in Wounds. An Expert Working Group Consensus*. Wounds International, London. Available at: <https://bit.ly/1KRwqol> (accessed 05.07.2018)
- Iuonut AMM, Dindelegan GC, Ciuce C (2011) Proteases as biomarkers in wound healing. *TMJ* 61: 1–2
- Kelly J, McGrath A, Wildman S (2013) UrgoClean – A new dressing for desloughing exuding wounds. *Br J Community Nurs* Suppl: S44–9
- Lazareth I, Meaume S, Sigal-Grinberg ML et al (2012) Efficacy of a silver lipidocolloid dressing on heavily colonised wounds: a republished RCT. *J Wound Care* 21(2): 96–102
- Milne J (2015) Wound-bed preparation: the importance of rapid and effective desloughing to promote healing. *Br J Nurs* 24(Suppl 20): S52–S8
- Meaume S, Perez J, Rethore V et al (2012) Management of chronic wounds with an innovative absorbent wound dressing. *J Wound Care* 21(7): 31S–22
- Meaume S, Dissemmond J, Addala A et al (2014) Evaluation of two fibrous wound dressings for the management of leg ulcers: Results of a European randomised controlled trial (EARTH RCT). *Journal of wound care*, 23(3), pp.105–116.
- Natarajan S, Williamson D, Stiltz AJ, Harding K (2000) Advances in wound care and healing technology. *Am J Clin Dermatol* 1(5): 269–75
- Perceval SL, Suleman L (2015) Slough and biofilm: removal of barriers to wound healing by desloughing. *J Wound Care* 24(11): 498–510
- Phillips PL, Wolcott RD, Fletcher J, Schultz GS (2012) *Biofilms Made Easy*. *Wounds International* 1(3): 1–6 Available at: <https://bit.ly/1CJUTUX> (accessed 05.07.2018)
- Sinno H, Prakash S (2013) Complements and the wound healing cascade: an updated review. *Plast Surg Int* 2013: 146764
- Steed DL (2004) Debridement. *Am J Surg* 187(5A): S71–S4
- Strohal R, Apelqvist J, Dissemmond J et al (2013) EWMA document: debridement: an updated overview and clarification of the principle role of debridement. *J Wound Care* 22(1): 5
- Trudigan J, Law P, Tarbox B (2014) Evaluation of UrgoClean® for the treatment of sloughy, exuding wounds. *Wounds UK* 10(1): 56–62
- Velnar T, Bailey T, Smrkolj V (2009) The wound healing process: an overview of the cellular and molecular mechanisms. *J Int Med Res* 37(5): 1528–42
- Wolcott RD, Rhoads DD, Bennett ME et al (2010) Chronic wounds and the medical biofilm paradigm. *J Wound Care* 19(2): 45–53
- Wolcott R (2015) Disrupting the biofilm matrix improves wound healing outcomes. *J Wound Care* 24(8): 366–71
- Young S (2014) Management of slough in diabetic foot wounds. *The Diabetic Foot Journal* 17(1): 29–33