

Outpatient management of secondary upper-limb lymphoedema with an adjustable compression sleeve: a case study

Shane Gallagher, Lynn O' Connor, Michael Martin, David Roberts and Kenneth Monaghan

Key words

Adjustable compression garment, case report, manual lymphatic drainage, secondary lymphoedema

Shane Gallagher is a Physiotherapist and MSc student, Clinical Health and Nutrition Centre (CHANCE), Neuroplasticity Research Group, School of Science, Institute of Technology (IT) Sligo, Ireland; , Physiotherapy Department, Sligo University Hospital, Sligo, Ireland; Lynn O' Connor, Senior Physiotherapist in Physiotherapy Department, Sligo University Hospital, Sligo, Ireland Michael Martin is Oncology Consultant, Sligo University Hospital, Sligo, Ireland; David Roberts, Senior Lecturer, Neuroplasticity Research Group, Clinical Health and Nutrition Centre (CHANCE), School of Science, Institute of Technology (IT) Sligo, Ireland; Kenneth Monaghan, Senior Lecturer, Neuroplasticity Research Group, Clinical Health and Nutrition Centre (CHANCE), School of Science, Institute of Technology (IT) Sligo, Ireland

Declaration of interest: There are no conflicts of interest in this study. The Juzo Adjustable Compression System Light was provided free of charge from Juzo via Serra Nova Ltd, Ireland, for this case study, but no other funding or payment was received.

Abstract

Introduction: Compression bandaging is a key component of complex decongestive therapy (CDT) for lymphoedema (Sezgin Ozcan et al, 2018) and there is increasing interest in using adjustable compression wraps for lymphoedema treatment (Thomas, 2017). **Objective:** To assess the feasibility of using an adjustable compression wrap in the intensive phase of secondary lymphoedema treatment. **Methods:** A 75-year-old patient with a history of breast cancer surgery underwent CDT with the compression bandaging replaced by a Juzo Adjustable Compression System. **Results:** There were no adverse reactions during treatment, skin condition improved during treatment and the patient could apply the garment independently. Small reductions in volume occurred during the intensive phase and were maintained at 3 months. **Conclusion:** This case study shows that the Juzo Adjustable Compression System Light is a feasible treatment option for the intensive phase of CDT. Further research is required.

Breast cancer-related lymphoedema (BCRL) is one of the most commonly reported complications of treatment (17% incidence — DiSipio et al, 2013) for the estimated 2 million breast cancer cases worldwide annually (Soran et al, 2006; Bray et al, 2018; De Vrieze et al, 2020). Lymphoedema increases the risk of cellulitis and the frequency of hospitalisation (Lymphoedema Framework, 2006). It is,

therefore, important to have safe, effective and evidence-based treatment options that alleviate symptoms, prevent progression, and reduce both the risk of skin infection and the frequency of hospitalisation (Finnane et al, 2015; Gatt et al, 2017).

Compression bandaging is a key component of complex decongestive therapy (CDT; Sezgin Ozcan et al, 2018), which is considered the standard treatment technique to control and even reduce the

lymphoedema volume and symptoms (Ezzo et al, 2015). A review of CDT (Mosti and Cavezzi, 2019) describes how numerous papers and consensus documents suggest applying multilayer bandaging (MLB) at a relatively high pressure in the initial treatment phase. They also describe how MLB is difficult to apply, with healthcare professionals rarely achieving the desired pressure. Bandage pressure loss occurs after a relatively short time, requiring more

Case report

frequent readjustment/re-application to stay within the desired ranges (Mosti and Cavezzi, 2019).

As a result of the disadvantages with MLB, there is currently an increasing interest in adjustable compression wraps (ACW; Table 1) in lymphoedema (Thomas, 2017). It is now known that a lower pressure is more effective and better tolerated than a stronger pressure to treat arm lymphoedema; this is true both after 2 hours and after 24 hours (Damstra and Partsch, 2009).

Campanholi et al (2017) found that ACW applied at a lower pressure than MLB was effective in the reduction of limb volume in nine patients with BCRL. The patients reported that the device was more practical and convenient and a better option than MLB. Patients can self-adjust the ACW when it loses pressure, leading to better pressure maintenance over time and increased volume reduction in lower-limb lymphoedema (Mosti and Cavezzi, 2019). The ability for patients to remove/replace/adjust the ACW themselves increases its acceptability and improves patient compliance (Mosti and Cavezzi, 2019).

ACWs reduce treatment time as it is much faster to apply than conventional MLB (Campanholi et al, 2017). Thomas (2017) described how the most important factor concerning potential cost saving is that it can be applied without the assistance of medical staff. In these COVID times, some patients are reluctant to attend clinic appointments, so less frequent appointments, or self-treatment in the home setting, may be potential benefits of using an ACW. In their review of compression therapy in lymphoedema, Mosti and Cavezzi (2019) suggested that “in order to get a higher degree of evidence, more randomised controlled trials (RCTs) on lymphedema treatment by means of different compression medical devices are to be performed”.

The Juzo Adjustable Compression System Light (JACSL) and Hand Wrap (Juzo, 2020; Figure 1) was chosen as it has an incorporated lining (fixing aid), which the company state makes the JACSL easy to use and allows for simple and quick application. This could, therefore, aid in patients’ self-management. The manufacturers claim that therapeutic compression pressures of up to 40 mmHg are possible and, therefore, effective therapeutic compression pressures

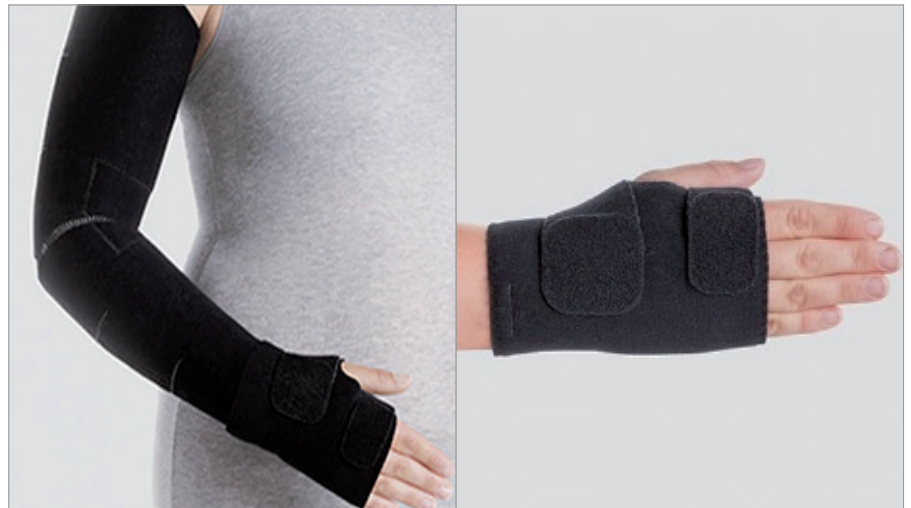

Figure 1. Juzo ACS Light Arm Wrap & Juzo ACS Light Hand Wrap (Juzo, 2021).

should be achievable as a pressure in the range of 20–30 mmHg is now found to be effective in the treatment of upper limb lymphoedema (Mosti and Cavezzi, 2019).

Patient history and presentation

The patient is a 75-year-old female who had a full left mastectomy with axillary clearance for an invasive ductal carcinoma in 2004. This was followed by chemotherapy (Taxol) and radiotherapy to her chest wall and supraclavicular fossa and 5 years of Arimidex hormonal therapy. Lymphoedema started 30 months after her surgery, with no known precipitation factor. She has been attending the Sligo University Hospital (County Sligo, Ireland) Physiotherapy department for CDT every 6 months since May 2008. Here, Coban compression bandaging has replaced MLB as the compression therapy of choice since

2017. She also reported a past medical history of atrial fibrillation 2018, (on Apixaban) hypertension, vertigo, knee osteoarthritis and scoliosis.

Aim

The aim of this case study is to investigate if this ACW can provide a feasible, effective and safe treatment option in both the intensive treatment phase and the maintenance phase of CDT in an Irish healthcare setting.

Methods

Initial Assessment, July 2020

Skin condition

Visual examination of the upper limb and palpation of the skin and tissues, as well as questioning of the patient determined the patient had moderate stage II Lymphoedema in the left upper-limb

Table 1. Examples of adjustable compression wraps.

- Juzo Compression wrap (Juzo, 2021)
- Compreflex (Sigvaris, 2021)
- JOBST FarrowWrap (JOBST, 2021)
- Circaid Juxtafit (Medi, 2021)

Table 2. Timetable of appointments.

Appointment number/ date	Limb volume measurement (LVM) and/or treatment of manual lymphatic drainage (MLD) and adjustable compression wrap and instruction re self-care
1. 28/7/2020	LVM + Treatment of MLD and ACW
2. 31/7/2020	Treatment of MLD and ACW
3. 4/8/2020	Treatment of MLD and ACW
4. 7/8/2020	LVM + Treatment of MLD and ACW
5. 11/8/2020	Treatment of MLD and ACW
6. 14/8/2020	LVM

(Scale 0-III, Executive Committee, 2020), with increased lymphoedema evident in the forearm and a positive Stemmer's sign (Greene and Goss, 2018) in the left hand. An Excel-based software programme was used to calculate volume using circumferential measurements 4 centimetres apart, treating each segment as a truncated cone (Ng and Munnoch, 2010). A 12.8% difference between limbs was recorded, while there was a 19% difference between forearm volumes. The oedema in the forearm was soft and pitting, and there was moderate skin thickening over the wrist extensor muscles of the forearm. The patient had a body mass of 61.6 kg and height of 1.35m, classifying the patient as overweight with a body mass index of 26.7kg/m² (Normal/healthy weight 18.5–24.9 BMI; Cdc.gov, 2021).

Twelve arm circumference measurements were recorded using a tape measure, starting from the zero point at the posterior wrist crease and at 4-cm intervals up the arm. The patient sat with the arm straight and abducted 90° on a table. Measurements were taken on the first visit prior to treatment starting, prior to treatment four and at the final visit (visit 6).

Treatment protocol

Manual Lymphatic Drainage (MLD) was performed as per Dr Vodder protocol (Wittlinger, 2018) twice per week, lasting 30 minutes. The patient was then fitted with a Juzo Adjustable Compression System Light (JACSL), shown how to apply and instructed on how to tighten Velcro straps independently at home if the garment became loose. The patient was asked to wear the JACSL for three 24-hour periods/week during the maintenance phase.

The patient was instructed on both the self-lymphatic drainage (Figure 2) and strengthening exercises for her affected limb, which consisted of wrist and elbow flexion and extension and shoulder flexion and abduction with a 0.5kg weight. Each exercise was performed 20 times, two times daily. The patient was also given advice about aerobic exercise (30 minutes walking daily, 5 times weekly) and weight management following healthy eating guidelines on the Irish Health Service Executive (HSE) website (<https://www.hse.ie/healthyeating/>).

Results

There was no change to any medication throughout the course of treatments.

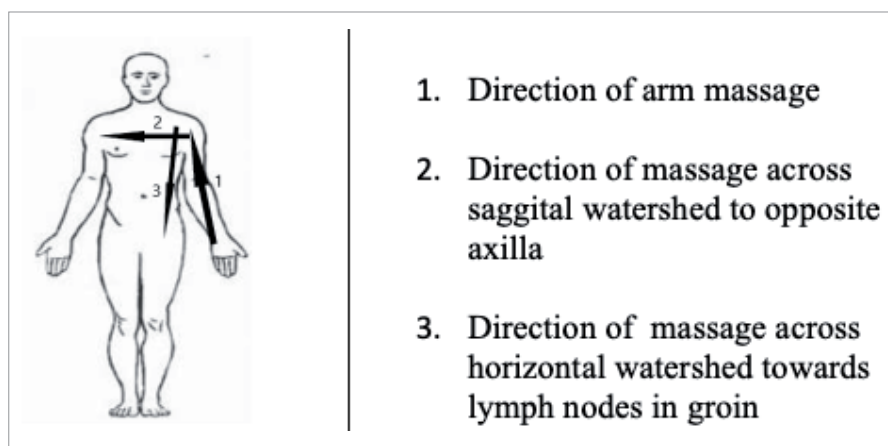


Figure 2. Direction of movement for the self-massage.

Table 3. Limb volume (mls) and percentage difference throughout treatment.

	UL volume (mls)		Forearm volume (mls)		Upper arm volume (mls)	
	Right	Left	Right	Left	Right	Left
Initial visit, day 1	2111	2382	807	967	1113	1181
Volume difference %	270 12.8%		160 19.8%		68 6.2%	
Pre-fourth treatment, day 10	2078	2379	801	930	1092	1223
Volume difference %	301 14.5%		129 16%		131 12%	
Last visit, day 18	2102	2334	788	902	1127	1210
Volume difference %	232 11%		114 14.5%		83 7.4%	
3 month follow-up	2041	2267	787	860	1070	1190
Volume difference %	226 11.1%		73 9.3%		120 11.2%	
7 month follow-up	1961	2320	760	856	1025	1234
Volume difference %	18.3%		12.7%		20.4%	

Table 4. Patient comments.

Symptoms	<p>“delighted with the progress in her forearm up to her elbow”</p> <p>“can feel her elbow and the bone down her forearm for the first time since the lymphoedema started in her forearm”</p> <p>“skin feels very good and very soft”</p> <p>“I don’t think it has ever felt as good since the lymphoedema started”</p> <p>“I feel that all of the hardness in my skin has resolved”</p>
Comfort	<p>“apart from when I was showering and moisturising I did not remove the sleeve over the past few days other as it felt so comfortable”</p> <p>“better than the previous compression bandaging”(multi-layer bandaging and cohesive bandaging)</p>
Ease of use	<p>“the fact that you can adjust it yourself is a huge help, and it is easy to take off and put back on, and allows for showering and moisturising”.</p>

Case report

Changes in limb volume are noted in Table 3.

The patient was confident to adjust the sleeve herself and did so on a more frequent basis as treatment progressed. She tightened it above the wrist only between the first and second visits as it had become slightly loose.

The patient adjusted the garment more frequently during the intensive phase, progressing from 1–2 adjustments between the second and third treatment visits, to 3 adjustments between subsequent visits. She removed the bandage for 1 hour one of the days between treatments to shower and moisturise her arm. The patient reported how the JACSL was beginning to soften her skin between treatments 2 and 3, where it had previously felt fibrotic (tough and thickened).

Overall, the patient felt the JACSL was a success due to the reduction in forearm volume, improvement in skin quality and reduction in subjective weight of the forearm. At the 6 months follow-up, the patient reported that the JACSL “has had a good effect on her forearm”, which according to the patient was where “most of the work was needed”.

Discussion

In terms of feasibility outcomes, the patient reported no issues of concern in relation to the wearing, fitting and treatment time for the JACSL and glove. The patient reported no adverse reaction to wearing the JACSL. She described the bandaging as very comfortable and had no issue with areas of skin redness or breakdown. The JACSL was easily removed and reapplied as needed by the patient for showering, moisturising, social events and photographs. In terms of treatment time, the JACSL could be applied by the therapist in under 3 minutes which, from practical experience, is much faster than both the multilayer bandaging and the cohesive bandaging (approximately 10–20 minutes). This extra time could be dedicated to either seeing more patients or providing a more thorough manual lymphatic drainage. The areas of fibrosis in her forearm resolved with the skin becoming soft and mobile during the intensive treatment phase; this continued to improve during the maintenance phase. Women with lymphoedema can find the multilayer bandaging to be tiring, time

consuming, heavy and bulky, resulting in a restricted life and loss of independence, and occasionally poor concordance with treatment (Morgan et al, 2011). The patient in this case study reported that the JACSL is much easier to apply than the patient self-wrapping with multilayer bandaging and resulted in increased compliance with self-treatment.

Although the feasibility outcomes are the most important in terms of how well tolerated the JACSL was for the patient, the effectiveness of the JACSL resulted in small reductions in upper-limb volume after MLD and JACSL maintained at 3 months, but increased slightly between the 3- and 7-month follow-up.

Most of the volume reduction occurred in the patients forearm volume, which was noticeable to the patient both in terms of appearance and in being able to palpate bony landmarks. This improvement was maintained over the next 3 months of self-management, then regressing slightly over the following 4 months. The upper arm volume increased slightly during the intensive phase of treatment and also through the 3- and 7-month follow up.

In future studies, pressure monitors under the sleeve providing real-time feedback to the patients could be of benefit to assist the patient in applying the sleeve at an appropriate level in the upper arm, and may help achieve the desired results. To the authors' knowledge, no studies so far have established the Minimal Clinical Important Difference for lymphoedema, a point echoed by Letellier et al (2014).

Should the JACSL system be found to be safe and effective in both the intensive phase and maintenance phase, it would provide significant cost savings in terms of staff time and also decrease the amount of waste material generated from other bandaging. It is also hoped that if successful this method of treatment would further empower patients to self-manage and take ownership of their condition, rather than being passive recipients of care. It would allow patients who were reluctant to attend treatment as frequently as before (secondary to COVID) to continue with treatment at home, and may enable treatments to be performed virtually, whereby patients are directed through their self-massage, skin care, strengthening exercises and application of their ACW if necessary.

Methodology issues

Feasibility outcomes including ease of application, comfort, and skin integrity were appropriate, ensuring patient safety and satisfaction with fitting and wearing the garment and can be recommended for future studies.

The current standard treatment in the Sligo University Hospital lymphoedema clinic, which has limited resources, comprises of two 1-hour appointments weekly has worked well for patients as they find the time and travel commitments manageable. JACSL compression would allow the therapists and patients to continue with the same scheduling. Circumferential measurements using the truncated cone calculation method is an accurate and reliable method of capturing volumetry (Ng and Munnoch, 2010).

Pressure monitors under the ACW providing feedback could allow for more uniform/efficient delivery of pressure throughout the sleeve.

The patient's follow-up visit, which would normally happen 6 months post-intensive phase of treatment, had to be moved back 1 month due to outpatient appointments being stopped due to the COVID-19 pandemic. Photographs would have captured changes in the patients arm and skin.

Conclusion

It has been demonstrated in this case study that the JACSL is both feasible and effective in the intensive phase of treatment. The patient reported no adverse effects and reported increased compliance with the JACSL. It decreased the lymphoedema volume in the forearm during the intensive phase of treatment, which was maintained at the 3-month follow-up and also reduced areas of fibrosis.

The overall recommendation is that the JACSL has the potential to form part of the intensive treatment protocol for patients with BCRL due to it decreasing forearm volume, ability to improve the softness of the patients' skin and patient satisfaction with treatment outcomes. There is a need for a pilot RCT in the future to further explore the possibility of using an ACW in the intensive phase of lymphoedema management.

References

Bray F, Ferlay J, Soerjomataram I et al (2018) Global cancer statistics 2018: GLOBOCAN estimates of incidence and mortality worldwide for 36 cancers in 185 countries. *CA Cancer J Clin* 68(6): 394–424

- Campanholi LL, Lopes GC, Mansani FP et al (2017) The validity of an adjustable compression Velcro wrap for the treatment of patients with upper limb lymphedema secondary to breast cancer: a pilot study. *Mastology* 27(3): 206–12
- Damstra RJ, Partsch H (2009) Compression therapy in breast cancer-related lymphedema: A randomized, controlled comparative study of relation between volume and interface pressure changes. *J Vasc Surg* 49(5): 1256–63
- De Vrieze T, Nevelsteen I, Thomis S et al (2020) What are the economic burden and costs associated with the treatment of breast cancer-related lymphoedema? A systematic review. *Support Care Cancer* 28(2): 439–49
- DiSipio T, Rye S, Newman B, Hayes S (2013) Incidence of unilateral arm lymphoedema after breast cancer: a systematic review and meta-analysis. *Lancet Oncol* 14(6): 500–15
- Executive Committee of the International Society of Lymphology (2020) The diagnosis and treatment of peripheral lymphedema: Consensus Document of the International Society of Lymphology. *Lymphology* 53(1): 3–19
- Ezzo J, Manheimer E, McNeely ML (2015) Manual lymphatic drainage for lymphedema following breast cancer treatment. *Cochrane Database Syst Rev* (5): CD003475
- Finnane A, Janda M, Hayes SC (2015) Review of the evidence of lymphedema treatment effect. *Am J Phys Med Rehabil* 94(6): 483–98
- Gatt M, Willis S, Leuschner S (2017) A meta-analysis of the effectiveness and safety of kinesiology taping in the management of cancer-related lymphoedema. *Eur J Cancer Care (Engl)* 26(5). doi: 10.1111/ecc.12510
- Greene AK, Goss JA (2018) Diagnosis and staging of lymphedema. *Semin Plast Surg* 32(1): 12–6
- JOBST (2021) *FarrowWrap*. Available at: <https://www.jobst.com/products/product-detail/farrowwrap-lite.html> (accessed 20.07.2022)
- Juzo (2021) *Juzo ACS Light*. Available at: <https://www.juzo.com/en/products/compression-garments/oedema-therapy/compression-systems-for-decongestion-therapy/juzo-acs-light> (accessed 20.07.2022)
- Letellier ME, Towers A, Shimony A, Tidhar D (2014) Breast cancer-related lymphedema: a randomized controlled pilot and feasibility study. *Am J Phys Med Rehabil* 93(9): 751–9; quiz 760–1
- Lymphoedema Framework (2006) *Best Practice for the Management of Lymphoedema. International Consensus*. London: MEP Ltd pp3–52
- Medi (2021) *Circaid Juxtafit*. Available at: <https://www.mediuk.co.uk/products/circaid-juxtafit-essentials-arm/> (accessed 20.07.2022)
- Morgan PA, Murray S, Moffatt CJ, Young H (2011) The experience of patients with lymphoedema undergoing a period of compression bandaging in the UK and Canada using the 3M™ Coban™ 2 compression system. *Int Wound J* 8(6): 586–98
- Mosti G, Cavezzi A (2019) Compression therapy in lymphedema: Between past and recent scientific data. *Phlebology* 34(8): 515–22
- Sezgin Ozcan D, Dalyan M, Unsal Delialioglu S et al (2018) Complex decongestive therapy enhances upper limb functions in patients with breast cancer-related lymphedema. *Lymphat Res Biol* 16(5): 446–52
- Sigvaris (2021) *Compreflex*. Available at: <https://www.sigvaris.com/en-us/catalog/product-styles/lymphedema-garments/compreflex-standard-arm> (accessed 20.07.2022)
- Soran A, D'Angelo G, Begovic M et al (2006) Breast cancer-related lymphedema—what are the significant predictors and how they affect the severity of lymphedema? *Breast J* 12(6): 536–43
- Thomas S (2017) The use of compression wraps in the management of lymphoedema. *Journal of Lymphoedema* 12(1): 32–8
- Tidhar D, Armer JM, Stewart BR (2018) What is clinically important in lymphedema management? A systematic review. *Rehabilitation Oncology* 36(1): 13–27
- Wittlinger H, Wittlinger D, Wittlinger A (2018) *Dr. Vodder's Manual Lymph Drainage: A Practical Guide*. New York: Thieme Medical Publishers