

Prontosan Debridement Pad

made easy



© Wounds International | May 2018 www.woundsinternational.com

Introduction

Wound bed preparation (WBP) is 'the management of a wound in order to accelerate endogenous healing or to facilitate the effectiveness of other therapeutic measures' (Falanga, 2002; Schultz et al, 2005). Defining WBP has helped clinicians to utilise the principles and components of wound care in a standardised way, to promote best practice and help overcome barriers to wound healing (Halim et al, 2012).

WBP provides a pathway by which clinicians can take steps to aid more efficacious wound healing in an organised, standardised way (Milne, 2015). The WBP process relies heavily on debridement to remove undesirable tissue and disrupt microbial burden that may form biofilm and cause infection, and there are numerous methods by which clinicians can achieve a clean, healthy wound bed to allow rapid and effective healing. One new option for mechanical debridement is the Prontosan Debridement Pad (B Braun), which uses microfibre technology to safely, gently and effectively remove coatings (e.g. biofilm) and dead cell residues (devitalised tissue and debris). With its hydrophilic composition, it is designed to absorb excess exudate and slough. Intact tissue is spared, and pain and discomfort are minimised for patients, as demonstrated by a clinical case series.

The importance of wound bed preparation

The TIME framework is a well-established assessment and management method, and remains the typical WBP paradigm in practice (Dowsett & Newton, 2005). Since its original presentation, substantial developments in our understanding of wound care have occurred; in particular, regarding the bacterial continuum through contamination, colonisation and infection, as well as the presence of biofilm. TIME remains relevant, but there is a need to ensure these developments are incorporated into assessments and choices regarding WBP (Leaper et al, 2012). Taking steps to aid more efficacious wound healing is critical to patient outcomes and quality of life (Table 1), as well as making cost savings by providing practical benefits that result in cost savings, such as reducing dressing changes/nursing visits (Guest et al, 2015).

Focus on debridement

The WBP process relies heavily on debridement (e.g. mechanical, sharp, autolytic) to remove undesirable tissue and disrupt microbial burden that may form biofilm and cause infection. Alongside wound cleansing, debridement is often the first step in any protocol of wound care. The aim of debridement is to obtain a clean, healthy wound bed to allow rapid and effective healing (Table 1). By removing devitalised tissue, excess exudate, senescent and abnormal cells, and microbial burden, healthy tissue is unimpeded, and granulation tissue encouraged to form in the wound bed (Halim et al, 2012). These factors allow wounds to progress to and through the final phase of wound healing and towards complete closure.

Table 1: The effects of debridement according to the principles of TIME (Dowsett & Newton, 2005; Ovens & Irving, 2018; B Braun, data on file)

Clinical observation	Proposed pathophysiology	Effect of debridement with Prontosan Debridement Pad	Clinical outcome
T issue non-viable or deficient	Defective matrix and cell debris impair healing	Gently clears wound bed of devitalised tissue and cleans surrounding skin	Viable wound base
I nfection or inflammation	Defective matrix and cell debris impair healing	Gently clears wound bed of devitalised tissue and cleans surrounding skin	Viable wound base
M oisture imbalance	Desiccation slows epithelial cell migration Excess exudate slows cell proliferation by interfering with growth factor availability, or delivering elevated levels of inflammatory mediators and activated matrix metalloproteinases to the wound bed	Absorbs harmful excess exudate; safe to remove devitalised tissue from dry wounds	Achievement of moisture balance
E dge of wound — non-advancing or undermining	Non-responsive wound cells and abnormalities in extracellular matrix or abnormal protease activity	Intact tissue is spared, allowing ingrowth of healthy tissue into the wound bed	Advancing edge of wound

Prontosan Debridement Pad **made easy**



	Benefits	Method	Considerations
Surgical/sharp	<ul style="list-style-type: none"> Fast methods of debridement Surgical (usually surgeons only in operating theatres): for large areas, typically under sedation/anaesthesia Sharp: for small areas 		<ul style="list-style-type: none"> Practitioner level: Advanced Requires procedure room and resources to manage complications (e.g. bleeding) Requires skills to obtain patient consent
Autolytic	<ul style="list-style-type: none"> Uses the body's own macrophages and proteolytic enzymes to liquefy and separate necrotic tissue from the wound bed Safe and natural 		<ul style="list-style-type: none"> Practitioner level: General Highly selective (may not remove all devitalised tissue) May require dressings to enhance phagocytic activity May not work particularly with complex patients/wounds
Enzymatic	<ul style="list-style-type: none"> Effective in the removal of hard necrotic eschar where surgical debridement is not an option Exogeneous enzymes combine with the body's own to break down tissue 		<ul style="list-style-type: none"> Practitioner level: Specialist/specialist-led Not commonly used Evidence indicates that this method should be combined with another, to ensure effectiveness
Larval	<ul style="list-style-type: none"> Quick and efficient Sterile larvae secrete powerful enzymes to break down devitalised tissue while sparing healthy granulation tissue Can be administered in both primary and secondary care settings 		<ul style="list-style-type: none"> Practitioner level: Specialist/specialist-led Requires specialist kit Requires patient compliance/education Some patients and staff may not find it socially acceptable
Hydro-surgical	<ul style="list-style-type: none"> A quick method of debridement Sterile water delivered at high pressure washes away dead tissue Effectively reduces microbial burden 		<ul style="list-style-type: none"> Practitioner level: Advanced Expensive Must be delivered in hospital Requires specialist training Low availability
Ultrasonic	<ul style="list-style-type: none"> Low-frequency, low-dose ultrasound breaks down devitalised tissue Safe and painless Shown to reduce bacterial burden Readily available 		<ul style="list-style-type: none"> Practitioner level: Advanced Usually delivered in hospital Requires specialist training
Mechanical	<ul style="list-style-type: none"> Microfibre technology increases effectiveness Soft, with no tissue irritation Droplet shape allows use in cavities and difficult-to-reach areas Can be used at home and in the community, no specialist training required 		<ul style="list-style-type: none"> Practitioner level: General Previous materials used for wound cleansing have been shown to be ineffective and painful (Collier and Hollingworth, 2000), and, therefore, the use of any debridement pad may necessitate changing attitudes towards newer methods

e.g. Prontosan Pad

Figure 1: Methods of debridement

» Innovative Shape - Designed for Success



Figure 2: The Prontosan Debridement Pad

It is important to remember that, while debridement provides the foundation of healing, debridement alone will not achieve healing and must be used as part of an overall management plan involving the patient, their disease process and the wound itself (Vowden & Vowden, 2011). Chronic wounds may require repeated, or maintenance, debridement to prevent the wound reverting to a chronic unhealthy state, regardless of debridement method chosen (Wolcott, 2009) (see Figure 1).

Old methods of mechanical debridement with wet or dry gauze are now considered to be potentially harmful, as they were ineffective or damaged the wound bed, and could cause significant pain for patients (Vowden & Vowden, 2011). As a result — and due to the need for effective, gentle, easy-to-use debridement options that can be administered by any practitioner level — soft-debridement technologies have been developed.

In community home care, some patients wish to be more self-reliant, to be able to continue working and have the flexibility of being cared for in their homes or at a location convenient to them, such as a GP surgery (Plaschke, 2013). Many methods of debridement require visits to a clinic or even time in a hospital procedure room, which can be deleterious to patient concordance with treatment — particularly as debridement may need to be performed repeatedly over the course of care for a chronic wound. Insufficient debridement delays healing and exposes the patient to increased risk of complications. To achieve optimum patient concordance and promotion of wound healing, it is important to take account all the complexities and individual needs of patients living with a wound (Wounds International, 2012). Debridement methods, such as use of the Prontosan Debridement Pad, which allow care to be performed in the community/GP setting or at home, can encourage patient concordance and may pose a cost-savings benefit in terms of helping wounds to heal faster.

The Prontosan Debridement Pad has been designed to offer a new WBP option that is safe, efficacious and gentle for patients (Figure 2). Composed of polyester and polypropylene, the 3mm thin, 80cm² pad consists of a front layer with microfibres that debride and an absorbent backing layer for rapid, effective and safe debridement. Clinical practice has shown that it frees the wound from coatings (e.g. biofilm), dead cell residues (devitalised tissue and debris) and absorbs excess exudate and slough. Intact tissue is spared, and pain and discomfort are minimised for patients. The Prontosan Debridement Pad produces good results even with scaly and necrotic coatings, if they have been subjected to prior autolytic treatment (Ovens & Irving, 2018).

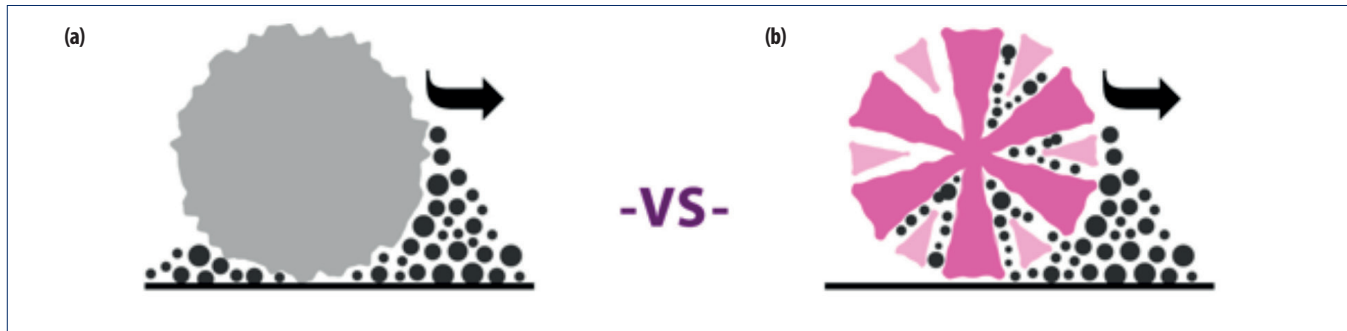
The Prontosan Debridement Pad is ideal for chronic wounds, including pressure ulcers, venous leg ulcers and diabetic foot ulcers. It does not require specialist training, and can be used in the community or home nursing settings, by practitioners at any skill level.

Mode of action: microfibre technology

The Prontosan Debridement Pad is composed of a flexible, hydrophilic material that contains microfibres — a fibrous structure that effectively picks up all particles. Microfibres are more effective at cleansing than traditional fibres, due to their size and structure: one microfibre is approximately 1/100th the diameter of a human hair, meaning that there are many more of them in the pad's surface area than in a traditional monofilament pad. Each microfibre has a split structure, producing several strands per fibre, which not only produces a greater 'lifting' effect but also allows the microfibre to retain particles of debris in the space between each strand — further increasing the surface area available for cleansing and removal of debris (Ovens & Irving, 2018).

Additionally, microfibres can use microscopic 'electrostatic forces' to bind to particles, increasing their ability to lift

Figure 3: The traditional monofilament (a) versus microfibre (b) structures



and retain particles of slough and debris (Ovens & Irving, 2018). Microfibres are able to attach themselves to even the smallest, most microscopic particles — ones that much-larger monofilament fibres can brush past (Figure 3).

If the forces of mechanical debridement were visible, one could observe that there are adhesive forces between microfibrils and the particles. There are millions of microfibrils in a pad, so the overall sticking effect is magnified dramatically. As a result, biofilm, slough, debris and devitalised cells can be quickly and effectively 'hoovered up' and retained in the pad, while sparing intact tissue. Furthermore, the hydrophilic composition of the Prontosan Debridement Pad absorbs excess exudate.

Focus on biofilm

In chronic or hard-to-heal wounds, biofilm development is likely to be a significant factor, therefore should be a key consideration in any WBP strategy. Fewer than 10 studies have visualised biofilms in non-healing chronic wounds using the accepted approaches of microscopy with or without molecular analysis (James et al, 2008; Kirketerp-Møller et al, 2008; Fazli et al, 2009; James et al, 2016; Han et al, 2011; Neut et al, 2011; Oates et al, 2014).

These studies identified the presence of biofilms in 60% to 100% of samples. In fact, a recent systematic review and meta-analysis demonstrated that up to 90% of chronic wounds have biofilm present and are a major cause of pain, discomfort and poor healing of wounds for patients (Malone et al, 2017).

The common characteristics of in vitro and in vivo evidence of biofilm include the following:

- Aggregation of bacteria
- Some sort of matrix that is not restricted to self-produce as it can also be of host origin
- Extreme tolerance and protection against most antimicrobial agents and the host defence (Wounds International, 2016).

Based on these common criteria, a simplified description can be used to define biofilm in the context of chronic wound infection: an aggregate of bacteria tolerant to treatment and the host defence, and invisible to the naked eye (Wounds International, 2016).

The formation of biofilm is a multi-step process that occurs quickly and is reversible during the early stages. However, as biofilm formation progresses, disruption and eradication become increasingly difficult. In part, this is because planktonic (free-floating) bacteria and bacterial colonies that make up biofilm behave differently in terms of protecting themselves. In addition, biofilm inhibits healing due to its relationship with the phenotypic abnormalities of cells in chronic wounds, as well as the chronic wound's pathophysiology. Presence of biofilm may be assumed in all chronic wounds, but assessment should be performed to confirm clinical suspicion of biofilm. Once the likelihood of biofilm presence is established, a multi-pronged biofilm-based treatment strategy should be determined, accounting for the multiple stages of biofilm formation (Bjarnsholt et al, 2017).

Reducing the amount of biofilm in a chronic wound may tip the balance in favour of healing; if biofilm is suspected of delaying healing of a chronic wound, it should be treated proactively by:

- Repeatedly breaking up and removing the biofilm — through vigorous/active cleansing and/or appropriate debridement
- Reducing biofilm reformation — by decreasing the microbial burden left in the wound through the use of an antimicrobial dressing (e.g. Prontosan Gel X) left in place between each session of biofilm removal (Phillips et al, 2010; Wolcott, 2009).

A proactive approach to treatment recognises that there is no one-step solution for treatment of biofilm, but aims to reduce bioburden and prevent its reconstitution (Ovens & Irving, 2018). If a wound is not progressing following regular treatment, a more aggressive approach to biofilm removal may be required, with specialist referral as appropriate (Wolcott et al, 2008).

Although biofilm is not visible to the naked eye, disruption can be seen in terms of wound improvement and healing.

Supported by an educational grant from B. Braun. The views expressed in this 'Made Easy' do not necessarily reflect those of B. Braun.

Authors: Irving S¹, Ovens L², Collier M³
1. Independent Tissue Viability Nurse Consultant
2. Tissue Viability Specialist Nurse
3. Nurse Consultant and Associate Lecturer (Lincolnshire, UK).

© Wounds International 2018 Available from: www.woundsinternational.com

A case series of six patients presenting to a leg ulcer clinic demonstrated the clinical effectiveness of the Prontosan Debridement Pad in removing biofilm as part of the debridement process. All cases involved long-term, chronic wounds in patients who were complicated by comorbidities and other factors that elevate risk of biofilm formation and, in turn, infection (Ovens & Irving, 2018).

Three patients' wounds healed completely (within 3–6 weeks); in one patient who had two wounds, one was moving towards closure, and the other demonstrated significant improvement in both wound bed (e.g. significant slough reduction) and periwound skin condition. For one patient with a small, hard-callous ulcer that was showing signs of undermining, the Prontosan Debridement Pad produced effective debridement such that the patient did not have to undergo sharp debridement, which had been considered the first line of care for that ulcer type. Even where the wounds were too

complex to achieve complete healing, significant improvements were seen: tenacious slough was reduced to the point that topical treatments could be effective. After 4 weeks of weekly administration of debridement with the Prontosan Debridement Pad, granulation tissue was forming on both legs (the patient had presented with multiple wounds), the quality of skin had improved and progress was made towards healing (Figures 4a and 4b depict one of these wounds).

In all cases, patient comfort was noted, and patients were satisfied with the treatment. All patients were able to tolerate the product, including one patient with *Pyoderma Gangrenosum*. Clinical judgement was used to determine effective results; regardless of whether the wound was pre-soaked (with distilled water, sodium chloride, Prontosan solution) or not. The clinician noted that effects were improved when the wound was pre-soaked, but using the product independently is an effective option where necessary (Ovens & Irving, 2018).

References

- Bjarnsholt T, Eberlein T, Malone M, Schultz G (2017) Management of wound biofilm made easy. London: *Wounds International* Available from: www.woundsinternational.com
- B Braun, data on file
- Collier M, Hollinworth H (2000) Nurses views about pain and tissue trauma at dressing changes: results of a national survey *J Wound Care* 9(8): 369-73
- Dowsett C, Newton H (2005) Wound bed preparation: TIME in practice. *Wounds UK* 1(3): 58-70
- Falanga V (2002) Wound bed preparation and the role of enzymes: a case for multiple actions of therapeutic agents. *Wounds* 4(2):47-57
- Fazli M, Bjarnsholt T, Kirketerp-Møller K et al (2009) Non-random distribution of *Pseudomonas aeruginosa* and *Staphylococcus aureus* in chronic wounds. *J Clin Microbiol* 47(12): 4084-9
- Guest J, Ayoub N, McIlwraith T (2015) Health economic burden that wounds impose on the National Health Service in the UK. *BMJ Open* 5(12) <http://dx.doi.org/10.1136/bmjopen-2015-009283>
- Halim AS, Khoo TL, Mat Saad AZ (2012) Wound bed preparation from a clinical perspective. *Indian J Plast Surg* 45(2):193-202
- Han A, Zenilman JM, Melendez JH et al (2011) The importance of a multifaceted approach to characterizing the microbial flora of chronic wounds. *Wound Repair Regen* 19(5): 532-4
- James GA, Swogger E, Wolcott R et al (2008) Biofilms in chronic wounds. *Wound Repair Regen* 16(1):37-44
- James GA, Zhao AG, Usui M et al (2016). Microsensor and transcriptomic signatures of oxygen depletion in biofilms associated with chronic wounds. *Wound Repair Regen* doi: 10.1111/wrr.12401.
- Kirketerp-Møller K, Jensen PØ, Fazli M et al (2008) Distribution, organization, and ecology of bacteria in chronic wounds. *J Clin Microbiol* 46(8):2717-22
- Leeper DJ, Schultz G, Carville K et al (2012) Extending the TIME concept: what have we learned in the past 10 years? *Int Wound J* 9(Suppl 2):1-19
- Malone M, Bjarnsholt T, McBain A, et al (2017) The prevalence of biofilms in chronic wounds: a systematic review and meta-analysis of published data. *J Wound Care* 26(1):20-5
- Milne J (2015) Wound Bed preparation, the importance of rapid and effective desloughing to promote healing. *Br J Nurs* 24(20): S52-8
- Neut D, Tjeldens-Creusen EJ, Bulstra SK et al (2011) Biofilms in chronic diabetic foot ulcers — a study of 2 cases. *Acta Orthop* 82(3): 383-5
- Oates A, Bowling FL, Boulton AJ et al (2014). The visualization of biofilms in chronic diabetic foot wounds using routine diagnostic microscopy methods. *J Diabetes Res* 153586
- Ovens L, Irving S (2018) Advances in wound cleansing: an integrated approach. *Wounds UK* 14(1): 58-63
- Phillips PL, Fletcher J, Shultz G S (2010) Biofilms Made Easy. *Wounds International* 1(3): 1-6
- Plaschke M (2013) Cost benefits in using a microfiber debridement pad in the healing of a venous leg ulcer. Presented at: *European Wound Management Association* 2013, Copenhagen
- Schultz G, Ladwig G, Wysocki A (2005) Extracellular matrix: review of its role in acute and chronic wounds. *World Wide Wounds*. Available from: www.worldwidewounds.com
- Vowden K, Vowden P (2011) Debridement made easy. *Wounds UK* 7(4). Available from: www.wounds-uk.com
- Wolcott, RD, Kennedy JP, Dowd SE (2009) Regular debridement is the main tool for maintaining a healthy wound bed in most chronic wounds. *J Wound Care* 18(2): 54-6
- Wolcott RD, Rhoads DD (2008) A study of biofilm based wound management in subjects with critical limb ischaemia. *J Wound Care* 17(4):145-55
- World Union of Wound Healing Societies (2016), Florence Congress, Position Document. Management of Biofilm. London: *Wounds International*
- Wounds International (2012) Optimising wellbeing in people living with a wound. An expert working group review. Available from: www.woundsinternational.com

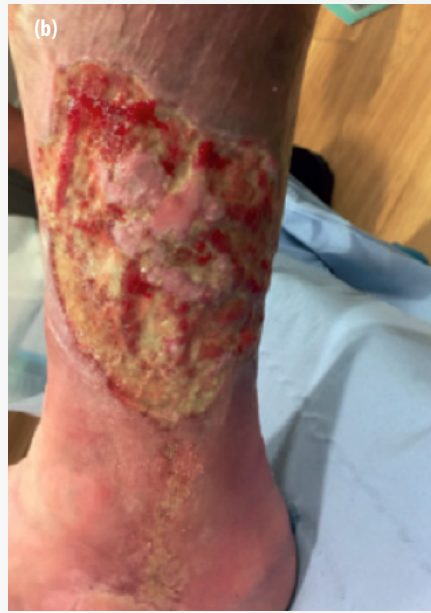
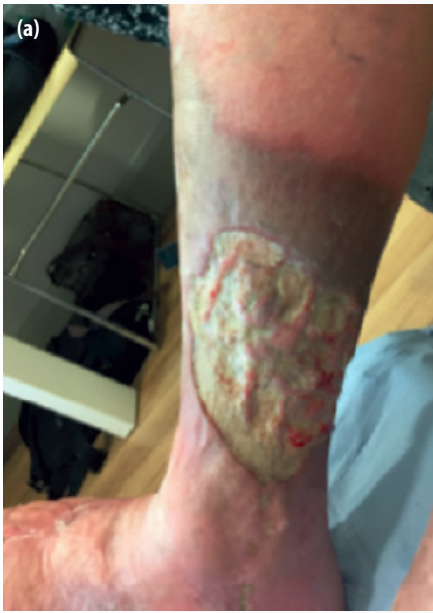
Figure 4(a) and (b): Before and after use of Prontosan Debridement Pad on a sloughy venous ulcer

Using the Prontosan Debridement Pad in practice

The Prontosan Debridement Pad is indicated in chronic wounds, including pressure ulcers, venous leg ulcers and diabetic foot ulcers. The Prontosan Debridement Pad has been designed to support WBP in conjunction with Prontosan Wound Irrigation Solution or, if unavailable, with physiological sodium chloride or distilled water. There is a simple, three-step process for using Prontosan Debridement Pad to safely and effectively debride the wound bed and periwound skin.

STEP 1.

Moisten the unmarked side of the pad with Prontosan Wound Irrigation Solution (or saline solution or distilled water), in the blister packaging that allows for safe and aseptic soaking of the pad prior to use; 15–20ml is sufficient to moisten the entire pad. If local guidelines exist, they should be observed.

STEP 2.

Applying gentle pressure, wipe the moistened side over the wound and/or adjacent skin in a circular or sweeping motion.

STEP 3.

After debridement, it is advisable to irrigate the wound thoroughly for a second time with Prontosan Wound Irrigation Solution (or other indicated solution), in order to thoroughly cleanse the wound and remove any traces of debris/biofilm, and to continue with appropriate treatment, based on holistic assessment and local protocols.

The pad is sterile and individually packed, and is intended for single use only. It should not be rinsed or reused; cut to size; used as a wound dressing; used in cases of known intolerance or allergy to one or more of the pad's components.

Summary

The unique shape and the low profile of the Prontosan Debridement Pad has shown that it can be used in multiple wound types, as demonstrated by the clinical case series, including wounds in hard-to-reach areas. The edge-to-edge microfibres on the pad ensure rapid and soft debridement that obtains a clean wound bed and surrounding skin while sparing intact tissues. With its novel mode of action that clears slough and disrupts biofilm more effectively than other currently used mechanical debridement methods, the Prontosan Debridement Pad thus presents a new advance in mechanical debridement as part of a multi-pronged biofilm-based wound care approach.