

Evolution of the wound infection continuum



Authors:
Emily Haesler and Karen Ousey

In 2016, the International Wound Infection Institute reviewed the wound infection continuum through a literature review and formal Delphi process. This article discusses some significant changes made to the wound infection continuum, including changes in terminology used to describe phases of wound infection, and distinction between early (covert) signs of local infection and the overt classic Celsian signs. Clinical indicators of potential biofilm in a wound, which were agreed on by experts as part of the Delphi process, are explored. An overview of strategies to manage local wound infection, and the important role of antiseptics in providing an option for early action against microbial proliferation, are also presented.

Wound infection is defined as the presence of a wound environment characterised by microbes in sufficiently large numbers, or of sufficient virulence to provoke an immune response locally, systemically or both. Whenever there is a break in the skin integrity, bacteria can enter the body and begin multiplying. Without the protective barrier of the skin, sensitive tissues in the wound bed are vulnerable to microbial colonisation. When microorganisms invade a wound and start proliferating, local tissue damage occurs and wound healing is disrupted (Eberlein, 2006; Siddiqui and Bernstein, 2010).

Update to the wound infection continuum

The wound infection continuum characterises the progression of infection in a wound. A 'continuum' is a continuous sequence in which adjacent elements are not perceptibly different from each other, but the extremes are quite distinct (Merriam-Webster Online Dictionary, 2018). This conceptualisation of the impact that infection has on a wound and the person with a wound as a continuum recognises that distinct stages of infection are difficult to define and identify. However, there is a large and easily distinguishable difference between a non-infected wound and an individual with systemic infection arising from microbes in a wound.

As stages of infection cannot be neatly demarcated, there has been ongoing debate about the distinct wound infection stages and their relationship to clinical signs and symptoms. In 2016, the International Wound Infection Institute

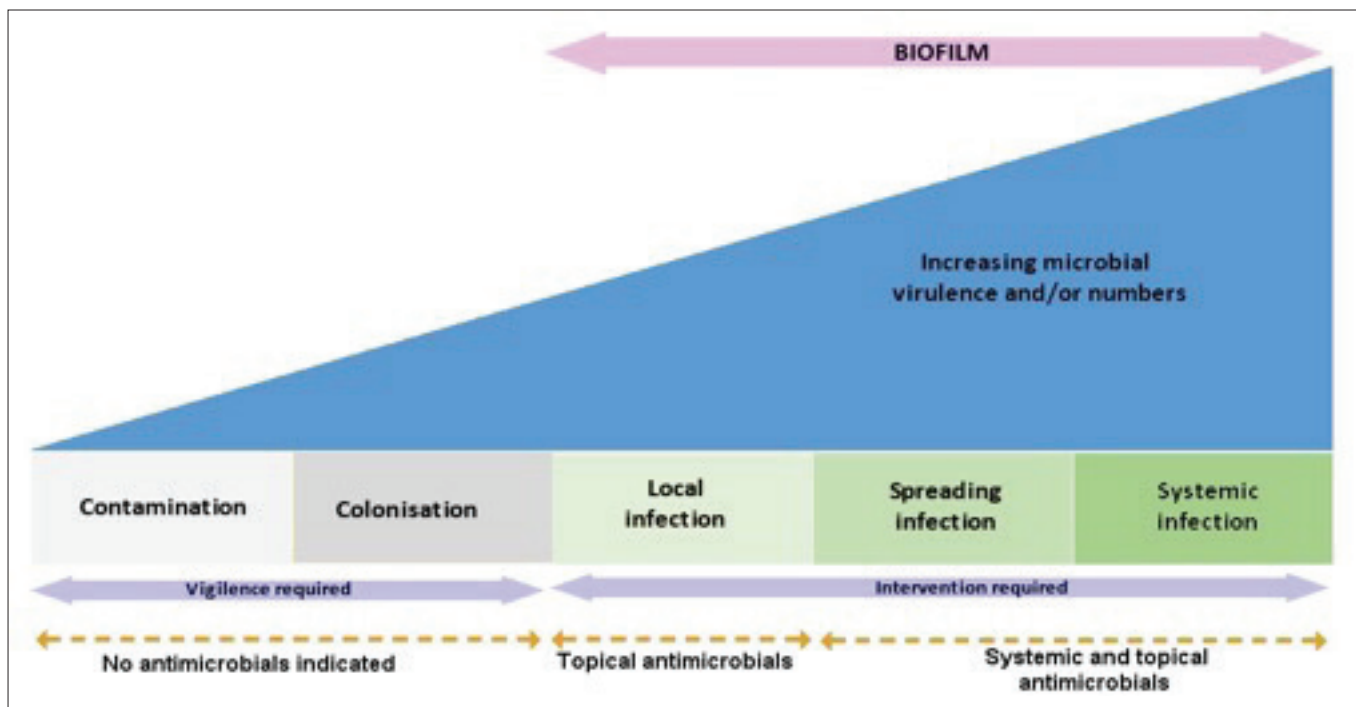
(IWII) presented a revision of the wound infection continuum that aligned the phases of infection with the clinical response of the individual and the wound (IWII, 2016). The wound infection continuum revision was developed using a consensus voting (Delphi) process underpinned by a literature review. In an iterative, three-round voting process, experts from the IWII executive committee reached agreement on wound infection definitions and terminology, as well as an update on the conceptualisation and presentation of the wound infection continuum (IWII, 2016).

This process, which used a previously validated and published method, allowed the participants to reach agreement on statements using a valid and reliable that had been adapted to an online process (Haesler et al, 2018).

The first phase of the wound continuum is considered to be contamination. This recognises the well-established fact that all wounds acquire micro-organisms, often from normal flora from the periwound skin. However, if the wound bed does not provide an appropriate environment for the microbials species they will not multiply or persist, and their presence is neither detrimental nor persistent (Cooper, 2005; IWII, 2016).

Contamination describes the point at which microbial species successfully grow and divide. At this point, microbes begin to proliferate in a favourable environment, but are not in sufficient levels or virulence to disturb wound healing or provoke an immune response (Dow et al, 1999; Enoch and Harding, 2003). There are no clinical signs and symptoms as the healing trajectory continues as expected; however, laboratory

Emily Haesler is Adjunct Associate Professor, Curtin University, School of Nursing, Midwifery and Paramedicine, Perth, Australia; Honorary Senior Lecturer, Australian National University, ANU Medical School, Academic Unit of General Practice, Canberra, Australia; Honorary Associate, La Trobe University, School of Nursing and Midwifery, Bundoora, Australia; Karen Ousey is Professor of Skin Integrity, Director for the Institute of Skin Integrity and Infection Prevention, University of Huddersfield, Department of Nursing and Midwifery, England. Adjunct Professor, School of Nursing, Faculty of Health, Queensland University of Technology, Australia



Contamination ⁶	Colonisation ⁶	Local infection		Spreading infection ^{19, 20}	Systemic infection ^{19, 20}
All wounds may acquire micro-organisms. If suitable nutritive and physical conditions are not available for each microbial species, or they are not able to successfully evade host defences, they will not multiply or persist; their presence is therefore only transient and wound healing is not delayed.	Microbial species successfully grow and divide, but do not cause damage to the host or initiate wound infection.	Covert (subtle) signs of local infection: ^{10, 12, 15-17, 32-37} <ul style="list-style-type: none"> • Hypergranulation (excessive 'vascular' tissue) • Bleeding friable granulation • Epithelial bridging and pocketing in granulation tissue • Wound breakdown and enlargement • Delayed wound healing beyond expectations • New or increasing pain • Increasing malodour 	Overt (classic) signs of local infection: ^{12, 15, 16, 36, 37} <ul style="list-style-type: none"> • Erythema • Local warmth • Swelling • Purulent discharge • Delayed wound healing beyond expectations • New or increasing pain • Increasing malodour 	<ul style="list-style-type: none"> • Extending induration or erythema • Lymphangitis • Crepitus • Wound breakdown/dehiscence with or without satellite lesions • Induration • Malaise/ lethargy or non-specific general deterioration • Loss of appetite • Inflammation/ swelling of lymph glands 	<ul style="list-style-type: none"> • Severe sepsis • Septic shock • Organ failure • Death

Figure 1. The International Wound Infection Institute's Wound Infection Continuum and associated signs and symptoms of wound infection stages (reproduced with permission) (Edwards and Harding, 2004; WUWHS, 2008; Lipsky and Hoey, 2009).

specimens from the wound would confirm microbes in proliferating numbers.

The term 'critical colonisation' has previously been included into the wound infection continuum as a stage following contamination. The term was used to refer to growth of bacteria within a chronic wound without causing the signs and symptoms traditionally associated with infection (Edwards

and Harding, 2004). The stage is considered to be when a chronic wound displays signs of delayed healing, and the term implies that a critical number or virulence of microbes has been reached. However, the literature provides no guidance on what this critical level may be, and the term 'critical colonisation' has remained poorly defined (White and Cutting, 2005; White et al, 2006). The difficulty

in determining when critical colonisation is reached led the IWII Executive Committee to reach agreement to remove this term from the revised wound infection continuum (IWII, 2016) (see the revised continuum in *Figure 1*).

Local wound infection — covert and overt signs and symptoms

When bacteria or other microbes present in the wound move deeper into wound tissue and proliferate in a way that overwhelms the immune system (Collier, 2004; Siddiqui and Bernstein, 2010), colonisation progresses to local infection. In this stage, infection is maintained within the bounds of the wound bed, contained in the one location, system or structure.

Local wound infection often presents in a subtle manner that may not be readily identified without conscientious wound assessment and a strong understanding of early indicators that bacteria may be present in quantities or virulence that are a threat (Sibbald et al, 2006; 2007). Wound breakdown, delayed healing, new pocketing and epithelial bridging are early signs that tissue is not healing along the optimal trajectory (Cutting and Harding, 1994; Gardner et al, 2001; Collier, 2004; Gardner and Frantz, 2008).

Recognising the earliest signs and symptoms of wound infection is essential. Intervening promptly with appropriate infection management strategies is important for preventing more extensive local tissue damage and avoiding further microbial proliferation, delays to wound healing and potential severe sequelae. These early and subtle indicators of local wound infection gradually emerge (particularly in chronic wounds) and are, therefore, referred to in the 2016 update of the *Wound Infection in Clinical Practice* consensus document (IWII, 2016) as covert signs of infection.

Further along the wound infection continuum, when the host response to microbial invasion increases, the classic signs of local wound infection become evident. Purulent discharge, erythema and swelling, local warmth, increasing malodour and new or increasing pain are classic signs of infection in any organ of the body (Sibbald et al, 2003; IWII, 2016). The classic signs of local wound infection reflect the host's inflammatory response. As the host responds, the increase in local blood flow causes a local warmth. Erythema and pain develop due to activation of vasoactive mediators (e.g. histamine). Purulence and malodour are produced by bacteria processes (IWII, 2016).

In wounds, these classic signs of infection are also accompanied by delays in wound healing beyond expectations. When bacteria inhibit the development of healthy granulation tissue,

undermining can occur. Friable granulation tissue can occur due to bacterial burden interfering with healthy collagen formation (Sibbald et al, 2003). Because the classic Celsian signs of local wound infection are generally easy to detect by simply visualising the wound bed, the IWII refers to this stage on the wound infection continuum as overt (classic) signs of local infection (IWII, 2016).

Beyond the wound — later stages of the wound infection continuum

When pathogens proliferate beyond the bounds of the wound, spreading infection has occurred (World Union of Wound Healing Societies [WUWHS], 2008; Leaper et al, 2012). If uncontained by the host response, microbial infection begins to spread beyond the wound into other local structures, including deeper tissue, surrounding tissue, muscle, fascia and local organs. The immune response to wound infection also becomes evident outside the bounds of the wound. Signs and symptoms of spreading infection include extending erythema, extending induration, crepitus and inflammation of the lymph glands and lymphatic vessel walls (lymphangitis).

The individual might lose their appetite and experience malaise, lethargy and other non-specific deterioration (WUWHS, 2008; Leaper et al, 2012; IWII, 2016). During this phase, the wound bed continues to experience dehiscence with or without satellite lesions of infection breakdown, while the overt signs of local wound infection remain apparent.

Systemic infection is said to occur when the impact of wound infection is on the body as a whole (WUWHS, 2008; Leaper et al, 2012; IWII, 2016). Microbials that entered the host through the wound bed gradually proliferate until they extend throughout the body via the vascular or lymphatic systems (WUWHS, 2008; Leaper et al, 2012; IWII, 2016). Clinical signs and symptoms of this invasion reflect systemic inflammatory response from the host, including severe sepsis and septic shock, organ failure and death.

Biofilm in the wound infection continuum

The revised wound infection continuum recognises the advancing knowledge on biofilm in chronic wounds and its relationship to both microbial action and clinical signs and symptoms. It is now recognised that as microbials increase in number and virulence, biofilm form, mature and continually disperse (Cutting and McGuire, 2015; Nouraldin et al, 2016; Uppuluri and Lopez-Ribot, 2016). Biofilm is likely to be present in chronic wounds that have sufficient bacterial virulence or numbers to evoke

an inflammatory and immune response from the host.

Clinical signs and symptoms that biofilm may be present reflect those of early local infection, including increasing exudate and moisture, low level inflammation and erythema, poor granulation or friable hypergranulation. Biofilm may be present, especially in chronic wounds that have delayed healing in optimal conditions, recalcitrance to antimicrobial therapy and failure of appropriate antibiotics to resolve symptoms. These clinical indicators of potential biofilm presence in a chronic wound were agreed on by the IWII Executive Committee using a formal Delphi process and underpinned by a literature review of the current scientific evidence (IWII, 2016).

When the clinical indicators listed above are present, biofilm-based wound care, which includes appropriate cleansing, wound bed debridement and topical antiseptics, is an appropriate course of management (Rhoads et al, 2008; Leaper et al, 2012; Wolcott, 2015; Bianchi et al, 2016). The 2016 update of the *Wound Infection in Clinical Practice* document outlines implementation of these interventions to address biofilm-based wound care strategies to best effect (IWII, 2016).

Addressing wound infection

In addition to outlining the stages of wound infection as they relate to the pathophysiological action of microbes increasing in number and vigilance, the wound infection continuum provides guidance on interventions that are appropriate at each stage.

In the early stages, when microbial colonisation has not interfered with the host's health or the wound healing process, being alert to the risks of local infection is important. In these (and other) stages on the wound infection continuum, implementing strategies to prevent cross-infection, facilitating wound drainage, using antimicrobial dressings and optimising the wound bed environment, all optimise healing and reduce the risk of the wound being overcome by bacterial proliferation.

Optimising the health of the individual, including management of comorbidities and optimisation of nutritional status, is important to strengthening the potential of the immune response to respond rapidly and effectively (WUWHS, 2007; Australian Wound Management Association and New Zealand Wound Care Society, 2012; National Pressure Ulcer Advisory Panel et al, 2014; Lipsky et al, 2016).

When signs of local wound infection emerge, rapid response with appropriate management strategies is an imperative. It is at this point that

having the clinical skills to identify covert signs of infection is an advantage. When the earliest indicators of local infection are evident, more aggressive treatment should be initiated. This generally includes the use of topical antimicrobial therapies, including antibacterial wound dressings and topical antiseptics (Leaper et al, 2012).

Antiseptics are non-selective solutions that disrupt the ability of microbes to proliferate. However, antiseptics have potential adverse effects, as some are cytotoxic (may kill healthy wound tissues). As cytotoxicity is thought to be concentration dependent (Siddiqui et al, 2010; Leaper et al, 2012), antiseptic use is recommended at the lowest concentration, and preparations that cause more excessive tissue damage (e.g. hydrogen peroxide and sodium hypochlorite) are no longer recommended (IWII, 2016). A wide range of antiseptics appropriate for use in the stages of covert local infection, overt local infection and beyond are described in the 2016 update of the *Wound Infection in Clinical Practice* document, including more guidance on their indications and use (IWII, 2016).

Although antibiotic therapy is not recommended for routine use in promoting wound healing, judicious use of antibiotics when wound overt signs of wound infection are present and there is microbial confirmation of causative agent and its sensitivities (Gürgen, 2014). The global crisis of increasing antibiotic resistance (World Health Organization, 2014; Centers for Disease Control and Prevention, 2016) requires that all antibiotic use be reserved for situations in which local interventions are insufficient to control infection.

Conclusion

The revision of the wound infection continuum continues to recognise the stage on the wound infection continuum previously referred to as 'critical colonisation'. Recognising this stage as covert local infection changes the focus from an undefined level of bacterial proliferation to the clinical signs and symptoms associated with an early inflammatory response from the host. Having the skills and confidence to identify the early, covert signs of infection is important, as reacting early to indicators suggesting that the person's immune response is overwhelmed prevents severe sequelae of untreated local wound infection. Being able to identify when vigilance should become active intervention is imperative to providing rapid and appropriate management with cleansing and debridement, topical antiseptics and, in cases where the local therapy is inadequate, systemic antibiotics.

WINT

Acknowledgement

Expert participants in the Delphi process referred to in this article were Board members of the IWII at the time the study was conducted: Donna Angel, Joyce Black, Evan Call, Keryln Carville, José Contretas Ruiz, Rose Cooper, Jacqueline Fletcher, Lindsay Kalan, David Keast, Gojjiro Nakagami, Karen Ousey, Gregory Schultz, Geoff Sussman and Terry Swanson.

The 2016 update of the *Wound Infection in Clinical Practice* is accessible at: http://www.woundinfection-institute.com/2016/11/httpwww-woundinfection-institute-comwp-contentuploads201707iwii-consensus_final-2017-pdf/

References

- Australian Wound Management Association, New Zealand Wound Care Society (2012) *Australia and New Zealand Clinical Practice Guideline for Prevention and Management of Venous Leg Ulcers*. Cambridge Media: Osborne Park, WA
- Bianchi T, Wolcott RD, Peghetti A et al (2016) Recommendations for the management of biofilm: a consensus document. *J Wound Care* 25(6): 305–17
- Centers for Disease Control and Prevention (2016) *Antibiotic/Antimicrobial Resistance*. Available at: <https://bit.ly/2N7oMf8> (accessed 31.10.2018)
- Collier M (2004) Recognition and management of wound infections. *World Wide Wounds*. Available at: <https://bit.ly/1KwbFwT> (accessed 31.10.2018)
- Cooper R (2005) Understanding wound infection. In: Cutting K et al (eds.) *Identifying Criteria for Wound Infection*. European Wound Management Association Position Document. MEP Ltd, London
- Cutting KF, Harding KG (1994) Criteria for identifying wound infection. *J Wound Care* 3(4): 198–20
- Cutting KF, White RJ, Maloney P, Harding KD (2005) Clinical identification of wound infection: A Delphi approach. In: Calne S (ed.) *European Wound Management Association Position Document: Identifying Criteria for Wound Infection*. MEP Ltd, London
- Dow G, Browne A, Sibbald G (1999) Infection in chronic wounds: Controversies in diagnosis and treatment. *Ostomy Wound Manage* 45(8): 23–40
- Eberlein T (2006) Critical Colonisation and Local Infection - current therapy by use of polihexanide. Lohmann-Rauscher; Rengsdorf, Germany. Available at: <https://bit.ly/2zeYySb> (accessed 31.10.2018)
- Edwards R, Harding KG (2004) Bacteria and wound healing. *Curr Opin Infect Dis* 17(2): 91–6
- Enoch S, Harding K (2003) Wound bed preparation: The science behind the removal of barriers to healing. *Wounds* 15(7): 213–29
- Galpin JE, Chow AW, Bayer AS, Guze LB (1976) Sepsis associated with decubitus ulcers. *Am J Med* 61: 346–50
- Gardner SE, Franz RA, Doebbeling BN (2001) The validity of the clinical signs and symptoms used to identify localized chronic wound infection. *Wound Repair Regen* 9(3): 178–86
- Gardner SE, Frantz RA, Park H, Scherubel M (2007) The inter-rater reliability of the clinical signs and symptoms checklist in diabetic foot ulcers. *Ostomy Wound Manage* 53(1): 46–51
- Gardner SE, Frantz RA (2008) Wound bioburden and infection-related complications in diabetic foot ulcers. *Biol Res Nurs* 10(1): 44–53
- Gürgen M (2014) Excess use of antibiotics in patients with non-healing ulcers. *EWMA Journal* 14(1): 17–22
- Haesler E, Carville K, Haesler P (2018) Priority issues for pressure injury research: an Australian consensus study. *Res Nurs Health* doi: 10.1002/nur.21878 [Epub ahead of print]
- International Wound Infection Institute (2016) *Wound Infection in Clinical Practice. International Consensus*. Wounds International, London. Available at: <https://bit.ly/2iWLDAC> (accessed 31.10.2018)
- Joseph WS, Lipsky BA (2010) Medical therapy of diabetic foot infections. *J Am Podiatr Med Assoc* 100(5): 395–400
- Kingsley AR (2003) The wound infection continuum and its application to clinical practice. *Ostomy Wound Manage* 47(7A Suppl): 1–7
- Leaper DJ, Schultz G, Carville K et al (2012) Extending the TIME concept: what have we learned in the past 10 years? *Int Wound J* 9(Suppl 2): 1–19
- Lipsky BA, Hoey C (2009) Topical antimicrobial therapy for treating chronic wounds. *Clin Infect Dis* 49(10): 1541–9
- Lipsky BA, Aragón-Sánchez J, Diggle M et al (2016) IWGDF guidance on the diagnosis and management of foot infections in persons with diabetes. *Diabetes Metab Res Rev* 32(Suppl 1): 45–74
- Merriam-Webster Online Dictionary (2018) *Definition of 'Continuum'*. Available at: <https://bit.ly/2JYVJD0> (accessed 31.10.2018)
- National Pressure Ulcer Advisory Panel, European Pressure Ulcer Advisory Panel, Pan Pacific Pressure Injury Alliance (2014) *Prevention and Treatment of Pressure Ulcers: Clinical Practice Guideline*. Cambridge Media: Osborne Park, WA
- Rhoads DD, Wolcott RD, Percival S (2008) Biofilms in wounds: management strategies. *J Wound Care* 17(11): 502–8
- Sibbald RG, Woo K, Ayello E (2007) Increased bacterial burden and infection: NERDS and STONES. *Wounds UK* 3(2): 25–46
- Sibbald RG, Woo K, Ayello EA (2006) Increased bacterial burden and infection: the story of NERDS and STONES. *Adv Skin Wound Care* 19(8): 447–61; quiz 61–3
- Sibbald RG, Orsted H, Schultz G et al (2003) Preparing the wound bed 2003: Focus on infection and inflammation. *Ostomy Wound Manage* 49(11): 24–51
- Siddiqui A, Bernstein J (2010) Chronic wound infection: Facts and controversies. *Clin Dermatol* 28(5): 519–26
- Stotts NA, Hunt TK (1997) Managing bacterial colonization and infection. *Clin Geriatr Med* 13(3): 565–73
- White RJ, Cutting KF, Kingsley A (2005) Critical colonisation: clinical reality or myth? *Wounds UK* 1(1): 94–5
- White RJ, Cutting KF (2006) Critical colonization—the concept under scrutiny. *Ostomy Wound Manage* 52(11): 50–6
- Wolcott R (2015) Economic aspects of biofilm-based wound care in diabetic foot ulcers. *J Wound Care* 24(5): 189–94
- World Health Organization (2014) *Antimicrobial Resistance: Global Report on Surveillance 2014*. WHO: Geneva, Switzerland. Available at: <https://bit.ly/1hV6O7E> (accessed 31.10.2018)
- World Union of Wound Healing Societies (2008) *Principles of Best Practice: Wound Infection in Clinical Practice. An International Consensus*. MEP Ltd, London. Available at: <https://bit.ly/2AEZJWv> (accessed 31.10.2018)
- World Union of Wound Healing Societies (2007) *Principles of Best Practice: Wound Exudate and the Role of Dressings. A Consensus Document*. MEP Ltd, London. Available at: <https://bit.ly/2DdHe4e> (accessed 31.10.2018)