

A focus on the Triangle of Wound Assessment — addressing the gap challenge and identifying suspected biofilm in clinical practice

Authors:

Caroline Dowsett, Terry Swanson
and Tonny Karlsmark

Wound assessment should be comprehensive, systematic and evidence-based (World Union of Wound Healing Societies [WUWHS], 2016a). The Triangle of Wound Assessment offers clinicians a framework to assess the patient and their wound, taking into consideration the wound bed, wound edge and periwound skin (Dowsett et al, 2015). The framework can be adapted to incorporate new developments and new challenges in wound care such as the 'gap challenge' and biofilm prevention and management. Using the framework can assist in determining the status of the wound bed and support clinical decision making to prevent problems associated with exudate pooling at the wound bed and the potential for biofilm formation.

The Triangle of Wound Assessment was established in 2014 and provides a systematic approach to wound assessment and in setting management goals, to guide optimal treatment choice (Dowsett et al, 2015), ensuring that the periwound skin is incorporated into the assessment. Periwound skin can be a significant problem in patients with chronic wounds, with between 60–70% of wounds found to be surrounded by either problematic or unhealthy periwound skin (Cartier et al, 2014). It is, therefore, fundamental for these chronic wounds, and all other types of wounds to be assessed in three key areas: the wound bed, the wound edge and the periwound skin, which are incorporated by the Triangle of Wound Assessment (Dowsett et al, 2015).

More recently, the framework highlights the significance of the gap challenge and the potential for biofilm formation when exudate pools at the wound bed (Dowsett et al, 2018). The wound gap refers to the gap that can present between the wound bed and the dressing.

An appropriate wound dressing should make intimate contact with the wound bed, while absorbing and retaining levels of wound exudate (Snyder, 2005; Cutting et al, 2009). It can be a clinical challenge to manage and close the gap, which occurs when a dressing fails to conform to the wound bed. Additionally, managing wound bioburden can be challenging and biofilm based wound care needs to be considered in non-healing chronic wounds that are not responding to standard best practice.

This article will discuss how the Triangle of Wound Assessment identifies infection and biofilm, tackles the gap challenge, and how this framework can be developed for new challenges in wound care.

The importance of holistic assessment

Wounds are a significant source of cost to patients, as well as to the health economy. Chronic wounds are often hard to heal resulting in a cycle of pain, anxiety and reduced quality of life for the individual patient. Delayed wound healing and wound complications add considerably to the cost of care and are associated with longer and more intensive treatment, extended hospital stays or readmission, and specialist intervention (Dowsett, 2015).

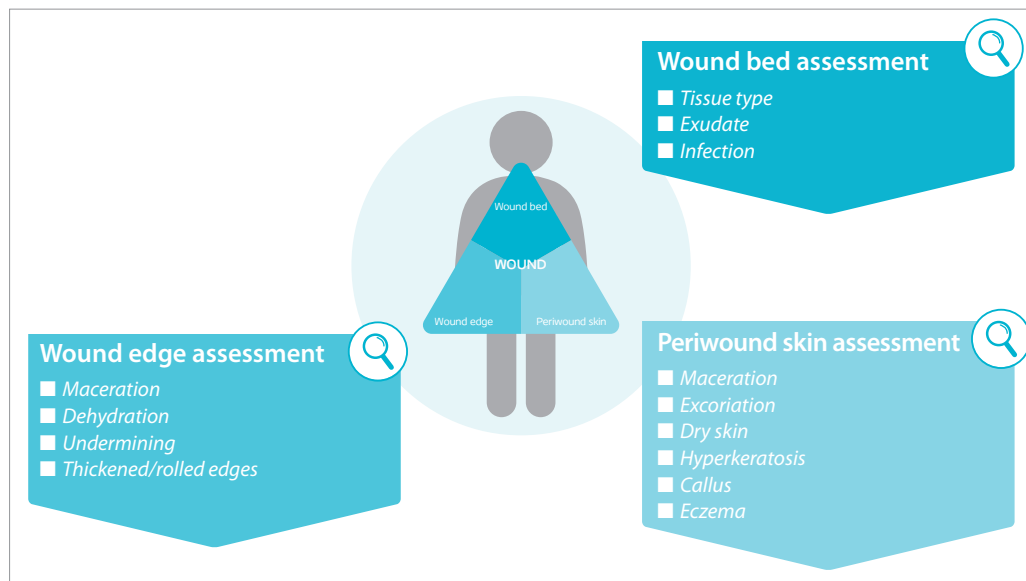
Evidence suggests that many patients with wounds lack an accurate diagnosis and are often managed with an inappropriate treatment plan (Guest et al, 2017). Accurate and timely wound assessment should be integral to managing a patient with a wound. Wound assessment needs to be comprehensive, systematic and evidence-based, providing baseline information against which clinicians can establish the current status of the wound, set realistic treatment goals and monitor progress over time using appropriate interventions. Poor assessment can lead to inappropriate treatment choices, contributing to poor outcomes for patients and additional resource costs.

Caroline Dowsett is Clinical Nurse Specialist Tissue Viability, East London NHS Foundation Trust, London & Independent Nurse Consultant in Wound Care, London

Terry Swanson is Nurse Practitioner Wound Management, South West Healthcare, Australia

Tonny Karlsmark is Clinical Associate Professor, Department of Dermatology, Copenhagen University Hospital, Bispebjerg Hospital, Copenhagen

Figure 1. The Triangle of Wound Assessment.



The role of structured assessment tools

Wound assessment and management frameworks offer clinicians an opportunity to improve wound assessment, patient outcomes and reduce the burden of chronic wounds. Assessment should aim to establish the correct diagnosis to ensure treatment of the underlying cause of the wound, as well as assessing size and depth of the wound and managing the wound. Wound assessment should record the wound type, location, size, wound bed condition, wound edge and the condition of the periwound area, and this should be ongoing as part of re-assessment. There are many benefits to improving wound assessment of chronic wounds and best practice in holistic wound assessment has the potential to:

- Improve healing rates
- Reduce the physical, emotional and socioeconomic impact of wounds on patients
- Benefit practitioners and the health economy by reducing the overall burden of wounds, potentially decreasing workload and the costs associated with wound care
- Raise practitioner and patient morale by improving patient outcomes (Wounds UK, 2018).

The Triangle of Wound Assessment

The Triangle of Wound Assessment is a well-established and easy to use framework for intuitive wound assessment that combines evaluation of the periwound skin within the wound bed preparation paradigm, while acknowledging the importance of treating the patient as well as the wound. It was developed to facilitate accurate and timely wound assessment in a simple and easy-to-use format,

that can be incorporated into any patient record system (Dowsett et al, 2015; WUWHS, 2016a).

The concept was developed from a global anthropological study conducted in 2013–2014 with the aim of gaining a better understanding of the impact of a wound on the patient. A key finding from the study showed that clinicians and patients separated the wound into three distinct, yet interconnected areas.

The Triangle of Wound Assessment focuses on the wound bed, wound edge and periwound skin, each with significant importance in wound healing [Figure 1]. The wound bed is where clinicians seek to assess tissue type, manage exudate, prevent infection, reduce inflammation, remove devitalised tissue and promote granulation tissue formation. At the wound edge, the aim is to reduce the barriers to healing by debriding thickened and rolled wound edges, identifying areas of undermining and improving exudate management. For the periwound skin the aim is to protect the skin surrounding the wound from maceration, excoriation, dry skin, hyperkeratosis, callus and eczema.

Developing the Triangle of Wound Assessment for new challenges

New developments in wound care highlight the importance of preventing exudate pooling and reducing the dead space or 'gap' between the wound bed and the dressing, to avoid wound complications, such as maceration and biofilm formation and infection. Highly exuding wounds and wounds with undermining and a steep angle between the wound edge and wound bed are at a higher risk of dead space. The Triangle of Wound Assessment can be used to (Dowsett et al, 2018):

- Identify and assess the gap, and evaluate the impact of the interventions
- Measure wound depth as part of wound assessment
- Identify irregular wound bed topographies and cavities
- Identify areas of undermining.

The Triangle can also be adapted to incorporate new developments and new challenges in wound care, such as the gap challenge and biofilm prevention and management.

Defining the gap: 'dead space' between wound and dressing

An ulcer is a sore on the skin or mucous membrane, accompanied by the disintegration of tissue. Ulcers can result in complete loss of the epidermis and often portions of the dermis and even subcutaneous fat, fascia and muscles in deep pressure ulcers. In some wounds, the deeper structures are more damaged than the epidermis, which leads to an undermining of the wound edges. Since it has been shown that a moist environment is more conducive to healing than a dry or a wet ulcer bed, most ulcer treatment includes a dressing that keeps the ulcer bed moist. Most dressings cover not only the wound, but also the periwound skin; the dressing often firmly attached to the intact skin. As there is often a wound cavity, it can be difficult for a non-conforming dressing to ensure close contact to the wound bed. This results in a gap/dead space between the wound bed and the dressing.

Why is the wound gap an issue?

Many chronic ulcers are stuck in the inflammatory stage of healing and some are critically contaminated with bacteria. In this stage, the wound bed produces a moderate-to-high amount of wound fluid. If the dressing is not in contact with the wound bed, there will be a risk of pooling of wound fluid in the cavity. A high amount of cavity wound fluid will lead to a risk of leakage from the dressing, primarily from the lower part of the dressing due to gravity. The fluid is toxic to the skin and causes maceration and damage to the normal skin barrier. Maceration causes enhancement of the wound area and has a direct relationship with wound healing, prolonging the time it takes to heal (Haryanto et al, 2016). If the periwound skin is not protected, for example, with zinc paste or other protecting ointments, there will be a risk of damaging the wound further.

Another problem with exudate pooling between the wound and dressing is the risk of

infection. Wound exudate contains an excess number of enzymes and other substances that can inhibit the healing, as well as proteins that promote the growth of bacteria. Thus, pools of exudate promote bacterial growth, leading to increased risk of infection and subsequent development of biofilm. An optimal wound dressing should conform to the wound bed to manage the gap and reduce exudate pooling, creating a less favourable environment for biofilm to form.

Managing the gap challenge

When choosing a dressing for moisture management, the dressing should conform to the wound to reduce exudate pooling and have properties that absorb and retain wound fluid.

One way to avoid the wound gap is to use a contact layer or paste that can minimise the cavity. However, this can be an expensive treatment in terms of materials and nursing time required for frequent dressing change. The frequency of the dressing change will depend on the following requirements:

- Manufacturers recommendations of individual products
- Level and consistency of wound exudate
- Patient preferences and individual requirements
- Signs of acute or spreading infection
- Total fluid handling capacity of the chosen dressing
- Dressing ability to manage the gap and reduce exudate pooling by conforming to the wound bed
- Tertiary requirements such as graduated compression and pressure offloading.

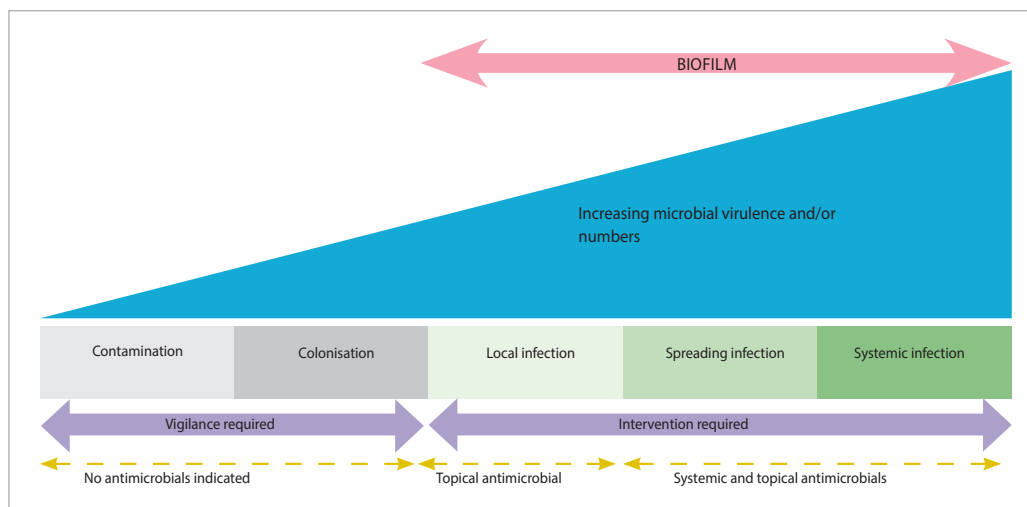
A more economic approach is to use a dressing with a high conformability where the primary dressing, due to its flexibility, is in contact with the wound bed and absorbs and retains the wound fluid in the dressing to avoid the formation of a gap and the risks associated with it.

Infection and biofilm

Diagnosing a wound infection, either planktonic (acute infection) or with presence of biofilm (chronic infection), is done through assessment of the clinical signs and symptoms and listening to the patient. A wound infection continuum provides the clinician with indications of clinical signs and symptoms, as well as indicators of when to commence topical and systemic antimicrobials [Figure 2].

Awareness of biofilm and the implications in wound management for many clinicians was

Figure 2. IWII wound infection continuum.



first raised in 2008 (Bjarnsholt et al, 2008; James et al, 2008) when publications emerged that not only was biofilm present in more than 60% of the chronic wounds, but also had a significant detrimental effect on wound healing. More recent studies (Malone et al, 2017) now suggest that the prevalence of biofilm in chronic wounds may be greater than 80%. Biofilms can be described as clusters of bacteria and fungi in a matrix, self-produced or of host origin (WUWHS, 2016b). Biofilms can be both surface attached and embedded in soft tissue, for instance those found embedded in the wound environment. There is some conflicting evidence in the literature regarding the negative impact of biofilms on wound healing, but there is growing consensus by international groups and scientists that biofilms can cause infection, inflammation and delayed wound healing (Bjarnsholt et al, 2008; James et al, 2008; International Wound Infection Institute [IWII], 2016; WUWHS, 2016b; Malone et al, 2017).

Biofilm are microscopic structures and can only be categorically confirmed using a specialised microscopy. Publications and studies to validate clinical signs of biofilm are welcomed but at present there is not enough evidence to provide consensus; a wound can appear clean and healthy but may have delayed healing due to biofilm being present in the deeper tissues. Debate in the literature is ongoing as to whether slough or gelatinous granulation tissue (slimy surface substances that reform in and on a wound) can be signs of presence of biofilm in the wound.

Biofilm can only be identified after obtaining a sample of wound tissue, following cleansing and debriding (curette or punch biopsy), which is sent to a laboratory with modern microscopy. Even so, as biofilms are heterogeneously

distributed within the wound, the results can strongly depend on where in the wound the biopsy is taken from (Bjarnsholt et al, 2008). A normal wound culture is deemed inadequate due to strong adherence of the biofilm and lack of equipment in normal pathology services (Schultz et al, 2017). However, if the clinician requires a culture for other reasons, such as to determine antimicrobial resistance, then recommendations are available on how to do a wound culture, e.g. using the Levine technique (IWII, 2016).

Using the Triangle of Wound Assessment to identify infection and biofilm

The Triangle of Wound Assessment assists in determining the condition of the wound bed, wound edge and periwound skin and is an excellent guide for assessment (Dowsett and von Hallern, 2017), including the identification of bioburden. Clinical assessment for signs and symptoms for secondary signs of infection or local infection are most relevant for a chronic wound [Table 1]. As previously stated, there is no validated clinical consensus for the signs and symptoms for biofilm, however, there is agreement that presence of one or more of the following signs are suggestive of biofilm:

- Lack of healing in a 'healable' wound that is not malignant
- Local signs of infection
- Not responding to antimicrobial substances.

Biofilm-based wound management

Reducing the level of biofilm can support optimal healing conditions in a wound. Management of suspected biofilm or chronic wound infection requires a multiple and holistic approach. Debridement and therapeutic wound

Table 1. Signs and symptoms of infection.

Local covert/secondary	Local overt/classic	Spreading/systemic
Unhealthy granulation tissue: friable, gelatinous, hypergranulated	Increased or change in pain	Redness/erythema >2 cm from wound edge
Stalled, delayed or non-healing wound	Warmth, redness < 2 cm from wound edge	Induration and oedema
Wound breakdown or enlargement	Change or increase in exudate. Odour, pus	Satellite lesions, dehiscence or further deterioration of the wound

cleansing are the cornerstone for wound bed preparation and create a window of opportunity for antimicrobials to act effectively. This removes non-viable tissue, crusting from desiccated wound edges and remnant dressing material, therefore allowing proliferation and migration of epithelial cells, disruption of biofilm and removal of excess exudate. There are many debridement options for clinicians [Box 1]. Post debridement care includes cleansing and application of an antimicrobial wound dressing (Schultz et al, 2017; Høiby et al, 2015).

Tips and tricks for managing bioburden

Assessing the wound at each wound dressing procedure will give opportunity to diagnose and treat a wound infection in the early stages, therefore, increasing the potential to prevent a limb or life threatening infection. Using appropriate aseptic technique to decrease inadvertent contamination and appropriate hand hygiene are relevant, and appropriate strategies to facilitate good wound management. Antimicrobials play an important part in wound care in the prevention and management of infection. It is important to note that antimicrobials should be used within antimicrobial stewardship practices and as part of an overall package of care. Modern wound products that are proactive in optimising the wound environment to decrease bioburden, decrease factors of inflammation, manage exudate and protect the periwound are available and should be used with knowledge and confidence.

Summary

The Triangle of Wound Assessment is a holistic and easy to use framework, that supports accurate and timely assessment of the wound bed, wound edge and periwound skin (Dowsett et al, 2015). Management goals can be set following this, along with selecting optimal treatment. Incorporating the framework into a holistic approach, also allows for wound assessment and reassessment as the status of the wound changes (Dowsett et al, 2015). All types

of wounds can be assessed in this way, with the ultimate goal of improving patient outcomes and promoting wound healing.

This well-established framework has also been shown to be essential in reducing the burden of the wound gap (Dowsett et al, 2018). As discussed in this article, maceration of the periwound skin is often caused by the gap between the dressing and the wound bed, which can lead to complications, such as infection and delayed healing. Use of the framework is able to guide treatment, so that appropriate dressings are selected that are able to conform to the wound bed, eliminate dead space, reduce exudate pooling and the risk of infection and biofilm. The Triangle of Wound Assessment can now be developed, with new concepts such as wound biofilm and the gap challenge incorporated into the overall assessment framework [Figure 3], aligned to exudate and infection prevention and management. Preventing biofilm formation by reducing exudate pooling can support optimal healing conditions in a wound. International best practice for promoting optimal healing conditions for infected wounds recommends to first cleanse and debride the wound, creating a window of opportunity for antimicrobials to act effectively (IWII, 2016; WUWHS, 2016b).

WINT

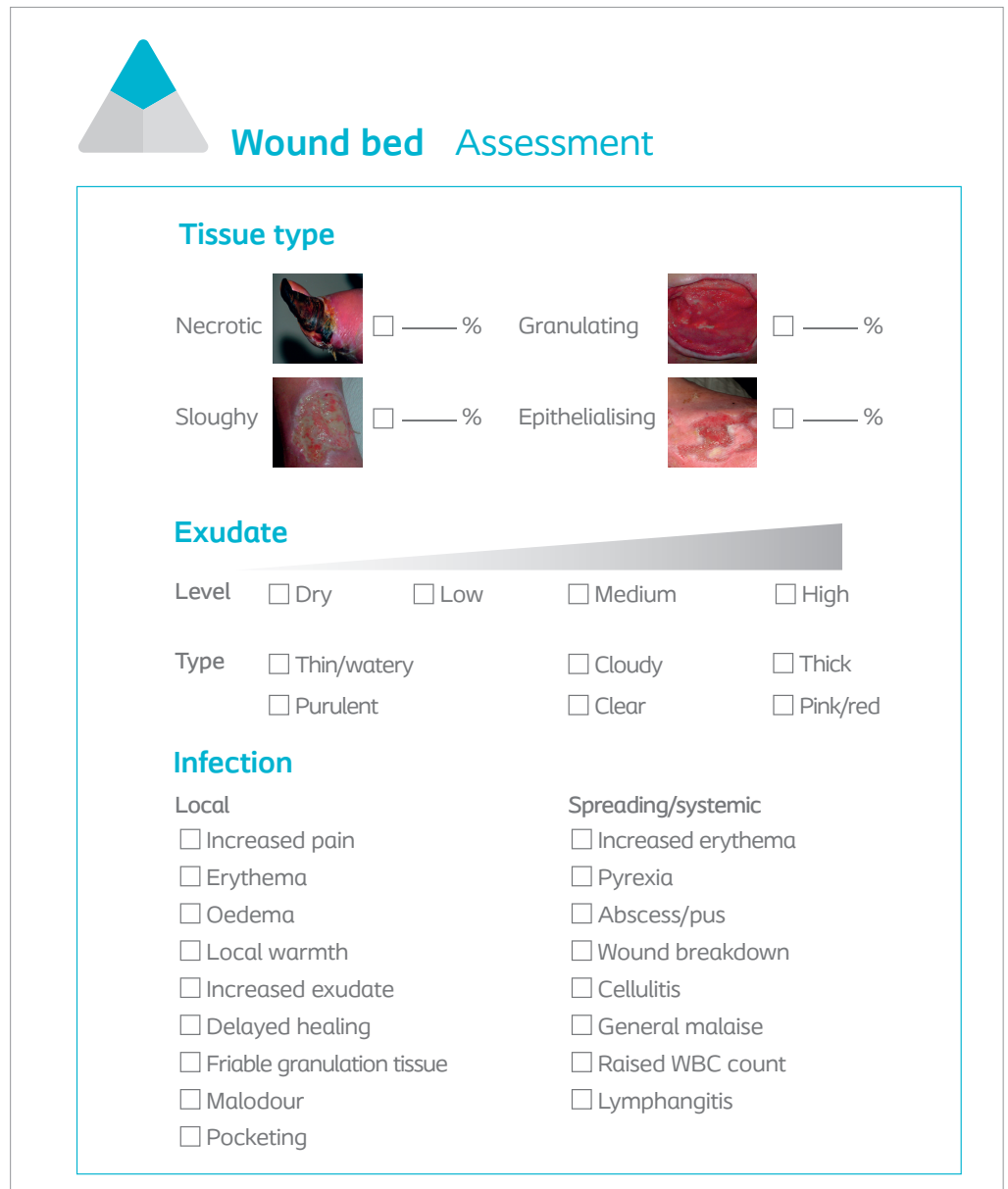
References

- Bjarnsholt T, Kirketerp-Møller K, Jensen PØ et al (2008) Why chronic wounds will not heal: a novel hypothesis. *Wound Repair Regen* 16(1): 2–10
- Cartier H, Barrett S, Campbell K et al (2014) Wound management with the Biatain Silicone foam dressing: a multicentre product evaluation. *Wounds International* 10(4): 26–30
- Cutting K, White R, Hoekstra H et al (2009) Topical silver impregnated dressings and the importance of the dressing technology. *Int Wound J* 6(5): 396–402
- Dowsett C, Protz K, Drouard M, Harding KG (2015) The Triangle of Wound Assessment Made Easy. *Wounds International*. Available at: <https://bit.ly/2L0Td8a> (accessed 27.08.2019)
- Dowsett C (2015) Breaking the cycle of hard-to-heal wounds: balancing cost and care. *Wounds International* 6(2): 17–21
- Dowsett C and von Hallern B (2017) The Triangle of Wound Assessment: a holistic framework from wound

Box 1. Debridement methods.

- **Conservative sharp wound debridement (CSWD):** use of scissors, forceps, curette or scalpel
- **Autolytic:** the body's own enzymes and moisture beneath a modern wound dressing liquefies non-viable tissue. Maintaining a balance in moisture is important
- **Mechanical:** use of technologies such as ultrasound, debridement pads or using a moistened gauze with aggressive cleansing
- **Biological:** use of sterile larvae
- **Enzymatic or chemical:** use of products with enzymatic properties, surfactants that assist with lifting or removing tissue and surface substance
- **Surgical:** For appropriately experienced clinicians who debride tissue down to healthy tissue, most commonly done in an operating theatre

Figure 3. Assessment framework to include how to assess the gap and suspicion of biofilm.



assessment to management goals and treatments. *Wounds International* 8(4): 34–9

Dowsett C, von Hallern B, Moura MRL (2018) Meeting report: The gap challenge in clinical practice how do you manage it? *Int Wound J* 9(3): 60–65

Guest JF, Ayoub N, McIlwraith T et al (2017) Health economic burden that different wound types impose on the UK's National Health Service. *Int Wound J* 14(2): 322–330

Haryanto H, Arisandi D, Suriadi S et al (2016) Relationship between maceration and wound healing on diabetic foot ulcers in Indonesia: a prospective study. *Int Wound J* 14(3): 516–522

Høiby N, Bjarnsholt T, Moser C et al (2015) ESCMID guideline for the diagnosis and treatment of biofilm infections 2014. *Clin Microbiol Infect* 21(1): S1–S25

International Wound Infection Institute (IWII) (2016) *Wound Infection in Clinical Practice*. Available at: <https://bit.ly/2WhwYC2> (accessed 27.08.2019)

James GA, Swogger E, Wolcott R et al (2008) Biofilms in chronic wounds. *Wound Repair Regen* 16(1): 37–44

Malone M, Bjarnsholt T, McBain AJ et al (2017) The prevalence of biofilms in chronic wounds: a systematic review and meta-analysis of published data. *J Wound Care* 26(1): 20–25

Schultz G, Bjarnsholt T, James GA et al (2017) Consensus guidelines for the identification and treatment of biofilms in chronic nonhealing wounds. *Wound Repair Regen* 25(5): 744–757

Snyder RJ (2005) Managing dead space: an overview. *Podiatry Management* 24: 171–4

World Union of Wound Healing Societies (WUWHS) (2016a) *Florence Congress, Position Document. Advances in wound care: the Triangle of Wound Assessment*. Available at: <https://bit.ly/2HQq5gK> (accessed 27.08.2019)

World Union of Wound Healing Societies (WUWHS) (2016b) *Florence Congress, Position Document. Management of Biofilm*. Available at: <https://bit.ly/2ZmUhvO> (accessed 27.08.2019)

Wounds UK (2018) *Best Practice Statement: Improving holistic assessment of chronic wounds*. Available at: <https://bit.ly/2u3VSUT> (accessed 27.08.2019)

Declaration

This article has been supported by an unrestricted educational grant by Coloplast A/S.