

ROUND TABLE REPORT

Consensus round table meeting: Portable topical oxygen therapy for healing complex wounds



Wounds
INTERNATIONAL

PUBLISHED BY:

Wounds International
108 Cannon Street
London EC4N 6EU, UK
Tel: + 44 (0)20 3735 8244
www.wounds-uk.com



© **Wounds International**
2018

This document has been developed by Wounds UK and supported by Inotec AMD Ltd

The views expressed are those of the authors and do not necessarily reflect those of Inotec AMD Ltd

How to cite this document:

Consensus round table meeting: Topical oxygen therapy for healing complex wounds. London: Wounds International, 2018. Available to download from: www.woundsinternational.com

FOREWORD

Oxygen is critical to wound healing. Lack of oxygen (hypoxia) can delay healing and increase the risk of complications.

In patients with comorbidities, their complex and chronic wounds are at increased risk of hypoxia, which means that healing is delayed, but may be corrected by early intervention with topical oxygen therapy.

NATROX® Oxygen Wound Therapy (Inotec AMD Ltd) is a portable medical device that has been clinically proven to deliver oxygen direct to the wound bed and have a positive effect upon healing.

A group of international experts met in May 2018 to discuss the use of topical oxygen therapy, and particularly NATROX, in practice. The aims of the meeting were to:

- Establish what is currently known about oxygen therapy, and where topical oxygen therapy fits into the current treatment landscape
- Develop recommendations for use of NATROX in practice
- Agree on clinical pathways for decision-making and using NATROX in complex wounds.

This resulting document aims to provide clinicians with the information they need to use NATROX appropriately in practice and improve outcomes in healing.

EXPERT WORKING GROUP

Chair: Breda Cullen, PhD RedC Consultant, UK
Abdulmohsen Ali Al Eisa, Consultant Surgeon, King Fahad Hospital, Hofuf, Saudi Arabia
Hanna Kaufman, Orthopaedic Surgeon, Israel
Joanne McCardle, Consultant Podiatrist, Salford Royal Foundation Trust, UK
Harikrishna K. Ragavan Nair, Consultant Wound Care Physician, Malaysia
Elia Ricci, Consultant Surgeon, Turin, Italy
Tang Tjun Yip, Consultant Vascular and Endovascular Surgeon, Singapore General Hospital, Singapore

REVIEW PANEL

Keith Harding, Medical Director, Welsh Wound Innovation Centre, Cardiff, UK; Dean of Clinical Innovation, Cardiff University, UK
Borripatara Wongprachum, Consultant Surgeon, Bangkok, Thailand
Ibby Younis, Consultant Plastic Surgeon and President, Plastic Surgery Section, Royal Society of Medicine, UK

CAUSES OF WOUND HYPOXIA

Wound hypoxia and the resulting delayed healing can be due to a variety of causes and is often multifactorial – e.g. the presence of multiple comorbidities and holistic health/lifestyle issues (Wounds UK, 2017).

This may be a result of a general, systemic lack of oxygen (e.g. if the patient is a smoker), or is often a result of reduced delivery of oxygen to tissues due to systemic or local disease (Sen et al, 2009; Schreml et al, 2010). Causes of reduced delivery of oxygen to wound tissues include:

- **Macrovascular disease** – e.g. reduced arterial blood flow due to peripheral arterial disease or reduced diffusion of oxygen through tissues due to oedema caused by venous disease (Sen et al, 2009; Schreml et al, 2010)
- **Microvascular disease** – e.g. capillary wall thickening and/or arteriovenous shunting with diabetes, fibrin deposition in chronic venous hypertension, vasculitis (Howard et al, 2013)
- **Systemic disease** – e.g. reduced arterial oxygen levels due to respiratory disease, heart disease or anaemia (Sen et al, 2009; Schreml et al, 2010)
- **Chronic wound inflammation** – non-healing wounds are stuck in a vicious cycle of increased inflammation, which in turn produces increased proteases, causing tissue degradation and stimulating further inflammation. An effect augmented by the presence of bacteria in biofilms. This chronic inflammatory state increases oxygen consumption by immune cells such as neutrophils and macrophages contributing to low wound oxygen levels (James et al, 2016).

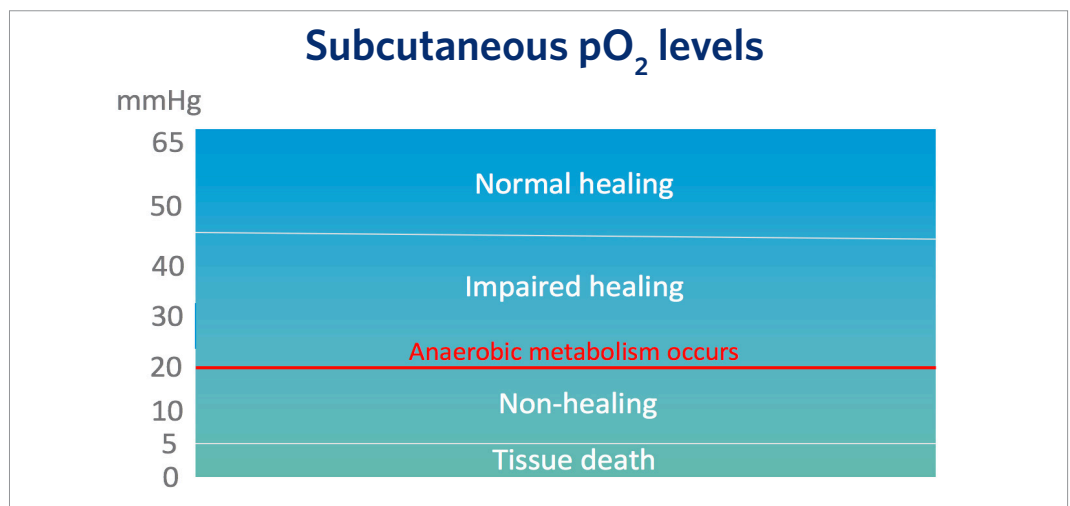
Other causes that may contribute to wound hypoxia can include cardiovascular disease, pulmonary fibrosis or pneumonia, sympathetic dysregulation, hypothermia, haemodynamic instability, Raynaud’s disease, the need for vapopressors or high altitude (Park et al, 2014).

OXYGEN LEVELS AND THEIR EFFECTS

In measuring both ‘normal’ and compromised oxygen levels in the skin, levels can be defined as follows:

- In normal skin, the oxygen levels 3–4 mm below the surface measure at approximately 45–65 mmHg (Howard et al, 2013).
- Tissue in chronic hypoxic wounds have been found to have oxygen levels of 5–20 mmHg (Schreml et al 2010), and can be as low as 0–5 mmHg in central devascularised regions (Howard et al, 2013).
- At oxygen levels below 20 mmHg, cells in the wound convert to anaerobic metabolism, which slows the processes of healing (Howard et al, 2013; see Figure 2).

Figure 2: The effects of oxygen levels



Furthermore, research has found that higher than usual oxygen levels can enhance some processes critical for wound healing and suggests that increased oxygen may increase the rate of healing:

- It is long-established that prolyl hydroxylase (a key enzyme for skin collagen production) is at maximal activity at oxygen levels of around 250 mmHg (Hutton et al, 1967).
- Fibroblast proliferation and protein production are maximal at oxygen levels of 160 mmHg (Howard et al, 2013).

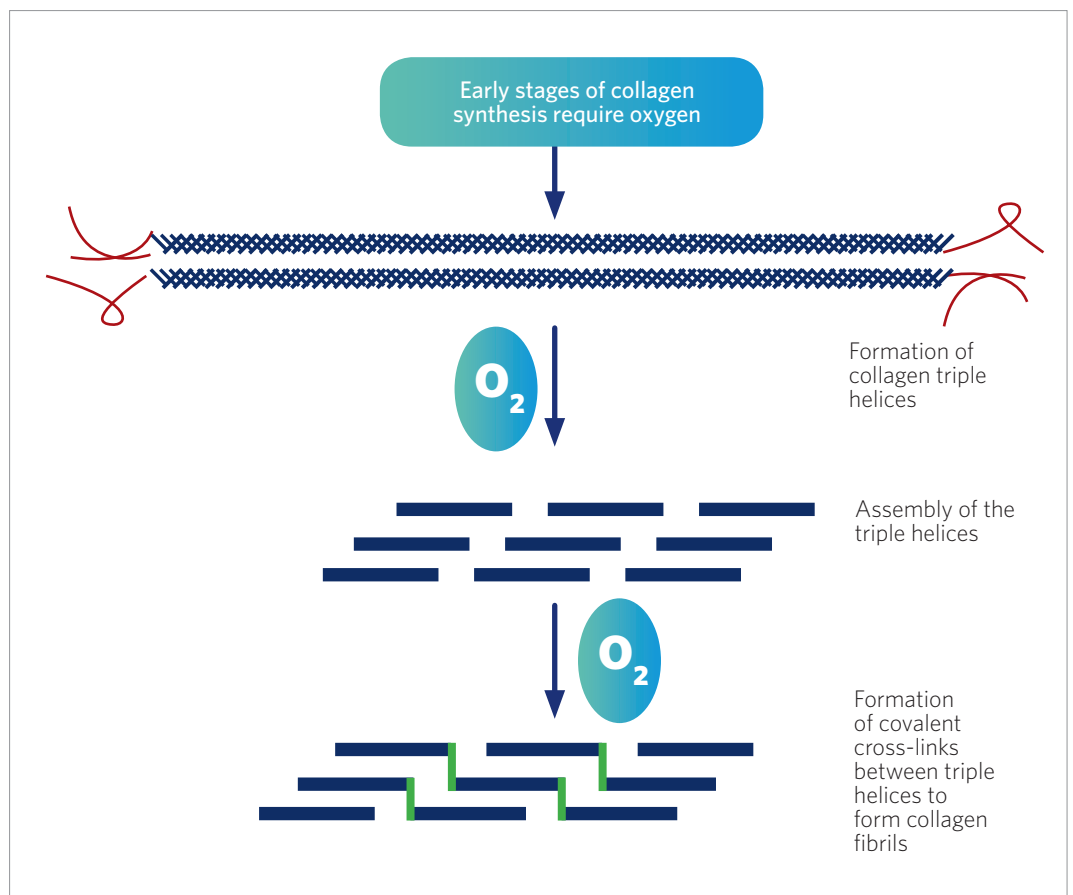
COLLAGEN PRODUCTION AND QUALITY OF HEALING

In addition to stimulating and expediting the processes of healing, higher oxygen levels also contribute to the quality of healing, through their influence on collagen production (Kominsky et al, 2010).

Collagen is the skin's primary component, accounting for 70–80% of its dry weight and acting as the 'structural scaffold' of the skin. Collagen is made up of fibres, which form 'bundles' like the strands in a rope and are interwoven like fabric, enabling them to be stretched in multiple directions (Hunt, 1990).

Multiple enzymes are involved in collagen production, all of which are dependent on oxygen (Gordillo and Sen, 2003). As well as supporting levels of collagen production, higher oxygen concentrations have also been found to improve the tensile strength and quality of the collagen produced, thus improving the quality of healed tissue (Figure 3).

Figure 3: Oxygen and collagen synthesis (Adapted from Sen, 2009; Shoulders and Raines, 2009)



Angiogenesis is connected to the formation of good-quality collagen. The rate of angiogenesis is directly proportional to oxygen levels in injured tissues and rates of collagen deposition also increase proportionally with oxygen levels (Hopf et al, 2005). Collagen formed in a hypoxic environment has been found to be only 30% as strong as collagen formed in normal or higher oxygen concentrations (Kominsky et al, 2010). This has a significant effect on the quality of healed skin and on rates of recurrence in skin breakdown.

OXYGEN AND INFECTION

Hypoxia is associated with an increased risk of wound infection (Eisenbud, 2012). This is in part due to the issue of stalled healing and chronicity increasing infection risk, and also the impaired oxygen-dependent antibacterial processes caused by hypoxia (Eisenbud, 2012).

Oxygen is essential to the respiratory burst needed for microbe clearance (Wang et al, 2007). This increased potential for the wound to become infected, augments the vicious circle of stalled healing and increases the risk of further complications (Eisenbud, 2012).

Maximal antibacterial action due to the respiratory burst occurs at oxygen levels greater than 300 mmHg (Allen et al, 1997). Such high levels can only be achieved through the use of supplemental oxygen, indicating that oxygen therapy can accelerate antibacterial action, which may be useful in all wounds at risk of infection and/or chronicity (Wounds UK, 2017).

Oxygen therapy in wound healing

Improving tissue oxygenation has long played an important role in wound healing. Traditionally, macrovascular issues have been corrected via arterial bypass surgery, or endovascular interventions such as angioplasty or stenting. However, these procedures carry significant morbidity and occasionally mortality risk, and many patients with chronic and complex wounds have comorbidities and risk factors that do not make them ideal candidates for surgery (Slovutz & Lipsitz, 2012; Sinha et al, 2014). Anecdotal evidence from global clinicians suggests that suitability may vary across geographical areas – e.g. revascularisation tends to be difficult in the Asian population due to small vessels.

Additionally, while these interventions primarily improve flow in larger arteries, they cannot overcome the microvascular disease that is often the cause of poor tissue oxygenation in chronic wounds, which tends to be associated with diabetes and chronic venous hypertension (Forsythe et al, 2014; Wollina et al, 2006).

Pharmacological interventions may also be useful in aiming to improve blood supply and oxygenation – such as the vasodilator iloprost; however, such systemic treatments are associated with potential side effects and may require short-term hospitalisation (Abdulhannan et al, 2012). Therapies may also be used that deliver topical nitric oxide to cause vasodilation, which can work well in healthy vessels but is likely to be more problematic when the vessels are diseased or absent, which means the vasculature cannot be physically dilated (Del Rosso & Kircik, 2017).

However, more recently, advances and improved methods of delivery have widened access to oxygen therapy, facilitating more effective treatments and making the use of oxygen more feasible in practice (Wounds UK, 2017).

HYPERBARIC OXYGEN

'Hyperbaric' means 'higher pressure', which in practice involves delivering systemic oxygen to the patient via a high-pressure chamber. Hyperbaric oxygen therapy was first used as a wound care treatment following the discovery that patients with burns receiving hyperbaric oxygen therapy for carbon monoxide poisoning healed more quickly (Wada et al, 1965).

Hyperbaric oxygen therapy is used in specialist centres, as it is not portable and therefore not suitable for home or community use. Furthermore, hyperbaric oxygen therapy assumes the microvasculature is sufficient to carry oxygen to the wound site. However, in chronic wounds often poor microvasculature is the cause of low oxygen levels in the limb. Topical oxygen therapies have since been developed, but it should be noted that topical and systemic oxygen therapies should be viewed as separate, and potentially complimentary to each other, rather than purely as alternatives.

TOPICAL OXYGEN

More recently localised methods of oxygen delivery have been developed. These initially included localised treatments such as pressurised oxygen cylinders connected to a chamber or bag that surrounds the area of the wound, which were found to be a useful advance in treatment (Tawfick & Sultan, 2009).

PORTABLE CONTINUOUS OXYGEN

Since then, developments in portable continuous oxygen therapy and the associated delivery modes have represented a significant advance in therapies available and have made the practicality of oxygen treatments available to patients in a larger range of care settings.

Key benefits of portable continuous oxygen therapy in practice

- Oxygen delivered independent of wound microcirculation
- Sustained delivery
- Low risk of toxicity
- Portable
- Easy to use
- Less expensive/potential for cost savings

New systems such as NATROX Oxygen Wound Therapy provide a more practical and patient-friendly mode of delivery for oxygen therapy, as it is small, lightweight and portable (around the size of a mobile phone), allowing continuous oxygen therapy to be delivered directly to the wound (Wounds UK, 2017).

Introducing NATROX

NATROX Oxygen Wound Therapy is an innovative, simple and lightweight device that delivers 98% pure humidified oxygen direct to the wound bed.


NATROX provides portable continuous oxygen therapy, whereby total contact oxygen delivery is possible in a format that is practical and easy for the patient to use. The device provides an active therapy, which can be maintained 24 hours a day, 7 days a week, until the wound achieves complete re-epithelialisation.

The treatment is low-risk and easy to implement in practice, so should be considered for use in suitable wounds at risk of delayed healing and increased chronicity and/or complexity.

HOW NATROX WORKS

The NATROX Oxygen Therapy System comprises an oxygen generator and oxygen delivery system (Figure 4). The device contains two interchangeable, rechargeable batteries, which operate an oxygen concentrator that generates 98% oxygen through the electrolysis of water that is naturally present in the atmosphere.

Figure 4: The NATROX device



The oxygen that is generated is delivered at a rate of approximately 13 ml per hour through a fine, soft tube to the specially designed oxygen distribution system, which is placed over the wound and delivers the oxygen directly to the wound bed. The oxygen then diffuses evenly and continuously across the wound surface while the device is in operation.

THE BENEFITS OF NATROX

Clinical evidence has shown that NATROX has a positive effect on healing, particularly in challenging and non-healing wounds (Wounds International, 2018).

In a study of DFUs, NATROX was found to significantly improve healing rates (Yu et al, 2016). After 8 weeks of treatment, 30% of the control group healed, compared to 90% healing in the NATROX arm.

A study by Kaufman et al (2018) found that 57% of DFUs and arterial ulcers completely healed when treated for longer than 25 days. Hayes et al (2015) also observed a 53% reduction in wound size after 8 weeks of treatment, with 7/10 DFUs on a healing trajectory.

A recent case study by Jones et al (2016) presented an extremely challenging DFU, which had failed to heal in 10 months despite receiving optimal standard of care. Following the introduction of NATROX, the wound achieved full re-epithelisation in just 10 weeks. This case demonstrated not just the clinical benefits of NATROX therapy but also the health economic benefits. The authors estimated the cost saving made by utilising NATROX compared to previous treatment was in the region of £3,707. This included the additional costs of purchasing NATROX.

A further study by Jones et al (2017) used NATROX in challenging, non-healing DFUs that had been present for more than 6 months (mean duration 17 months). Complete healing was achieved in 33 of the total cohort (42 patients) and a further 50% reduction in wound surface area was observed in the non-healing group.

Across the studies, NATROX was shown to be well tolerated by patients and to encourage a high level of concordance, due to the practicality of the device. In particular, patients expressed high levels of satisfaction with the device (Kaufman et al, 2018; Jones et al, 2017). Additionally, pain scores were found to reduce (Mani, 2010) and no adverse events were recorded.

MANAGING CHALLENGING WOUNDS

NATROX can be used as an adjunct therapy, in addition to first-line therapies or when standard of care has failed and the wound has become stalled, chronic or complex.

However, a need has been identified for more proactive treatment pathways that trigger earlier treatment and thus reduce complications from arising, saving clinician time and resource by doing so. NATROX should not be seen as a 'last resort' when other treatments have not succeeded and the wound has been allowed to become chronic and/or complex.

Advanced therapies are needed, as healing rates under standard of care are often poor; 'gold standard' treatment in reality is just minimally acceptable treatment (Fletcher et al, 2017).

Many patients may have multiple risk factors, and NATROX is a low-risk, well tolerated treatment that is easy to implement in practice, so should be used earlier in the treatment pathway where possible and appropriate.

See below for a checklist of key factors that may indicate an 'at-risk' wound where early treatment with NATROX may be beneficial.

Patient risk factors where early treatment with NATROX should be considered

- Patient's age
- Smoking status
- Nutritional status
- Comorbidities
- Medication/polypharmacy issues

Focus on peripheral arterial disease

Patients with diabetes are twice as likely to have peripheral arterial disease (PAD) as those without diabetes (Wounds International, 2013). This has a significant impact on the outcomes of DFU treatment and is associated with the most severe adverse outcomes, including:

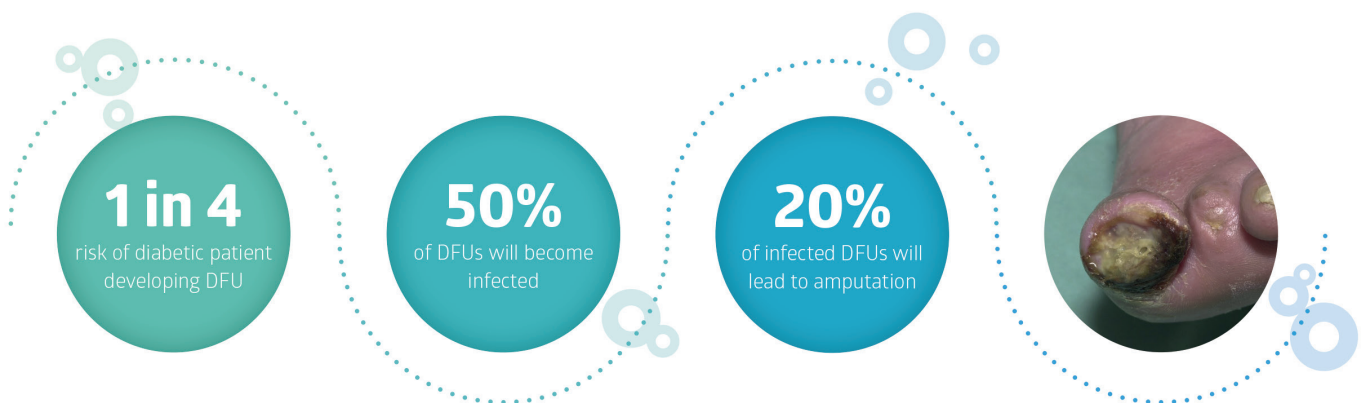
- Lower probability of healing
- Longer healing times
- Higher probability of recurrence
- Greater risk of toe as well as major amputations
- Potentially higher mortality (Armstrong et al, 2011)

Need for further advanced therapies may be determined by reduction in wound area over the period of treatment, which should act as a good indicator of whether standard of care is working. If not, advanced therapies need to be initiated.

If the wound hasn't progressed to healing (or significantly reduced in size - e.g. by 40-50%) within 4 weeks with standard of care treatment, advanced therapies such as topical oxygen should be considered.

The ideal advanced therapy needs to:

- Stimulate wound healing
- Be practical and easy to use
- Improve patient outcomes and quality of life

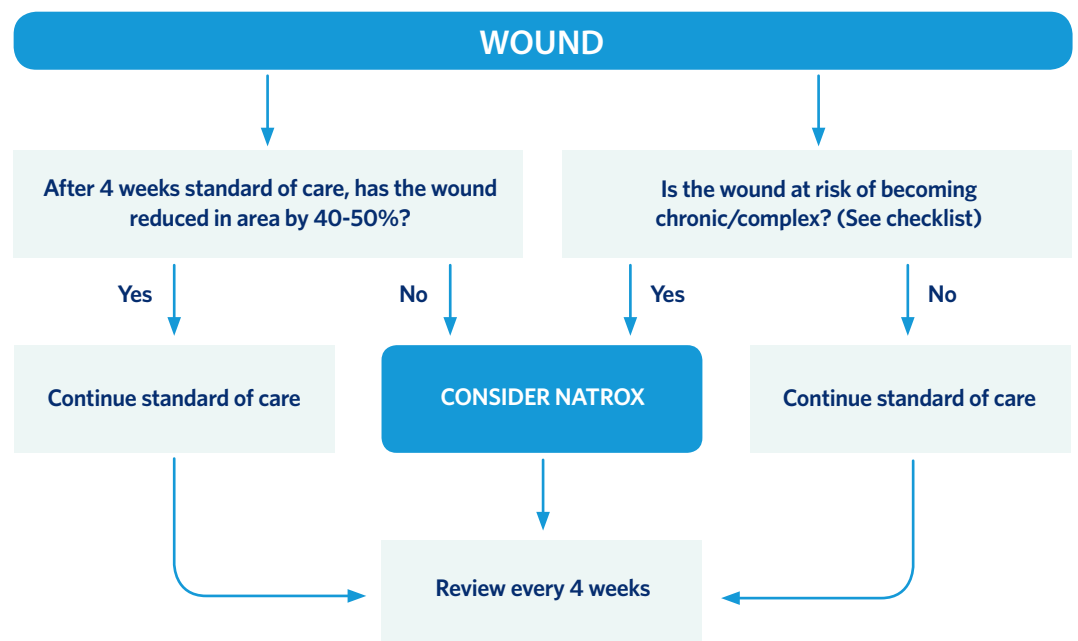


Treatment pathway in practice

The expert group devised a recommended treatment pathway to facilitate appropriate and timely use of NATROX Oxygen Wound Therapy in practice.

Prior to commencing treatment, assessment is key. A thorough holistic assessment of both patient and wound is vital, and every wound should have a vascular assessment prior to topical oxygen therapy.

It is also important to establish goals at the start of treatment – e.g. wound closure, wound area reduction, improved patient quality of life.



Ongoing assessment and monitoring is also key to successful treatment. Treatment should be reviewed at least every 4 weeks and, if sufficient progress is not being made, treatment options reassessed on an ongoing basis.

TIPS FOR USE IN PRACTICE

- NATROX may be used in conjunction with compression therapy, although care should be taken in positioning the device to avoid pressure when using under compression
- It is vital to properly prepare the wound before treatment via a structured wound bed preparation regimen (e.g. TIME; Dowsett & Newton, 2005) in order to ensure the wound is adequately debrided and minimal necrotic tissue is present, and to facilitate full contact between the device and the wound bed
- Appropriate dressing choice should also be considered alongside NATROX in order to get the best results and outcomes for the individual wound

- NATROX should not be used in conjunction with creams or similar topical treatments, as these can act as a barrier to oxygen absorption
- After the wound has closed, it can be useful to consider continuing treatment for a short duration to ensure that the skin has fully healed and to reduce risk of recurrence – it may be helpful to use the Leg Club model, which does not classify a wound as officially ‘healed’ until 2 weeks after wound closure, due to the fragility of the healed tissue (Lindsay, 2004). The Leg Club model relates to venous leg ulcers, but the concept may also be helpful in other chronic wound types.

What to expect from using NATROX treatment in practice

- The wound may initially increase in size, before becoming smaller and progressing to closure (i.e. in first 2 weeks of treatment)
- Exudate levels may initially increase in the early stages of treatment (i.e. in first 2 weeks), before decreasing
- Evidence has indicated that NATROX should ideally be used for 25 days or more as this time may be needed to kickstart healing, depending on the individual patient (Kaufman et al, 2018)
- NATROX may help to improve the patient’s pain levels

When not to use NATROX

NATROX should not be used in patients with the following:

- Malignant or potentially malignant wounds
- Wounds being treated with topical ointments or creams
- Unexplored deep sinus wounds or tracts
- Necrotic wounds
- Untreated osteomyelitis

Do not use in patients with known hypersensitivities to any of the components of this system

Discontinue if signs of sensitivity appear

Patient involvement

NATROX represents a patient-friendly development that encourages concordance by providing a practical solution that fits in with the patient's everyday lifestyle (Wounds UK, 2017).

The NATROX device is around the same size as a mobile phone, meaning it is portable and lightweight so can easily be used while carrying out everyday activities. It can be worn under clothing during the day, and positioned comfortably for use at night.

In case studies, NATROX has been well tolerated by patients and they have reported high levels of satisfaction with their treatment (Kaufman et al, 2018; Mani, 2010). Additionally, DFU patients reported high levels of satisfaction on the visual analogue scale, of 8.7 (Jones et al, 2017).

Encouraging concordance in patients as much as possible, in order to obtain the best results, helps to improve patient outcomes and encourage healing. As patients can use NATROX in the home care setting, involving them in their treatment where possible is key to patient concordance and empowerment.

While not all patients may be suitable for managing their own care, the device is simple to use, so suitable patients should be educated to manage their own care where possible. Patients can be taught how to apply the device (Figure 5) and to deal with issues such as changing the battery themselves (Figure 6).

Patients should be prepared for what to expect from their treatment, in order to manage expectations and optimise outcomes. Involving patients in their own care has been found to improve their experience and satisfaction with treatment, as well as to yield enhanced clinical and economic benefits (Moore, 2016).

Practical and economic benefits are associated with the reduced need for clinician time and the correct and efficient use of resources. Encouraging patient concordance can also encourage and expedite healing and improve overall outcomes.

As well as being educated about how to get the most out of their treatment with NATROX, patients can be involved in other aspects of their wound healing and skin health, such as an overall skin health regimen to preserve skin integrity and prevent recurrence, or in proper footwear choices in the case of DFUs, or compression therapy in venous leg ulcers.

Tips for establishing patient involvement (adapted from Moore, 2016)

- Establish the patient's level of insight into their specific wound problem/condition
- Establish the patient's expectations of the healthcare practitioner and of their individual treatment
- Establish the level of social support the patient has
- Outline the model of care employed, emphasising the central role of patient involvement
- Establish the patient's willingness/ability to be involved in their care
- Set realistic, achievable goals and establish good follow-up communication and support. Patients who are committed are more likely to follow the care plan

CLINICIAN USE – APPLICATION

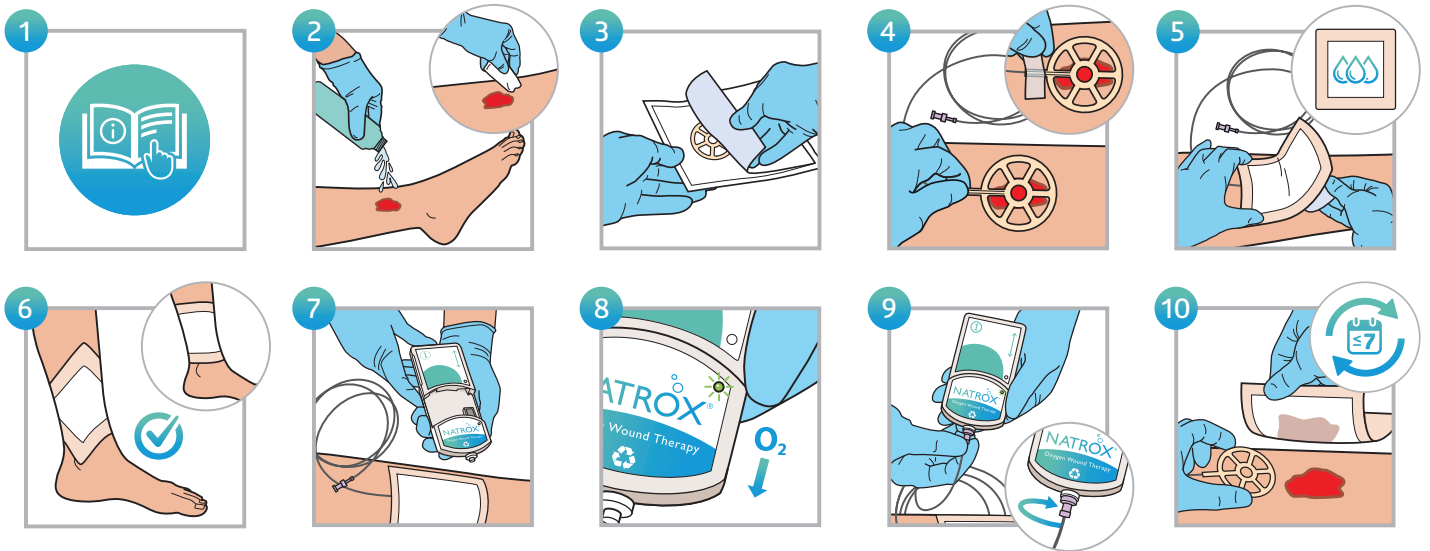


Figure 5: How to apply NATROX

PATIENT USE – BATTERY CHANGE & CHARGE

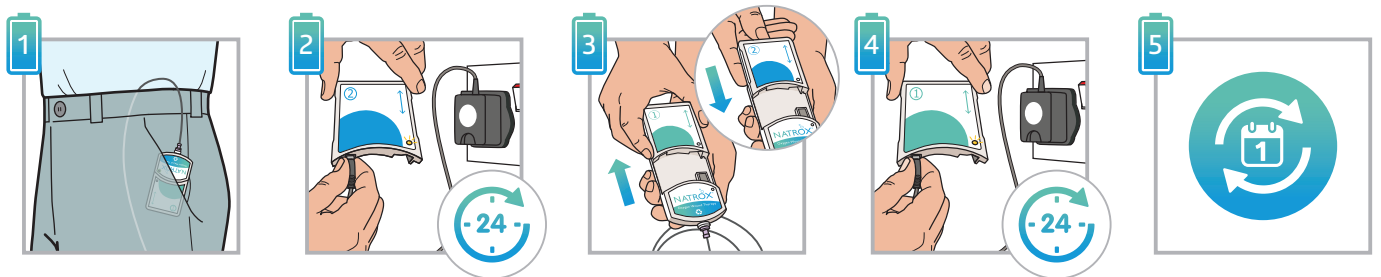


Figure 6: How to change and charge the battery

Case studies

Case study 1

AUTHOR: HARIKRISHNA K. RAGAVAN NAIR

HISTORY

A 58-year-old male presented with a non-healing wound of more than 3 months' duration, despite long-term antibiotic therapy and a good standard of care. His medical history included non-insulin dependent diabetes and neuropathy. The patient initially presented with ulceration on the first hallux of the right foot, which deteriorated quickly, resulting in severe infection and osteomyelitis leading to a Ray amputation. He went on to develop a post-surgical haematoma, which was surgically removed and antibiotics were initiated.

NATROX OXYGEN WOUND THERAPY

Due to the lack of progress and the likelihood of ongoing wound hypoxia, owing to small vessel disease, chronic inflammation and neuropathy, NATROX Oxygen Wound Therapy was initiated. On commencement (Figure 1) the wound measured 6.5 x 5.8 cm. There were no obvious signs of infection and the wound bed was free from any slough or necrosis. After 4 weeks of therapy, the wound had made significant progress (Figure 2), reducing in size, with only three small ulcerated areas evident. After 6 weeks of NATROX therapy, the wound was completely healed (Figure 3) with minimal scarring. NATROX was a highly effective and well-tolerated therapy for this particular wound and delivered excellent results in a very short space of time.

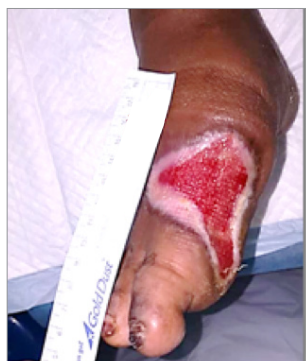

Figure 1: Start of treatment

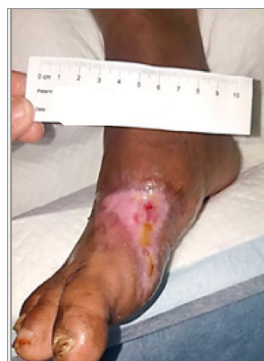

Figure 2: At 4 weeks

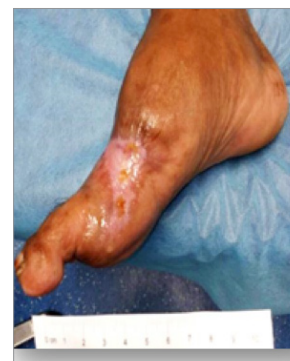

Figure 3: At 6 weeks

Case study 2

AUTHOR: KEITH HARDING

HISTORY

The patient was female, with type 1 diabetes and a previous right below-knee amputation. She also had peripheral arterial disease and a history of angioplasty. She presented with an indolent plantar diabetic foot ulcer of 6 months' duration following multiple amputation of toes.

NATROX OXYGEN WOUND THERAPY

NATROX Oxygen Wound Therapy was commenced with with the goal to stimulate wound healing. On commencement (Figure 1) the wound measured 2.5 cm x 2.5 cm. Treatment continued until the wound had reached healing (Figure 2). On review, the wound had achieved over 98% re-epithelialisation. Treatment with NATROX was discontinued after 16 weeks. This case showed excellent results in post-surgical diabetic foot wounds, as part of an RCT conducted in Cardiff, comparing the use of NATROX Oxygen Wound Therapy with standard care.

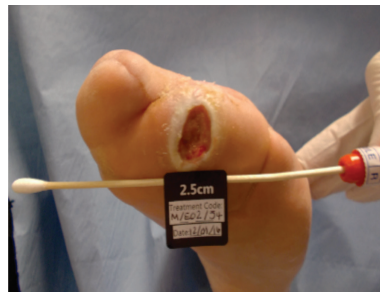


Figure 1: Start of treatment

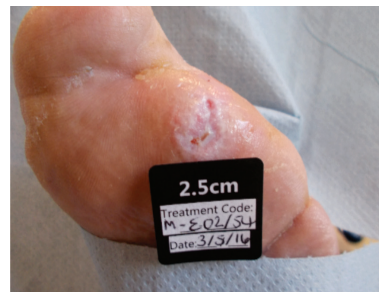

Figure 2: At 16 weeks

Summary

NATROX therapy is a simple and well tolerated therapy for patients to manage in the home care setting. Its potential for use in challenging and previously non-healing wounds offers both clinical and patient benefits, as well as associated economic benefits (Wounds International, 2018).

The need has been identified for use of advanced therapies in addition to standard of care, and for their proactive use earlier in the treatment pathway. Topical oxygen therapy has been proven to be beneficial and improve outcomes in suitable patients and their wounds, and there is scope for this treatment to be used on at-risk patients as well as those whose wounds have not achieved expected healing via standard of care.

In complex and chronic wounds, and patients with comorbidities, the elevated risk of hypoxia means that healing may be optimised by early intervention with topical oxygen therapy. NATROX in particular represents a significant advance in the delivery of topical oxygen therapy, enabling this to be facilitated in suitable patients in a practical and timely manner that will improve outcomes.

References

- Abdulhannan P, Russell DA, Homer-Vanniasinkam S (2012) Peripheral arterial disease: a literature review. *Br Med Bull* 104: 21-39
- Allen DB, Maguire JJ, Mahdavian M et al (1997) Wound hypoxia and acidosis limit neutrophil bacterial killing mechanisms. *Arch Surg* 132: 991-6
- Armstrong DG, Cohen K, Courric S et al (2011) Diabetic foot ulcers and their recurrence. *New England J Med* 376: 2367-75
- Castilla DM, Liu Z-J, Velazquez OC (2012) Oxygen: implications for healing. *Adv Wound Care* 1(6): 225-30
- Chadwick P, McCardle J, Mohamud L (2015) Appropriate use of topical haemoglobin in chronic wound management: consensus recommendations. *Wounds UK*, EWMA Special, 30-5
- Del Rosso JQ, Kircik L (2017) Spotlight on the use of nitric oxide in dermatology: what is it? What does it do? Can it become an important addition to the therapeutic armamentarium for skin disease? *J Drugs Dermatol* 16 (suppl 1): s4-10
- Demling RH (2009) Nutrition, anabolism, and the wound healing process: An overview. *Eplasty* 9: e9
- Dissemmond J, Kroeger K, Storck M et al (2015) Topical oxygen wound therapies for chronic wounds: a review. *J Wound Care* 24(2): 53-63
- Dowsett C, Newton H (2005) Wound bed preparation: TIME in practice. *Wounds International* 1(3): 58-70
- Eisenbud DE (2012) Oxygen in wound healing: Nutrient, antibiotic, signalling molecule and therapeutic agent. *Clin Plastic Surg* 39: 293-310
- Fagher K, Katzman P, Londahl M (2018) Transcutaneous oxygen pressure as a predictor for short-term survival in patients with type 2 diabetes and foot ulcers: a comparison with ankle-brachial index and toe blood pressure. *Acta Diabetol* 55(8): 781-8
- Fletcher J, Reuterhagen L, Ousey K, Berg L (2017) No compromise on quality: is 'good enough' really good enough? *Wounds International* 8(3): 30-3
- Forsythe RO, Brownrigg J, Hinchliffe J (2014) Peripheral arterial disease and revascularisation of the diabetic foot. *Diabetes, Obesity & Metab* 17: 435-44
- Gordillo GM, Sen CK (2003) Revisiting the essential role of oxygen in wound healing. *Amer J Surg* 186: 259-63
- Hayes P, Lee H, Curran G, Loftus I (2015) Topical oxygen therapy helps healing of diabetic foot ulcers. Poster presented at Canadian Association of Wound Care (CAWC) Conference, Toronto

- Howard MA, Asmis R, Evans KK, Mustoe TA (2013) Oxygen and wound care: A review of the current therapeutic modalities and future direction. *Wound Rep Regen* 21: 503-11
- Hunt TK (1990) Basic principles of wound healing. *J Trauma* 30: S122-8
- Hutton J, Tappel A, Udenfried S (1967) Cofactor and substrate requirements of collagen proline hydroxylase. *Arch Biochem Biophys* 118: 231-40
- James GA, Ge Zhao A, Usui M et al (2016) Microsensor and 16 transcriptomic signatures of oxygen depletion in biofilms associated with chronic wounds. *Wound Repair Regen* 24(2): 373-83
- Jones NJ, Curran G, Ivins N et al (2016) An economic evaluation comparing the cost of NATROX therapy versus standard care in the management of diabetic foot ulceration. Poster presentation
- Jones NJ, Curran G, Ivins N et al (2017) The role of topical oxygen therapy in the treatment of diabetic foot ulceration. Poster presentation
- Kaufman H, Gurevich M, Tamir E et al (2018) Topical oxygen therapy stimulates healing in difficult, chronic wounds: a tertiary centre experience. *J Wound Care* 27(7): 426-33
- Kominsky DJ, Campbell EL, Colgan SP (2010) Metabolic shifts in immunity and inflammation. *J Immunol* 184(8): 4062-8
- Lindsay E (2004) The Lindsay Leg Club Model: a model for evidence-based leg ulcer management. *Br J Community Nurs Suppl* 1: S15-20
- Mani R (2010) Topical oxygen therapy for chronic wounds: a report on the potential of NATROX, a new device for delivering enriched oxygen to chronic wounds. *J Wound Technol* 9: 28-30
- Moore Z (2016) Patient empowerment in wound management. *Wound Essentials* 11(1): 32-5
- Park N, Allen L, Nametka M, Driver VR (2014) Healing hypoxic wounds: fighting an uphill battle. *Lower Extrem Rev*. Available online at: <http://lermagazine.com/article/healing-hypoxic-wounds-fighting-an-uphill-battle> (accessed 28.06.2018)
- Schreml S, Szeimies RM, Prantl L et al (2010) Oxygen in acute and chronic wound healing. *Br J Dermatol* 163(2): 257-68
- Sen CK (2009) Wound healing essentials: let there be oxygen. *Wound Repair Regen* 17(1): 1-18
- Shoulders MD, Raines RT (2009) Collagen structure and stability. *Annu Rev Biochem* 78: 929-58
- Sinha S, Karthikesalingam A, Poloniecki JD et al (2014) Inter-relationship of procedural mortality rates in vascular surgery in England. *Circulation: Cardiovascular Quality and Outcomes* 7: 131-41
- Slovut DP, Lipsitz EC (2012) Surgical technique and peripheral arterial disease. *Circulation* 126: 1127-38
- Tawfick WA, Sultan S (2009) Does topical wound oxygen (TWO2) offer an improved outcome over conventional compression dressings (CCD) in the management of refractory venous ulcers (RVU)? A parallel observational comparative study. *Eur J Endovasc Surg* 38(1): 125-32
- Wang Z, Hasan R, Firwana B (2016) A systematic review and meta-analysis of tests to predict wound healing in diabetic foot. *Journal of Vascular Surgery* 63(2): S29-36
- Wang Y, Zeigler MM, Lam GK et al (2007) The role of the NADPH oxidase complex, p38 MAPK, and Akt in regulating human monocyte/macrophage survival. *Am J Respir Cell Mol Biol* 36: 68-77
- Wollina U, Abdel-Naser MB, Mani R (2006) A review of the microcirculation in skin in patients with chronic venous insufficiency: the problem and the evidence available for therapeutic options. *Int J Lower Extrem Wounds* 5(3): 169-80
- Wounds International (2013) International best practice guidelines: Wound management in diabetic foot ulcers. Available at: http://www.woundsinternational.com/media/best-practices/_/673/files/dfubestpracticeforweb.pdf (accessed 7.8.2018)
- Wounds International (2018) Challenging wounds, improving outcomes: Treatment of complex diabetic foot wounds using topical oxygen therapy. Available online at: <http://www.woundsinternational.com/case-studies/view/challenging-wounds-improving-outcomes-treatment-of-complex-diabetic-foot-wounds-using-topical-oxygen-therapy> (accessed 12.06.2018)
- Wounds UK (2017) Consensus round table meeting: Clinical pathway for using topical oxygen therapy in practice. Available online at: <https://www.wounds-uk.com/resources/details/consensus-round-table-meeting-clinical-pathway-using-topical-oxygen-therapy-practice> (accessed 12.06.2018)
- Yip WL (2015) Influence of oxygen on wound healing in diabetic foot ulcers. *J Vasc Surg* 24(6): 1536
- Yu J, Lu S, McLaren A-M et al (2016) Topical oxygen therapy results in complete wound healing in diabetic foot ulcers. *J Vasc Surg* 24(6): 1066-72

