

## Remove barriers to healing: Focus on wound bed preparation

### Authors:

Axel Kramer, Jan Stryja, Thomas Haeni and Luxmi Mohamud

This article is based on a symposium held at the European Wound Management Association (EWMA) conference in Krakow on 10th May 2018, which was sponsored by B.Braun. The focus of the symposium was on the importance of wound bed preparation and how this can be optimised to improve healing outcomes.

**W**ound bed preparation (WBP) describes a complex tool to achieve wound closure quickly and effectively, based on step-by-step approach. The two fundamental elements of any WBP regimen should be cleansing and debridement. Optimising these processes in practice has been proven to have a beneficial effect on both healing outcomes and patient quality of life.

Firstly, Professor Axel Kramer (Institute of Hygiene and Environmental Medicine, University of Medicine Greifswald, Germany) delivered a presentation summarising the recent consensus document published on the topic of antimicrobial agents (Kramer et al, 2018).

He spoke about the importance of antimicrobial agents and explored the properties of the ideal agent to use in wound cleansing. In critically colonised chronic wounds, or infected acute and chronic wounds, using an appropriate cleansing solution is vital, and can also be part of preparation for debridement.

The principle requirement in identifying the ideal antimicrobial agent is striking the correct balance of efficacy versus tolerability.

In terms of tolerability, it is useful to remember: 'do not apply anything to a chronic wound that you would not put in the eyes'. This reflects the importance of 'selective antimicrobial action' — an antimicrobial agent that kills bacteria but not human cells.

Antibiotic resistance is now a significant and growing issue, and antimicrobial stewardship must be considered in practice (NICE, 2015). The local application of antibiotics should be avoided: 'not only because of the promotion of resistance development, but also because of their microbiostatic mode of action and concentrations that are hard to adjust', and topical antimicrobial agents should be used instead. In the case of systemic infection, systemic antibiotics should be used in combination with topical antimicrobial agents, if necessary.

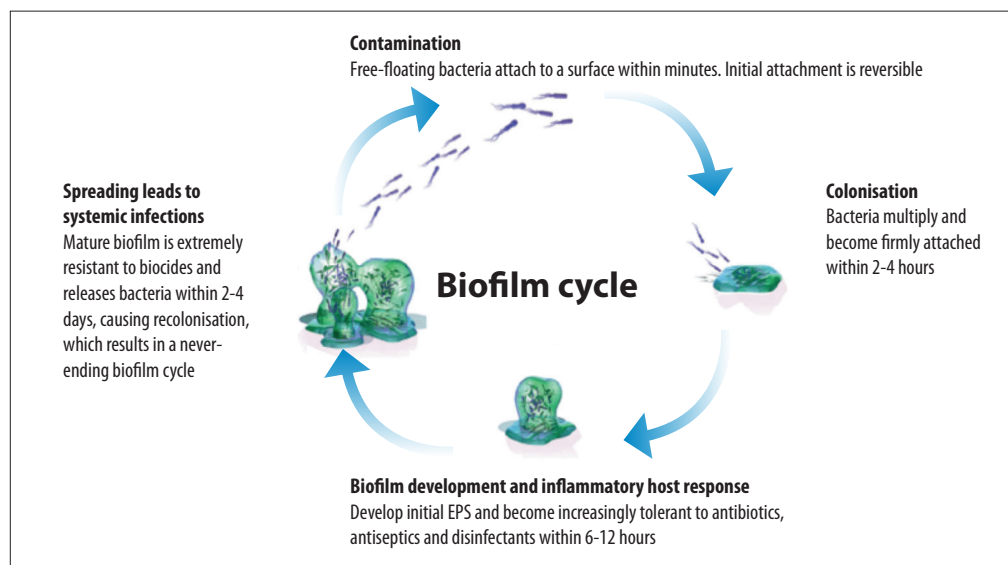
Although many wounds, particularly chronic ones, are contaminated, this does not mean that all wounds will develop infection. If a wound is not infected but is deemed to be at increased risk of infection, antimicrobial agents may be used as a preventative measure, to prevent bacterial burden from increasing and tipping the wound into infection (Roth et al, 2017).

*Axel Kramer is Specialist in Hygiene and Environmental Medicine, University of Greifswald, Germany; Jan Stryja is Vascular Surgeon, Cardiovascular Centre, Hospital Podlesi, Trinec, Czech Republic; Thomas Haeni is Head of Global Product Management, B.Braun, Sempach, Switzerland; Luxmi Mohamud is Nurse Consultant in Tissue Viability, Central and North West London NHS Foundation Trust, UK*

### Box 1. Considering the TIME principles.

- **Tissue management:** Tissue management should not focus solely on debridement, but debridement is an important element to aid infection control and improve healing outcomes. The aim is to ensure the basic conditions for healing (ample nutrients, oxygen, blood supply) on the wound bed.
- **Infection/inflammation:** Biofilm management in particular is a key issue and a biofilm-based care regimen should be considered where appropriate.
- **Moisture:** It is important to strike the optimal moisture balance to ensure the optimum wound healing environment, managing exudate where necessary but also preventing the wound from drying out.
- **Edges/epithelialisation:** The wound edges and epithelial tissue should be monitored, and advanced therapies used where necessary.

Figure 1. The biofilm cycle.



Preventative wound irrigation can be a useful component in the treatment process for all wounds at risk of infection.

In conclusion, it was emphasised that the key message is to strike a balance between efficacy, time dependence and tolerability.

Next, Dr Jan Stryja (Cardiovascular Centre, Hospital Podlesi, Trinec, Czech Republic) explained the importance of tailoring practice in WBP and ensuring that the best treatment is chosen for the individual patient. As such, it is also vital to consider any underlying factors that may influence healing (such as comorbidities, lifestyle and holistic health) – for example, in diabetic and ischaemic wounds.

It is advised to use a structured system such as the TIME principle (Dowsett and Newton, 2005) and take a step-by-step approach to care, but outcomes can be further improved when an individualised approach is taken that is adapted for the needs of the individual patient.

The combination of cleansing and regular debridement in practice helps to remove barriers to healing and 'opens the healing window', thus going on to improve overall outcomes (Wolcott et al, 2009).

In the step of Infection/Inflammation management, the treatment strategy depends on the wound bioburden. Biofilm is a key issue when considering infection and the need for antimicrobial agents. One of the objectives of WBP should be to manage biofilm, particularly in chronic wounds: one recent study demonstrated that up to 90% of chronic wounds have biofilm present (Malone et al, 2017).

The nature of the biofilm cycle [Figure 1] means that early intervention is vital in any wounds where biofilm is present or suspected. The formation of biofilm is a multi-step process that occurs quickly

and is reversible during the early stages. However, as biofilm formation progresses, disruption and eradication become increasingly difficult, as the bacteria become increasingly resistant to antibiotics, antiseptics and disinfectants (Wounds International, 2018). While biofilm is made up of microscopic bacteria and is not visible to the eye, there are visual signs that can indicate biofilm may be present and should be suspected, such as a shiny/slimy wound surface, and a painful chronically infected wound (Wounds International, 2017).

While there is no one-step solution for the eradication of biofilm, it can be treated proactively by breaking up and removing the biofilm, through vigorous/active cleansing with solutions supporting biofilm removal (e.g. Prontosan®) and/or appropriate debridement (Wounds International, 2018).

Prontosan® Wound Irrigation Solution (B.Braun), which combines the actions of betaine and polyhexamethylene biguanide (Polyhexanide or PHMB), can be a useful cleanser in everyday practice. Polyhexanide (PHMB) has a broad antimicrobial spectrum that is effective against bacteria, viruses and fungi, which to date has not been shown to contribute to antimicrobial resistance (Wounds International, 2018). Betaine is a surfactant, which lifts microbes and suspends them in a solution, to prevent wound recontamination.

To illustrate the TIME concept, Dr Stryja presented two cases of infected venous leg ulcers (VLUs) in which Prontosan® solution was successfully used to improve healing outcomes in challenging chronic wounds.

The first case was an infected VLU with biofilm present; a swab had confirmed bacterial

Figure 2. The Prontosan® debridement pad.



colonisation of the wound. Prontosan® solution was used as part of a wound care regimen including compression therapy. Improvement was seen after 4 and 6 weeks of treatment, with the wound going on to complete healing within 8 weeks.

The second case was an infected mixed VLU, which required revascularisation (PTA of crural arteries). Prontosan® solution was used as part of protocol of care with multilayer short-stretch compression bandages. After 4 months and wound improvement, the treatment switched to hydrofiber dressings changed every 3 days, and the wound went on to heal within 6 months.

Thomas Haeni (Head of Global Product Management, B.Braun) went on to discuss the debridement element of WBP, with a focus on mechanical debridement, which can be undertaken at home or in the community setting (Wounds International, 2018).

The Prontosan® Debridement Pad (B.Braun) optimises the principle of soft debridement, combining microfibre technology with a patented teardrop shape, providing efficacy and flexibility in practice.

Microfibres have a good effectiveness in cleansing, due to their size and structure: one microfibre is approximately 1/100th the diameter of a human hair, meaning that there are many more of them in the pad's surface area than in a traditional fibre pad. Each microfibre has a split structure, producing several strands per fibre, which not only produces a greater 'lifting' effect but also allows the microfibre to retain particles of debris in the space between each strand – further increasing the surface area available for cleansing and removal of debris. Microfibres are able to attach themselves to even the smallest, most microscopic particles — ones that much-larger traditional fibres can brush past.

Additionally, microfibres can use microscopic 'electrostatic forces' to bind to particles, further increasing their ability to lift and retain particles of slough and debris. In practical terms, this means

that slough and debris will effectively be lifted from the wound bed, and removed and retained within the Prontosan® Debridement Pad.

In practice, the microfibre technology has been found to be highly effective, including in wounds where traditional debridement methods have been unsuccessful (Ovens and Irving, 2018). Patient comfort has been particularly noted, with good tolerability and patient satisfaction (Ovens and Irving, 2018).

The unique teardrop shape [Figure 2] enables use in hard-to-reach areas and cavities. The pad can also be folded where necessary, increasing its flexibility in such areas.

To guarantee its efficacy, the Prontosan® debridement pad has to be moistened before use. This can be done with Prontosan® solution, which is recommended to increase efficacy or, alternatively, saline solution or distilled water can be used (Ovens and Irving, 2018).

Luxmi Mohamud (Central and North West London NHS Foundation Trust, UK) described two very challenging case studies in which Prontosan® Wound Irrigation Solution and the debridement pad had been used, and achieved successful results in practice.

Both patients had chronic lower limb wounds, with multiple comorbidities and quality of life issues. These were both challenging patients with longstanding wounds, who were being seen twice a week in clinic.

The first patient had a chronic wound that had been static for months. Due to the patient's pain levels, debridement was not always possible. Odour was a significant problem, which the patient was very conscious of, and which caused related psychosocial issues.

Prontosan® irrigation solution was used in conjunction with the Prontosan® debridement pad. This was found to improve the condition of the wound bed, which facilitated healing and had a positive effect on the patient's quality of life.

## References

- Dowsett C, Newton H (2005) Wound bed preparation: TIME in practice. *Wounds UK* 1(3): 58–70
- Kramer A, Dissemond J, Kim S (2018) Consensus on wound antiseptics: Update 2018. *Skin Pharmacology and Physiology* 31(1): 28–58
- Malone M, Bjarnsholt T, McBain A et al (2017) The prevalence of biofilms in chronic wounds: a systemic review and meta-analysis of published data. *Journal of Wound Care* 26 (1) 20–5
- National Institute for Health and Care Excellence (2015) *Antimicrobial Stewardship: Systems and Processes for Effective Antimicrobial Medicine Use*. NICE Guideline NG15. Available at: <https://www.nice.org.uk/guidance/ng15> (accessed 8.06.2018)
- Ovens L, Irving S (2018) Advances in wound cleansing: an integrated approach. *Wounds UK* 14(1): 58–63
- Roth B, Neuenschwander R, Brill F et al (2017) Effect of antiseptic irrigation on infection rates of traumatic soft tissue wounds: a longitudinal cohort study. *J Wound Care* 26: 1–6
- Wolcott RD, Kennedy JP, Dowd SE (2009) Regular debridement is the main tool for maintaining a healthy wound bed in most chronic wounds. *J Wound Care* 18(2): 54–6
- Wounds International (2017) *Management of Wound Biofilm Made Easy*. Available online at: <http://www.woundsinternational.com/made-easy/view/management-of-wound-biofilm-made-easy> (accessed 19.09.2018)
- Wounds International (2018) *Prontosan® Debridement Pad Made Easy*. Wounds International, London. Available at: <http://www.woundsinternational.com/made-easy/view/prontosan-debridement-pad-made-easy> (accessed 19.09.2018)

### Box 2. Using the Prontosan® debridement pad in practice.

The Prontosan® debridement pad is indicated in chronic wounds, including pressure ulcers, venous leg ulcers and diabetic foot ulcers. The Prontosan® debridement pad has been designed to support WBP in conjunction with Prontosan® Wound Irrigation Solution or, if unavailable, with saline solution or distilled water. There is a simple, three-step process for using the Prontosan® debridement pad to safely and effectively debride the wound bed and periwound skin.

#### STEP 1.

Moisten the unmarked side of the pad with Prontosan® Wound Irrigation Solution, in the blister packaging that allows for safe and aseptic soaking of the pad prior to use; 15–20ml is sufficient to moisten the entire pad. If local guidelines exist, they should be observed.

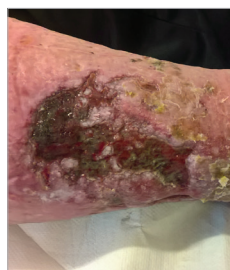#### STEP 2.

Applying gentle pressure, wipe the moistened side over the wound and/or adjacent skin in a circular or sweeping motion.

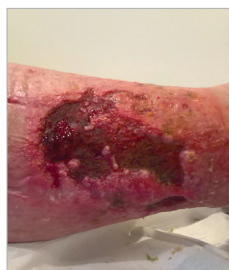#### STEP 3.

After debridement, it is advisable to irrigate the wound thoroughly for a second time with Prontosan® Wound Irrigation Solution (or other indicated solution), in order to thoroughly cleanse the wound and remove any traces of debris/biofilm, and to continue with appropriate treatment, based on holistic assessment and local protocols.

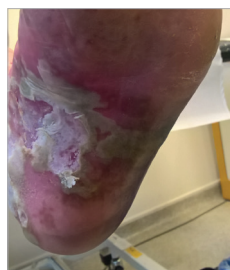The pad is sterile and individually packed, and is intended for single use only. It should not be rinsed or reused; cut to size; used as a wound dressing; used in cases of known intolerance or allergy to one or more of the pad's components.



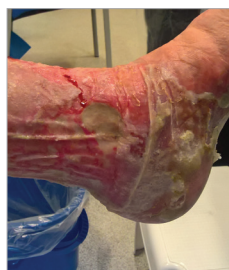Case 1. Before debridement.



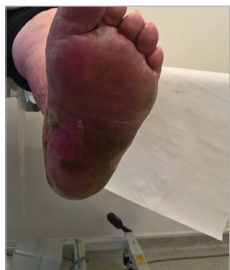Case 1. After debridement.



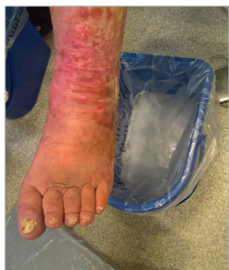Case 2. Before debridement.



Case 2. Before debridement.



Case 2. After debridement.



Case 2. After debridement.

As his pain and odour issues improved, the patient's mobility also benefited, which had a positive effect on his overall health. The patient was able to increase his exercise levels, then agreed to seeing a dietician, which helped to get his diabetes under control.

Enabling debridement and proper WBP, which kickstarted healing in the wound, had a hugely positive effect on the patient's general health and quality of life.

In the second patient, recurrence was an issue: the patient had been prescribed hosiery, but the wound originated from a blister sustained on holiday when she was not wearing her hosiery garment due to the heat.

The wound became static and the surrounding skin macerated. Pain was an issue, which affected the patient's mobility — she had to walk on tiptoe, being unable to put weight on her foot. This meant that she eventually had to use a wheelchair and was unable to use public transport.

Odour was also a significant issue. The patient lived alone with her dog, and the odour from the wound caused problems with the dog sniffing her wound, which was distressing for the patient and affected her quality of life.

Prontosan® debridement pad was used weekly. Improvement could be seen immediately, which increased the patient's confidence. She began to look forward to clinic visits and was more engaged with her treatment. Along with pain and odour, her mobility also improved, which enabled her to walk with a stick and use public transport. The wound went on to heal and there was no recurrence.

These cases illustrate that facilitating the fundamental elements of WBP — principally, cleansing and debridement — can improve outcomes and have a positive effect upon patient wellbeing and quality of life.

It is important to remember that dressing selection — and any additional advanced therapies — will not be able to provide their full benefit unless the fundamentals of WBP are in place.

WINT