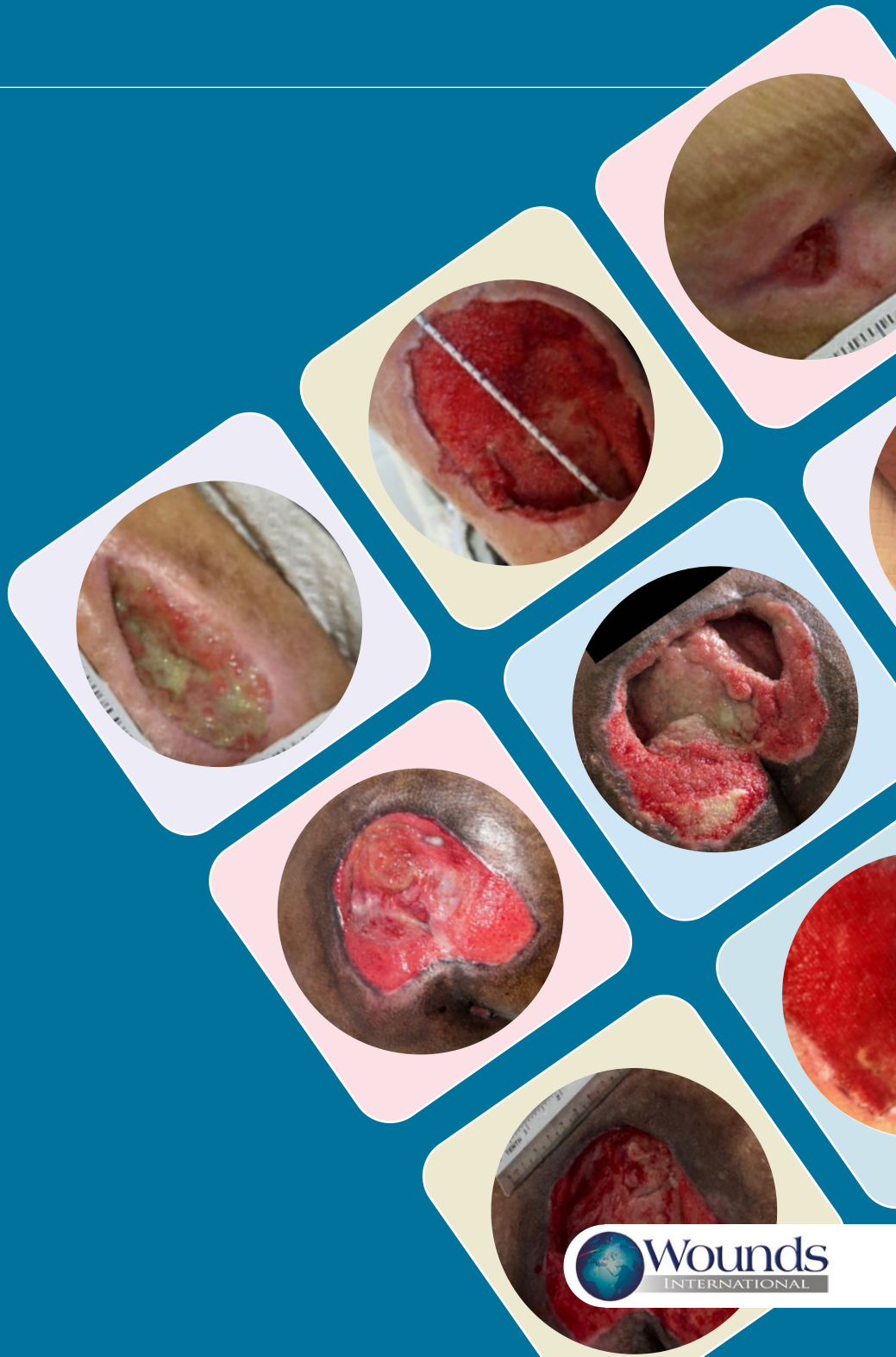


INTERNATIONAL
CASE REPORTS

The Asia-Pacific region; the OneNPWT clinical decision tree for open wounds

CASE REPORT SERIES 2023



Published by

Wounds International
A division of Omniamed Communications Ltd
108 Cannon Street
London EC4N 6EU, UK
Tel: +44 (0)20 3735 8244
Email: info@omniamed.com
www.woundsinternational.com



© Wounds International, 2023

Suggested citation

Wounds International (2023) *Case series: The Asia-Pacific region; the OneNPWT clinical decision tree for open wounds*. Wounds International, London, UK

Free download available from:
www.woundsinternational.com

All rights reserved ©2023. No reproduction, copy or transmission of this publication may be made without written permission.

No paragraph of this publication may be reproduced, copied or transmitted save with written permission or in accordance with the provisions of the Copyright, Designs and Patents Act 1988 or under the terms of any license permitting limited copying issued by the Copyright Licensing Agency, 90 Tottenham Court Road, London, W1P 0LP.

Supported by an educational grant from
Smith+Nephew.

The views expressed in this publication are those of the authors and do not necessarily reflect those of Smith+Nephew.

OneNPWT clinical decision tree for open wounds

FOREWORD

The prevalence of wounds is increasing globally, particularly in the Asia-Pacific (APAC) region. The International Diabetes Federation (IDF) estimates that there were 537 million people with diabetes worldwide in 2021, and up to one-third of those individuals will experience a diabetic foot ulcer (DFU) during their lifetime (Nair et al, 2022). The high prevalence of diabetes in the APAC region accounted for over 60% of the 5.1 million deaths caused by diabetes globally in 2013 (Organisation for Economic Co-operation and Development [OECD], 2020). In Australia, there are 400,000 people affected with chronic wounds, which is associated with a direct healthcare cost of AUD\$3 billion (Australian Centre for Health Services Innovation et al, 2017). This equates to 2% of the Australian national healthcare expenditure. On pressure ulcers alone, it is estimated that AUD\$983 million is spent annually and more than 500,000 bed days are lost. While official statistics are either unavailable or difficult to access in the APAC region, a comprehensive population-based analysis in Singapore between 2000 and 2017 estimated that among all Singaporeans hospitalised for acute care, the incidence of wounds was 300 per 100,000 adults over the age of 18 and 800 per 100,000 adults over the age of 50 (Goh et al, 2020).

Negative pressure wound therapy (NPWT) is the gold standard treatment for many open acute and chronic wounds (Bakaeen et al, 2019; Kim and Kang, 2020; Seidel et al, 2020). NPWT involves applying the NPWT system to a dressing that is designed to deliver suction and promote wound healing. There are two general delivery systems — traditional negative pressure wound therapy (tNPWT) and single use negative pressure wound therapy (sNPWT) [Table 1].

Table 1. Traditional and single use NPWT	
Traditional NPWT	Single use NPWT
Multi-patient use	Single use and disposed of following treatment
Pressure applied is adjustable with continuous and intermittent modes of operation (Banasiewicz et al, 2019)	Pressure is applied continuously and is not adjustable (Banasiewicz et al, 2019)
Draws fluid from a wound into a cannister via tubing	Manages fluid with its dressing through evaporation from the outer layer of the dressing (Banasiewicz et al, 2019)
Uses wound filler to distribute negative pressure, commonly foam or gauze, but others are available	Wound filler is optional to distribute negative pressure*
Often powered by mains electricity source (Banasiewicz et al, 2019).	Battery-powered.

*Recommended for treating open wounds with 0.5cm to 2cm in depth

The use of tNPWT can be complex and resource-intensive and hospital resources may struggle to match the growing demand. There are hidden costs that can increase the economic burden associated with using NPWT and discharge processes are complex (Kirsner and Hurd, 2020; Hurd et al, 2021). As a result, an international panel of 5 clinicians from Malaysia, Singapore, Australia and New Zealand with experience in wound care and NPWT developed a set of recommendations to help provide optimal patient care and resource efficiency. The panel aimed to advise clinicians on when to consider NPWT use in acute and chronic wound management and provide a practical decision-making tool, known as the OneNPWT clinical decision tree for open wounds, to guide on NPWT modality (RENASYS™ Negative Pressure Wound Therapy System or PICO™ Single Use Negative Pressure Wound Therapy System) and when it should be used.

This case series describes how the OneNPWT decision tree [Figure 1] was used in clinical practice by wound care specialists in the APAC regions. The decision tree was used within local protocol to prompt initiation of either RENASYS™ tNPWT or PICO™ sNPWT [Figure 2]. Each patient was monitored and reviewed until NPWT was ceased or until full wound closure. The characteristics of the wounds (i.e. size, wound bed composition) were recorded at dressing change.

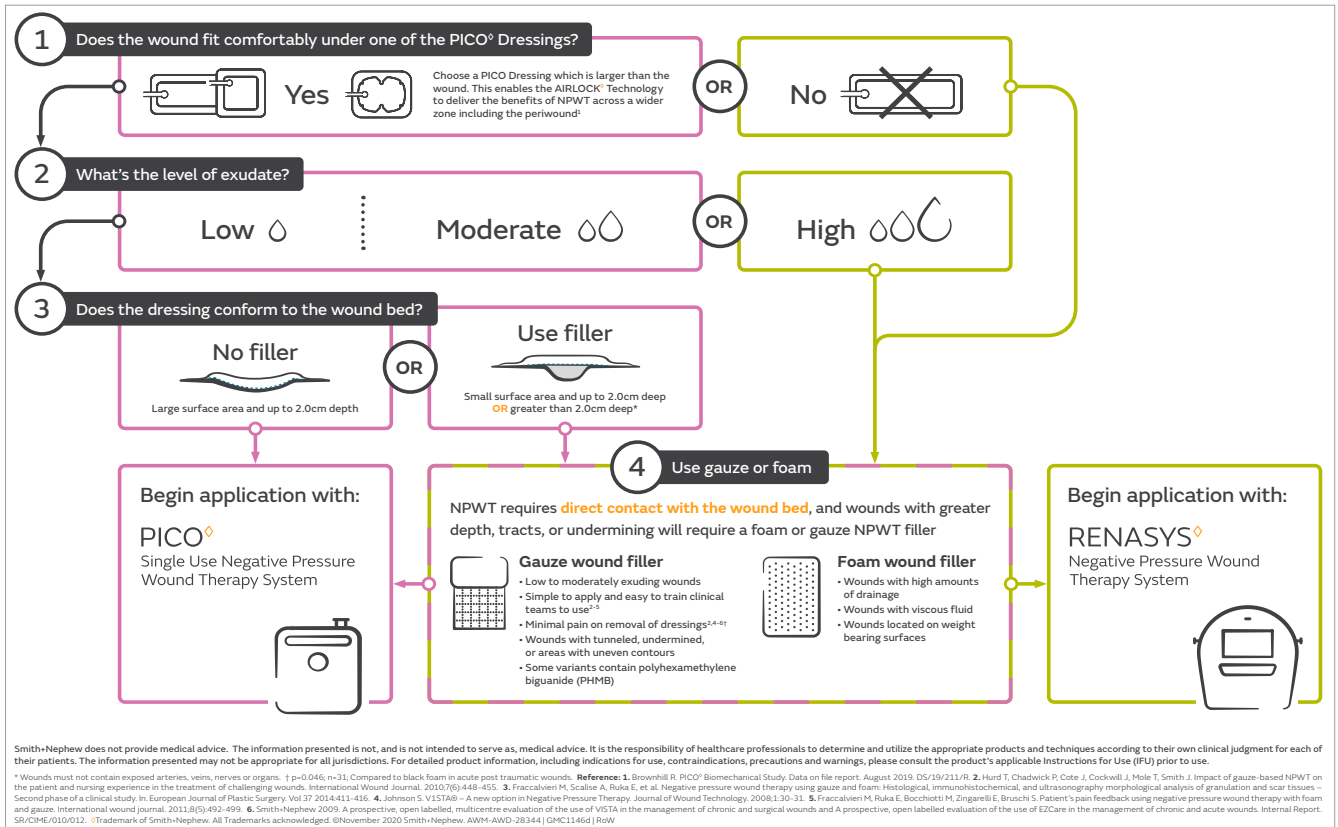
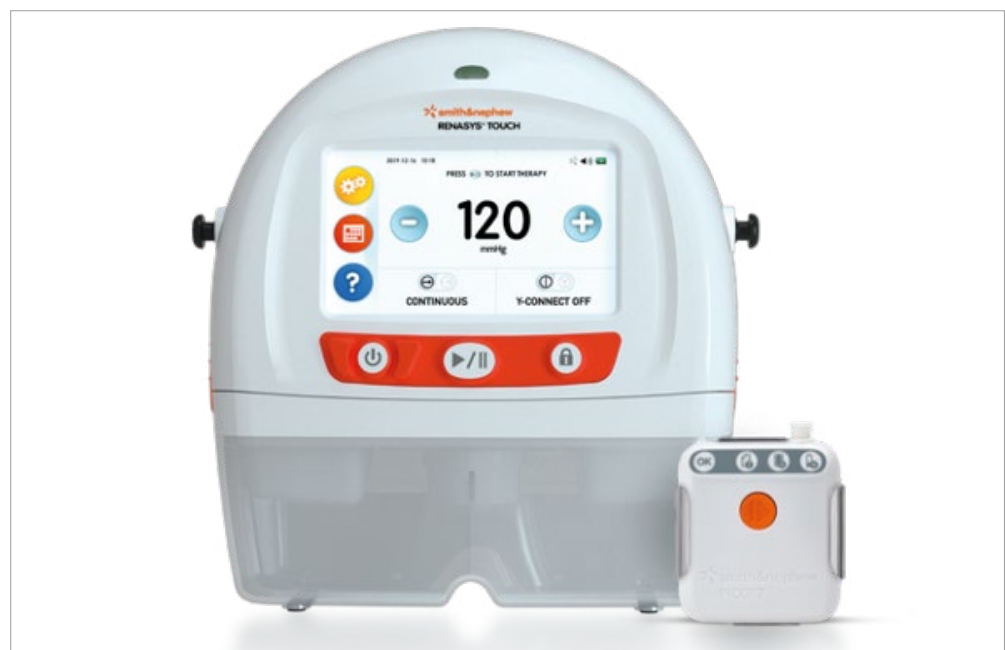

Figure 1. The OneNPWT clinical decision tree for open wounds. © All rights reserved. Figure 1 belongs to Smith+Nephew.

Figure 2. RENASYS™ Negative Pressure Wound Therapy System and PICO™ Single Use Negative Pressure Wound Therapy. © All rights reserved. Figure 2 belongs to Smith+Nephew.



OPERATIONAL OUTCOMES

Healthcare professionals

5 healthcare professionals (HCPs) were asked to provide feedback on use of the OneNPWT decision tree in practice, see Table 2. Their responses indicate that satisfaction levels with use of the decision tree in the 8 case studies were very high, with 75% finding it excellent. HCPs also found the decision tree very easy (excellent; 75%) or easy (good; 25%) to follow. Additional comments indicate that HCPs considered the introduction of PICO™ sNPWT to be a useful interim between RENASYS™ tNPWT and traditional dressings, a viewpoint given in many individual case studies.

Table 2. Healthcare professional feedback about the OneNPWT decision tree (n=8 case studies)

	Excellent	Good	Fair	Poor	Very poor
Satisfaction level	6	2	0	0	0
Ease of learning how to operate	6	2	0	0	0
Comments	<ul style="list-style-type: none"> ■ The OneNPWT decision tree is 'pragmatic', 'simple' and 'suitable' for use in practice ■ Availability of PICO™ sNPWT as an intermediate step-across dressing allows for ease of application and better patient acceptance ■ A great modality and step-across approach. 				

The 8 case studies highlighted several benefits of RENASYS™ tNPWT and PICO™ sNPWT. The flexibility in the mode (continuous or variable) and level of negative pressure applied by RENASYS™ tNPWT meant that healthcare professionals were able to work with patients to ensure this device was both comfortable and effective when used. HCPs stated in various case studies that PICO™ sNPWT was easy to apply and well accepted by patients.

HCPs were asked about dressing change times and expectations. They said that it took between 10 minutes and an hour to change NPWT dressings, see Table 3. The amount of time varied depending on the device used and the complexity of the wound(s), but HCPs were happy with this aspect of treatment: half said it required less time than expected and half said it took the amount of time expected to complete dressing changes.

Table 3. Healthcare professional feedback on time taken for NPWT dressing changes (n=8 case studies)

Time (minutes)	Less than expected	As expected	Longer than expected
10	0	1	0
15	2	2	0
20	1	1	0
60	1	0	0

Patients

Patient-related outcomes from using the OneNPWT decision tree were all excellent or good, see Table 4. 87.5% of patients were very satisfied (excellent), 12.5% were satisfied (good) with the use of NPWT and its outcomes. Compliance with treatment was good or excellent in all cases. The use of PICO™ sNPWT enabled earlier mobilisation and return to activities of daily living, thus having a positive impact on patients' wellbeing. In a few cases, treatment was altered e.g. the level of negative pressure during RENASYS™ tNPWT was changed, to improve comfort and compliance.

Table 4. Patient satisfaction feedback about the OneNPWT decision tree (n=8 case studies)

Operational outcomes using decision tree	Excellent	Good	Fair	Poor	Very poor
Patient satisfaction	7	1	0	0	0
Patient compliance	4	4	0	0	0
Patient ability to resume activities of daily living	2	4	2	0	0

Individual cases highlighted in the series and HCP feedback revealed that patients generally did not understand how NPWT worked. These concerns highlight the importance of patient education in the acceptability of and concordance with treatment; however, most patients complied well with treatment and 75% were very satisfied with it.

Patients' ability to resume activities of daily living varied between excellent (25%), good (50%) and fair (25%). These results demonstrate that all patients experienced some level of improvement following NPWT. Examples of improvements resulting from NPWT include increased mobility, improved self-care, and an ability to return to work. Wider improvements relating to patients' wellbeing highlighted in individual case studies included increased self-esteem, increased confidence to take part in activities and the resolution of pain associated with wounds.

ECONOMIC OVERVIEW

HCPs stated that the use of the OneNPWT decision tree had a positive impact on patient discharge and hospital length of stay in the cases included in this series, see [Box 1](#). Additional economic benefits highlighted by HCPs are given in [Box 2](#). Several practitioners commented that using the OneNPWT decision tree to choose the best available treatment results in savings due to the avoidance of inappropriate dressing use and the provision of an optimal wound-healing environment, leading to a reduction in the number of dressing changes required before healing is achieved.

Box 1. Example HCP comments on how the OneNPWT decision tree impacted discharge and hospital length of stay

- Allowed for earlier discharge with more appropriate selection of NPWT device type based on depth, size and exudate level
- The length of the patient's stay was greatly impacted - allowed patient to be discharged quicker and return home to be cared for by a community wound care nurse consultant
- Patient did not have to attend hospital, and debridement occurred within the aged care home
- Hospitalization was avoided by using RENASYS™ tNPWT at the patient's home
- Less cost due to less hospital stay as the wound progressed well.

Box 2. Additional comments on the economic effects of using the OneNPWT decision tree

- Earlier conversion of RENASYS™ tNPWT to PICO™ sNPWT for convenience of ambulation and handling of pump
- Saves on frequency of dressing change and tolerated better compared with traditional non-NPWT dressings
- Fewer appointments [for dressing changes], freeing up nursing time and earlier return to normal activity including work
- Cost reduction is definite as the bed stays were reduced as well as dressing changes since we can keep the NPWT [dressings on] for longer periods.

CONCLUSION

The case reports in this document illustrate the wide range of open wounds where NPWT is suitable - DFUs, venous leg ulcers, infected wounds, pressure ulcers/injuries and dehisced surgical sites [[Table 5](#)], and demonstrates the use of the OneNPWT decision tree in practice. In most cases, NPWT was discontinued as the aim of treatment had been achieved. In other cases, NPWT was continued as a wound was making good progress towards healing and the patient was comfortable with the mode of therapy and pleased with the results.

The OneNPWT clinical decision tree incorporates the use of both types of NPWT, outlining when each mode of treatment is most appropriate. HCPs reported that the step-across approach from RENASYS™ tNPWT to PICO™ sNPWT resulted in reduced length of hospital stay, faster discharge to outpatient clinics or community care, fewer dressing changes and faster wound healing, reducing the cost of wound treatment. The use of the decision tree in practice was overall considered easy to use and pragmatic.

Key points

- The OneNPWT decision tree is easy to use in practice, is pragmatic and can be used by allied healthcare professionals
- Use of PICO™ sNPWT supports earlier ambulation and discharge to outpatient/community clinics
- The OneNPWT decision tree aids HCPs in choosing the best course of action, preventing the need for unnecessary dressings
- Patient and carer education supports concordance and improves outcomes.

Table 5. Summary of 8 case reports by 5 clinicians

Report	Clinician	Country	Wound type	Page
1	Harikrishna K R Nair	Malaysia	Sacral pressure ulcer/injury	8
2	Harikrishna K R Nair	Malaysia	Grade IV sacral pressure ulcer/injury	10
3	Hayley Ryan	Australia and New Zealand	Deep laceration in a patient with dementia	12
4	Hayley Ryan	Australia and New Zealand	Grade 4 sacral pressure ulcer/injury	14
5	Li Zongxian	Singapore	Deep thigh abscess	16
6	Sathappan Sathappan	Singapore	Infected foot wounds	18
7	Edmund Leung	New Zealand	Trauma to left calf	20
8	Edmund Leung	New Zealand	Venous ulcer on calf	22

REFERENCES

- Australian Centre for Health Services Innovation (AusHSI) (2017) Chronic Wounds in Australia (Issues Paper). Queensland Government, PHN Brisbane North, Wound Innovations, AusHSI. Available at: www.nfn.com.au/wp-content/uploads/2020/02/Chronic-Wounds-Solutions-Forum-Issues-Paper-final.pdf (accessed 4 November 2022)
- Bakaeen FG, Haddad O, Ibrahim M et al (2019). Advances in managing the noninfected open chest after cardiac surgery: Negative-pressure wound therapy. *The Journal of thoracic and cardiovascular surgery* 157(5): 1891-1903
- Banasiewicz T, Bnaky B, Karsenti A, et al (2019) Traditional and single use NPWT: when to use and how to decide on the appropriate use? Recommendations of an expert panel. *Wounds International*
- Brownhill R (2019) PICOSM Biomechanical Study. Data on file report DS/19/211/R
- Fraccalvieri M, Ruka E, Bocchiotti M et al (2011) Patient's pain feedback using negative pressure wound therapy with foam and gauze. *International wound journal* 8(5):492-499
- Fraccalvieri M, Scalise A, Ruka E, et al (2014) Negative pressure wound therapy using gauze and foam: Histological, immunohistochemical, and ultrasonography morphological analysis of granulation and scar tissues - Second phase of a clinical study. *European Journal of Plastic Surgery* 37: 411-416
- Goh OQ, Ganesan G, Graves N et al (2020) Incidence of chronic wounds in Singapore, a multiethnic Asian country, between 2000 and 2017: a retrospective cohort study using a nationwide claims database. *BMJ Open* 10(09)
- Hurd T, Chadwick P, Cote J et al (2010) Impact of gauze-based NPWT on the patient and nursing experience in the treatment of challenging wounds. *International Wound Journal* 7(6): 448-455
- Hurd T, Kirsner RS, Sancho-Insenser JJ et al (2021) International Consensus Panel Recommendations for the Optimization of Traditional and Single-Use Negative Pressure Wound Therapy in the Treatment of Acute and Chronic Wounds. *Wounds : a compendium of clinical research and practice* 33: S1-S11
- Johnson S (2008) V1STAR - A new option in Negative Pressure Therapy. *Journal of Wound Technology* 1: 30-31
- Kim S, Kang Sung IL (2020) The effectiveness of negative-pressure wound therapy for wound healing after stoma reversal: a randomised control study (SR-PICO study). *Trials* 21(1): 24
- Kirsner RS and Hurd T (2020) Assessing the Need for Negative Pressure Wound Therapy Utilization Guidelines: An Overview of the Challenges With Providing Optimal Care. *Wounds : a compendium of clinical research and practice* 32(12): 328-333
- Nair HKR, Chew KY, Jun Y et al (2022) International Consensus Document: *Diabetic foot ulcer care in the Asia-Pacific region*. *Wounds International*. Available online at www.woundsinternational.com
- Organisation for Economic Co-operation and Development/World Health Organisation (2020) Health at a Glance: Asia/Pacific 2020: Measuring Progress Towards Universal Health Coverage. Paris: OECD Publishing
- Seidel D, Diedrich S, Herle F et al (2020) Negative Pressure Wound Therapy vs Conventional Wound Treatment in Subcutaneous Abdominal Wound Healing Impairment: The SAWHI Randomized Clinical Trial. *JAMA surgery* 155(6): 469-47
- Smith+Nephew (2009) A prospective, open labelled, multicentre evaluation of the use of VISTA in the management of chronic and surgical wounds and A prospective, open labelled evaluation of the use of EZCare in the management of chronic and acute wounds. Internal Report. SR/CIME/010/012.

CASE 1: SACRAL PRESSURE ULCER/INJURY

Authors: Harikrishna K R Nair, Professor and Head of Wound Care, and Nurzuliana Zulkarnain, Medical Officer, Malaysia

PATIENT PRESENTATION AND HISTORY

- A 56-year-old man had been admitted to the intensive care unit (ICU) following a stroke and hypertensive emergency
- His recovery was complicated by the presence of an infected grade 3 sacral pressure ulcer, which he developed in the ICU
- Following discharge from the ICU, his sacral pressure ulcer was managed at home by family members, who cleansed the area daily with sterile water and replaced his dressings
- The wound worsened over time and became a grade 4 pressure ulcer, so the patient was admitted to the medical ward to be managed by the wound care clinic medical officer and staff nurse.

WOUND PRESENTATION

- **Wound size:** 12cm (length) x 10.5cm (width) x 1cm (depth)
- **Wound bed:** Irregular
- **Surrounding skin:** Healthy with no signs of infection or inflammation
- **Consistency and exudate level:** Haemoserous and high level.

MANAGEMENT PLAN AND CLINICAL OUTCOMES

Treatment aimed to reduce the size of the patient's wound and promote rapid healing so the patient could be discharged from the medical ward to the wound care clinic for outpatients. Slough was debrided from the wound, revealing it to be 1cm deep and uninfected. Debridement also revealed the presence of undermining. Due to the large size of the wound and high volume of exudate, RENASYS™ tNPWT was initiated and ACTICOAT™ FLEX 3 Antimicrobial Barrier Dressing was applied to the wound bed to reduce the risk of infection.

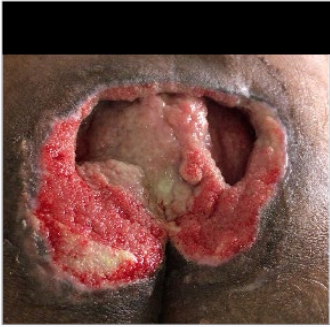- **NPWT:** RENASYS™ tNPWT
- **Wound contact layer:** ACTICOAT™ FLEX 3 Dressing
- **Pressure setting:** Continuous at -120mmHg
- **Planned dressing change frequency:** Every 3 days.

After a week, collagen dressings were applied to the wound bed to encourage new tissue formation and the wound was covered with ACTICOAT™ FLEX 3 Dressing. The treatment regimen was continued for 4 weeks in total, at which point the wound and undermining had reduced in size, therefore, the RENASYS™ tNPWT was changed to PICO™ sNPWT. At this time, collagen dressings were discontinued, and the patient's care was moved to the outpatient wound care clinic.

At a routine outpatient visit at 6 weeks, the wound had significantly decreased in size. The wound bed consisted of granulation and epithelialisation tissue, there was no undermining and little exudate. PICO™ sNPWT was continued, as the wound was responding well to PICO™ sNPWT, and the patient was relieved that their wound was healing.

CONCLUSION

The patient was initially admitted to the medical ward but after 4 weeks of RENASYS™ tNPWT, he was discharged to the outpatient setting as his sacral pressure ulcer had significantly improved. Treatment was stepped across from RENASYS™ tNPWT to PICO™ sNPWT, which was continued beyond 6 weeks. Wound size and volume of exudate continued to decrease throughout the treatment period. The combination of RENASYS™ tNPWT and PICO™ sNPWT was considered a successful step-across approach in this patient.



Week 1: 1 week of treatment with RENASYS™ tNPWT

Exudate level and consistency: High with thick haemorrhous discharge

Wound size (length x width x depth): 11.5cm x 8.5cm x 1cm

Wound edge: Undermined

Tissue type: Granulation

Surrounding skin: Healthy, no signs of infection or inflammation.

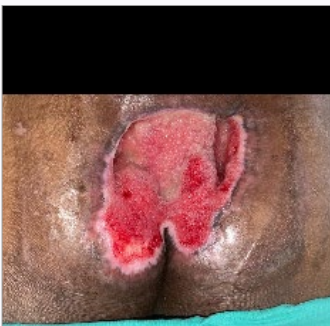Wound contact layer: ACTICOAT™ FLEX 3 Dressing

Pressure setting: Continuous at -120mmHg

Planned dressing change frequency: 3 days

Additional treatment: Collagen dressings

Treatment plan: As per the OneNPWT decision tree, continue RENASYS™ tNPWT.



Week 4: 4 weeks of treatment with RENASYS™ tNPWT

Exudate level and consistency: Moderate and thin

Wound size (length x width x depth): 8cm x 7cm x 1cm

Wound edge: Undermined (small area)

Tissue type: Granulation with epithelialisation

Surrounding skin: Healthy, no signs of infection or inflammation.

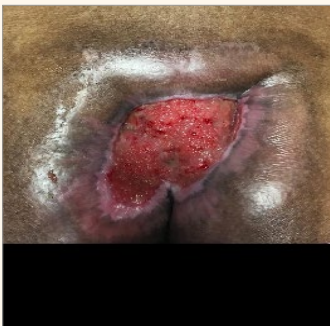Wound contact layer: ACTICOAT™ FLEX 3 Dressing

Pressure setting: Continuous at -120mmHg

Planned dressing change frequency: 3 days

Additional treatment: Collagen dressings

Treatment plan: As per the OneNPWT decision tree, switch to PICO™ sNPWT.



Week 6: 2 weeks of treatment with PICO™ sNPWT

Exudate level and consistency: Low and thin

Wound size (length x width x depth): 5.5cm x 5.5cm x 1cm

Wound edge: Advancing with epithelial tissue

Tissue type: Granulation with epithelialisation

Surrounding skin: Healthy, no signs of infection or inflammation.

Wound contact layer: ACTICOAT™ FLEX 3 Dressing

PICO dressing size: 20cm x 25cm

Planned dressing change frequency: 3 days

Treatment plan: Continue PICO™ sNPWT to achieve the planned outcome of complete healing.

CASE 2: GRADE 4 SACRAL PRESSURE ULCER/INJURY

Authors: Harikrishna K R Nair, Professor and Head of Wound Care, and Nurzuliana Zulkarnain, Medical Officer, Malaysia

PATIENT PRESENTATION AND HISTORY

- A 46-year-old man with underlying hypertension and T7-T8 thoracic myelopathy
- Following surgery to treat his thoracic myelopathy, he experienced prolonged immobilisation as an inpatient and developed a sacral pressure ulcer
- The pressure ulcer worsened over time and eventually developed into a grade 4 pressure ulcer
- His self-esteem suffered as a result of the pressure ulcer, which rendered him dependent on others for daily tasks.

WOUND PRESENTATION

- **Wound size:** 15cm (length) x 7cm (width) x 2cm (depth)
- **Wound bed:** Well-defined
- **Surrounding skin:** Healthy epithelial tissue
- **Consistency and exudate level:** Thick and high level.

MANAGEMENT PLAN AND CLINICAL OUTCOMES

At the time of assessment, the grade 4 pressure ulcer was 2cm deep and twice as long as it was wide. The aim of the treatment was to completely heal the pressure ulcer. As per the OneNPWT decision tree, the wound was packed with foam filler and RENASYS™ tNPWT was initiated because the ulcer was producing a large volume of exudate.

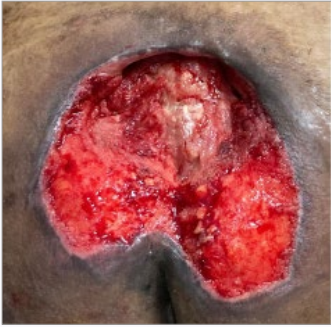
- **NPWT:** RENASYS™ tNPWT
- **Filler:** Foam filler
- **Pressure setting:** Continuous at -120mmHg
- **Planned dressing change frequency:** Every 3 days.

Seven days after starting RENASYS™ tNPWT, the wound bed was covered with granulation tissue and by week 3, the depth of the ulcer was decreasing. There were weekly reductions in the volume of exudate and improvements in exudate consistency. The patient was discharged after week 4 and it then was decided to switch to PICO™ 7 Single Use Negative Pressure Wound Therapy System (sNPWT) to encourage ambulation. The frequency of dressing changes was decreased to every 7 days at this time. After 2 weeks with PICO™ 7 sNPWT, the foam filler was discontinued, as it was no longer required, and PICO™ 7 sNPWT was continued to achieve the planned outcome of complete healing.

The patient was very pleased with the improvement in his wound. He reported that he had been able to resume some daily activities when treatment was stepped across from RENASYS™ tNPWT to PICO™ 7 sNPWT, which had improved his self-esteem.

CONCLUSION

The step-across approach to PICO™ 7 sNPWT that was used to manage this patient's sacral pressure ulcer resulted in significant reductions in wound size, depth, and exudate volume. In addition to the positive impact of NPWT on the pressure ulcer, there were improvements in the patient's mobility and mental wellbeing during treatment. RENASYS™ tNPWT and PICO™ 7 sNPWT were easy to use, and using them consecutively resulted in fast healing and early patient discharge.



Week 1: 1 week of treatment with RENASYS™ tNPWT

Exudate level and consistency: High and thick

Wound size (length x width x depth): 12cm x 11cm x 1cm

Tissue type: Granulation tissue

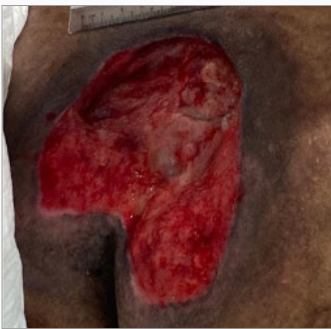Surrounding skin: Epithelial tissue.

Filler: Foam filler

Pressure setting: Continuous at -120mmHg

Planned dressing change frequency: 3 days

Treatment plan: As per the OneNPWT decision tree, continue RENASYS™ tNPWT.



Week 4: 4 weeks of treatment with RENASYS™ tNPWT

Exudate level and consistency: Low and thin

Wound size (length x width x depth): 11cm x 8.5cm x 1cm

Tissue type: Healthy granulation tissue

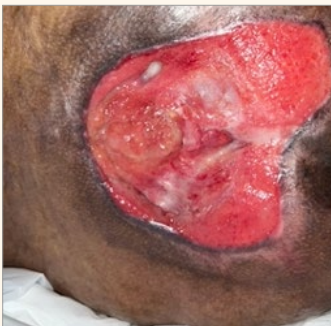Surrounding skin: Epithelial tissue.

Filler: Foam filler

Pressure setting: Continuous at -120mmHg

Planned dressing change frequency: 3 days

Treatment plan: As per the OneNPWT decision tree, the patient was switched to PICO™ 7 sNPWT because of the patient's reduced exudate and to promote ambulation.



Week 7: 3 weeks of treatment with PICO™ sNPWT

Exudate level and consistency: Low and thin

Wound size (length x width x depth): 10cm x 9cm x 0.5cm

Tissue type: Healthy granulation tissue

Surrounding skin: Epithelial tissue.

Filler: No foam filler required

PICO dressing used and size: PICO™ 7 sNPWT 20cm x 25cm

Planned dressing change frequency: 7 days

Treatment plan: Continue PICO™ 7 sNPWT to achieve the planned outcome of complete healing.

CASE 3: DEEP LACERATION IN A PATIENT WITH DEMENTIA

Author: Hayley Ryan, WoundRescue, Wound Clinical Nurse Consultant, Australia and New Zealand

PATIENT PRESENTATION AND HISTORY

- An 88-year-old woman with a clinical history of: cognitive impairment due to Alzheimer's disease, hypertension, depression, COPD, osteoarthritis, osteoporosis, chronic bilateral knee pain and psoriasis
- The patient had a fall at home and sustained a deep laceration. She did not seek medical assistance for 2 days. Her husband treated the wound at home using gauze to stem the bleeding
- The wound was not suitable for suturing; the patient was therefore referred to the wound care nurse consultant for treatment.

WOUND PRESENTATION

- **Wound size:** 7cm (length) x 3cm (width) x 4cm (depth)
- **Wound bed:** Rolled
- **Surrounding skin:** Dry
- **Consistency and exudate level:** Thick and high level.

MANAGEMENT PLAN AND CLINICAL OUTCOMES

On examination, the laceration was very deep, highly exudating, odorous and the tissue was pale. The wound was packed with foam filler and RENASYS™ tNPWT was started on a continuous low-pressure setting, as the patient said she found this more comfortable than the higher-pressure setting. As the skin surrounding the laceration was very dry, emollient creams were applied around the NPWT dressings.

- **NPWT:** RENASYS™ tNPWT
- **Filler:** Foam filler required due to depth of wound
- **Pressure setting:** Continuous at -100mmHg
- **Planned dressing change frequency:** Every 2 days.

After a week of RENASYS™ tNPWT, there was evidence of healing potential, as some granulation tissue was present in the wound bed.

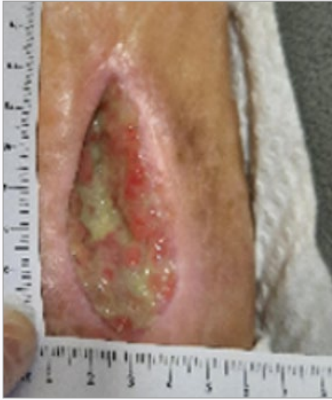Two weeks after starting RENASYS™ tNPWT, mechanical debridement was used to remove devitalised tissue from the wound bed. Oedema was present and there were some dry patches of skin surrounding the wound. ACTICOAT™ FLEX 3 Dressing would have been used, however it was not available at this visit.

A week later ACTICOAT™ FLEX 3 Dressing was added to the treatment regimen, as it was now available and gauze was used to fill the gaps instead of foam filler. The negative pressure setting was increased to -120mmHg on a trial basis, with the patient's agreement. Her tolerance to the change in pressure was monitored during the following week and she reported no issues.

During week 5, treatment was stepped across to PICO™ 7 sNPWT and ACTICOAT™ FLEX 7 Antimicrobial Barrier Dressing, allowing for a longer period of wear. A week later, ACTICOAT™ FLEX 7 Dressing was discontinued due to the significant improvements seen on dressing change: there was little exudate, the wound bed had almost filled in, the wound edges were closing, the oedema had resolved, and the surrounding skin was healthy. NO-STING SKIN-PREP™ Skin Protectant was subsequently applied to the surrounding dressing to avoid issues with the dressing coming off. This regimen was continued until week 7 when the wound had healed.

CONCLUSION

The patient engaged positively with the treatment and the nurses were able to adjust the level of negative pressure and the products applied to the wound as needed based on stage of healing. The involvement of all parties and use of a step across approach to PICO™ 7 sNPWT resulted in the successful resolution of this deep wound in 7 weeks.



Week 1: 1 week of treatment with RENASYS™ tNPWT

Exudate level and consistency: Moderate and thick

Wound size (length x width x depth): 6cm x 2.8cm x 3cm

Tissue type: Devitalised tissue

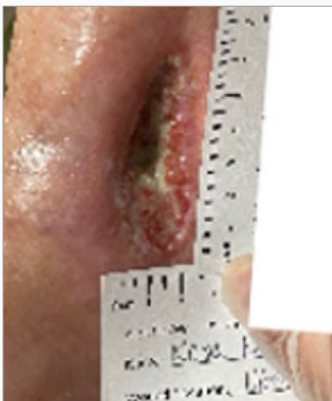Surrounding skin: Dry patches and oedema.

Filler: Foam filler

Pressure setting: Continuous at -100mmHg

Planned dressing change frequency: 3 days

Treatment plan: In accordance with the patient's tolerance, negative pressure was increased on a trial basis.



Week 4: 4 weeks of treatment with RENASYS™ tNPWT

Exudate level and consistency: Moderate and thin

Wound size (length x width x depth): 5cm x 2cm x 1cm

Tissue type: Granulation at wound base

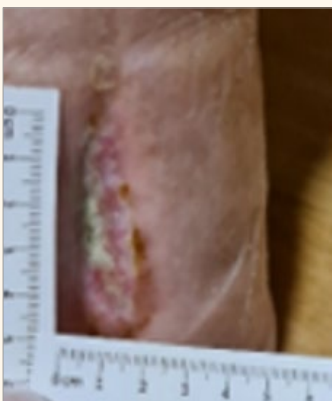Surrounding skin: Healthy; reduction in oedema.

Filler: Gauze

Wound contact layer: ACTICOAT™ FLEX 3 Dressing

Pressure setting: Continuous at -120mmHg

Treatment plan: As per the OneNPWT decision tree, step across to PICO™ 7 sNPWT and ACTICOAT™ FLEX 7 Dressing.



Week 6: 2 weeks of treatment with PICO™ sNPWT

Exudate level and consistency: Low and thin

Wound size (length x width x depth): 4.2cm x 1cm x 0.2cm

Tissue type: Granulation

Surrounding skin: Healthy.

Wound contact layer: None required

PICO dressing used and size: PICO™ 7 sNPWT 10cm x 20cm

Additional treatment: NO-STING SKIN-PREP™ applied to surrounding dressing

Treatment plan: Continue PICO™ 7 sNPWT for an additional week to achieve the planned outcome of complete healing.

CASE 4: GRADE 4 SACRAL PRESSURE ULCER/INJURY

Author: Hayley Ryan, WoundRescue, Wound Clinical Nurse Consultant, Australia and New Zealand

PATIENT PRESENTATION AND HISTORY

- A 71-year-old, male with a history of Alzheimer's disease, posterior cortical atrophy, frontal lobe dysfunction and depression
- He had become bed- and chair-bound due to unrelieved pressure that had caused a grade 4 sacral pressure ulcer that had been present for 8 months
- The patient's non-compliance with advice to stay off the wound and care home non-compliance with side-to-side repositioning of the patient had exacerbated his ulcer
- The patient had experienced a decrease in quality of life due to the pain caused by the pressure ulcer; he rated his pain level as 8 out of a maximum of 10.

WOUND PRESENTATION

- **Wound size:** 6cm (length) x 5cm (width) x 10cm (depth)
- **Wound bed:** Rolled and macerated
- **Surrounding skin:** Healthy
- **Consistency and exudate level:** High and thick.

MANAGEMENT PLAN AND CLINICAL OUTCOMES

After sharp debridement of the wound, as the wound was deep and producing a high volume of exudate, the wound was filled with foam filler and RENASYS™ tNPWT started on a variable pressure setting of -120mmHg.

- **NPWT:** RENASYS™ tNPWT
- **Filler:** Foam filler required due to depth of wound
- **Pressure setting:** Variable at -120mmHg
- **Planned dressing change frequency:** Every 3 days.

The patient found the variable pressure setting uncomfortable, so after 48 hours, it was decided to switch to continuous -120mmHg pressure for the remainder of the time RENASYS™ tNPWT was used. By week 4, the level of odour decreased considerably. The patient was very pleased with progress towards healing and keen to continue with RENASYS™ tNPWT.

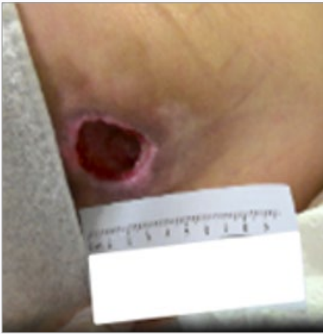Exudate remained high in volume until week 5, when it was moderate; but its consistency remained thick at this time. There was considerable improvement noted on week 7, when there was little exudate and it was thin in consistency. At this point in time, the wound was healing well, foam filler was discontinued, and the method of NPWT changed to PICO™ 7 sNPWT.

A week later, the wound had completely healed, and PICO™ 7 sNPWT was discontinued as the desired treatment outcome had been achieved.

CONCLUSION

NPWT use resulted in the complete resolution of the patient's chronic, grade 4 pressure ulcer in under 2 months without the need for hospital admission. The size and depth of the wound decreased every week, except on week 4 when an issue with the application of foam filler over the area surrounding the wound bed was found to be causing the skin to break down.

As a result of successful treatment, the patient's quality of life improved, as he was no longer in pain and felt able to join in with activities within the aged care home where he resided.



Week 2: 2 weeks of treatment with RENASYS™ tNPWT

Exudate level and consistency: High and thick

Wound size (length x width x depth): 5cm x 4cm x 6cm

Tissue type: Granulation

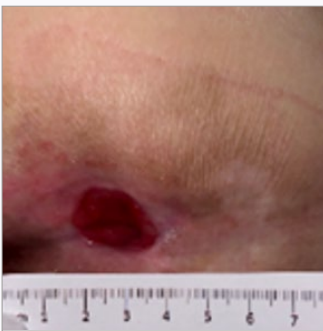
Surrounding skin: Rolled.

Filler: Foam filler

Pressure setting: Continuous at -120mmHg

Planned dressing change frequency: 3 days

Treatment plan: As per the OneNPWT decision tree, continue RENASYS™ tNPWT.



Week 5: 5 weeks of treatment with RENASYS™ tNPWT

Exudate level and consistency: Moderate and thick

Wound size (length x width x depth): 2cm x 1.5cm x 1cm

Tissue type: Granulation

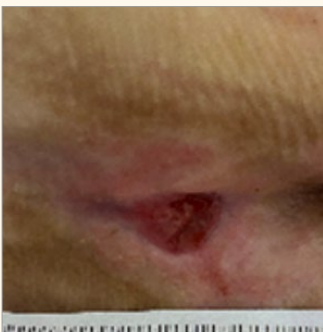Surrounding skin: Rolled, improving.

Filler: Foam filler

Pressure setting: Continuous at -120mmHg

Planned dressing change frequency: 3 days

Treatment plan: As per the OneNPWT decision tree, continue RENASYS™ tNPWT until the wound is suitable for PICO™ 7 sNPWT.



Week 7: 1 week of treatment with PICO™ sNPWT

Exudate level and consistency: Low and thin

Wound size (length x width x depth): 1cm x 1cm x 0.6cm

Tissue type: Granulation noted

Surrounding skin: Improved.

Filler: No foam filler required

PICO dressing used and size: PICO™ 7 sNPWT 10cm x 20cm

Treatment plan: Continue PICO™ 7 sNPWT for an additional week to achieve the planned outcome of complete healing.

CASE 5: DEEP THIGH ABSCESS

Author: Li Zongxian, Consultant Orthopaedic Surgeon, Singapore

PATIENT PRESENTATION AND HISTORY

- A 26-year-old woman with no noted past medical history
- She had a left inner thigh abscess that initially started off as a scratch. Her GP had prescribed antibiotics to resolve the abscess, however, after 5 days there was no improvement
- When the patient attended hospital for treatment, the abscess was producing a moderate amount of exudate.

WOUND PRESENTATION

- **Wound size:** 4.8cm (length) x 3.7cm (width) x 1.5cm (depth)
- **Wound bed:** Healthy
- **Surrounding skin:** Slight erythema
- **Consistency and exudate level:** Moderate and thin.

MANAGEMENT PLAN AND CLINICAL OUTCOMES

The young woman's thigh abscess was assessed, and it was decided that surgery was required. Following debridement, drainage of the abscess and saucerisation, it was decided to pack the debridement cavity defect with foam filler and start RENASYS™ tNPWT at -120mmHg continuous negative pressure. ACTICOAT™ FLEX 3 Dressing was applied as a wound contact layer to reduce the risk of infection.

- **NPWT:** RENASYS™ tNPWT
- **Filler:** Foam filler
- **Wound contact layer:** ACTICOAT™ FLEX 3 Dressing
- **Pressure setting:** Continuous at -120mmHg
- **Planned dressing change frequency:** Every 3 days.

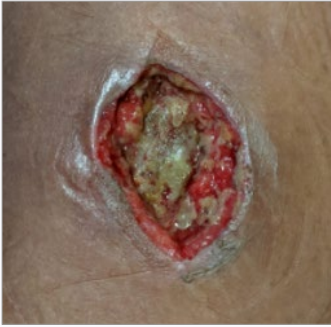The patient's treatment was moved from the acute to the outpatient setting after 2 days. Treatment with RENASYS™ tNPWT, foam filler and ACTICOAT™ FLEX 3 Dressing was continued for 2 weeks and was applied by the clinic nurse.

After two weeks, there was sufficient granulation tissue present in the wound bed to transition from RENASYS™ tNPWT to PICO™ 7 sNPWT. As the wound's depth had decreased to 0.5 cm, the foam filler was discontinued at this point.

By week 4, PICO™ 7 sNPWT was discontinued as the surgical cavity defect had filled in. REPLICARE™ Hydrocolloid Wound Dressings were applied as part of the patient's ongoing treatment plan.

CONCLUSION

The use of the OneNPWT decision tree for this patient enabled earlier discharge to the outpatient clinic, with the most appropriate device being selected based on the depth, size and exudate level of the wound as it progressed towards healing. Over the 29-day course of NPWT, the majority of which was in the outpatient setting, the wound cavity filled in and the wound area decreased to less than a quarter of its initial size. The nurse and patient were pleased with the selection of treatment and the progression towards healing.



Week 1: 1 week of treatment with RENASYS™ tNPWT

Exudate level and consistency: Moderate and thin

Wound size (length x width x depth): 4.5cm x 4cm x 1cm

Wound edge: Viable

Tissue type: Exposed subcutaneous fat and fascia

Surrounding skin: Slight maceration.

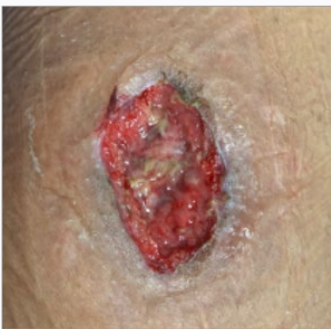Filler: Foam filler

Wound contact layer: ACTICOAT™ FLEX 3 Dressing

Pressure setting: Continuous at -120mmHg

Planned dressing change frequency: 3 days

Treatment plan: As per the OneNPWT decision tree, continue RENASYS™ tNPWT.



Week 2: 2 weeks of treatment with RENASYS™ tNPWT

Exudate level and consistency: Low and thin

Wound size (length x width x depth): 4cm x 2.5cm x 0.5cm

Wound edge: Viable

Tissue type: Granulation, minimal slough

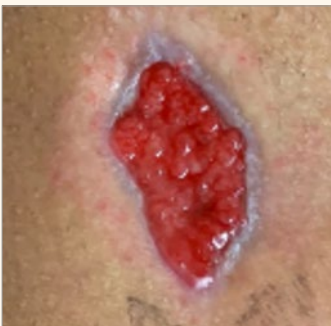Surrounding skin: Healthy.

Wound contact layer: ACTICOAT™ FLEX 3 Dressing

Pressure setting: Continuous at -120mmHg

Planned dressing change frequency: 3 days

Treatment plan: As per the OneNPWT decision tree, the patient was switched to PICO™ 7 sNPWT because foam filler was no longer required and the depth of the wound was decreasing.



Week 4: 2 weeks of treatment with PICO™ sNPWT

Exudate level and consistency: Low and thin

Wound size (length x width x depth): 3cm x 1cm x 0cm

Wound edge: Healthy

Tissue type: Healthy granulation

Surrounding skin: Healthy.

PICO dressing used and size: PICO™ 7 sNPWT 15cm x 15cm

Treatment plan: Discontinue PICO™ 7 sNPWT and apply REPLICARE™ Dressing as part of the patient's ongoing treatment plan.

CASE 6: INFECTED FOOT WOUNDS

Author: Sathappan Sathappan, Medical Director and Orthopaedic Surgeon, Singapore

PATIENT PRESENTATION AND HISTORY

- A 66-year-old woman with known type 2 diabetes, hypertension, obesity and a previous total knee arthroplasty
- She sustained a small scratch over her right foot, which became itchy. She then developed a fever that persisted intermittently over 3–4 days, during which the foot infection worsened, and a second, parallel wound had developed
- On presentation at the clinic, she was diagnosed with cellulitis of the right foot and anterior ankle with erythema ascending anteriorly to the mid-calf.

WOUND PRESENTATION

- **Wound size:** Wound A: 2cm (length) x 0.5cm (width) x 0.5cm (depth); Wound B: 3cm (length) x 2cm (width) x 0.5cm (depth)
- **Wound bed:** Healthy
- **Surrounding skin:** Healthy
- **Consistency and exudate level:** High and thick.

MANAGEMENT PLAN AND CLINICAL OUTCOMES

The patient's wounds had considerably increased in size and depth since the initial scratch. It was decided to debride the wounds in theatre and start RENASYS™ tNPWT to reduce the swelling and encourage the wounds to fill in. Both wounds were packed with foam filler and covered with ACTICOAT™ FLEX 3 Dressing to tackle infection at a local level. A single tNPWT portal was used to bridge both wounds and applied at a continuous pressure of -120mmHg.

- **NPWT:** RENASYS™ tNPWT
- **Filler:** Foam filler
- **Wound contact layer:** ACTICOAT™ FLEX 3 Dressing
- **Pressure setting:** Continuous at -120mmHg
- **Planned dressing change frequency:** Every 3 days.

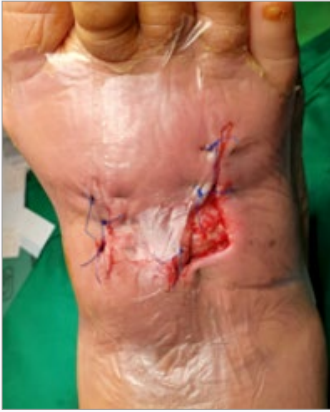One week after starting RENASYS™ tNPWT, the smaller of the two wounds had made good progress towards healing and the edges were healthy, so the wound was closed with several stitches. The bed of the remaining wound had started to granulate and the edges were closer together than on day 1 as the surrounding tissue was less inflamed. Stitches were added to encourage closure. The wound was packed as before with foam filler and ACTICOAT™ FLEX 3 Dressing was discontinued.

A week later, the OneNPWT decision tree guided the decision to discontinue the use of the foam filler and switch treatment from RENASYS™ tNPWT to PICO™ 7 sNPWT as the wound was filling in and was superficial. The patient's care was transferred to the outpatient department and the dressing change frequency extended to once a week.

1 week after starting PICO™ 7 sNPWT, the desired treatment outcome of managing the wound and exudate had been achieved, therefore, PICO™ 7 sNPWT was discontinued. The wound continued to reduce in size over the next 2.5 weeks using simple low adherent dressing and had completely healed 6 weeks after commencing NPWT.

CONCLUSION

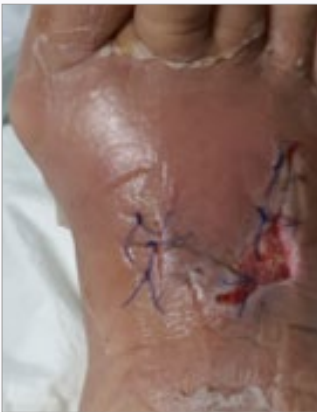The patient received 18 days of NPWT with the aim of reducing exudate and supporting wound closure.



Week 1 of treatment with RENASYS™ tNPWT

Exudate level and consistency: Low and thin
Wound size (length x width x depth): 3cm x 1.5cm x 0.5cm
Wound edge: Healthy
Tissue type: Granulating
Surrounding skin: Inflamed, oedematous and red, but improved from day 1.

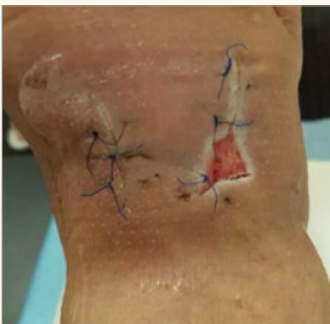Filler: Foam filler
Wound contact layer: None required
Pressure setting: Continuous at -120mmHg
Planned dressing change frequency: 3 days
Treatment plan: As per the OneNPWT decision tree, continue RENASYS™ tNPWT.



Week 2: 2 weeks with RENASYS™ tNPWT

Exudate level and consistency: Low and thin
Wound size (length x width x depth): 3cm x 1cm x 0.3cm
Wound edge: Healthy
Tissue type: Granulating
Surrounding skin: Inflamed, oedematous and red, but improved from week 1.

Filler: None required
Pressure setting: Continuous at -120mmHg
Planned dressing change frequency: Weekly
Treatment plan: As per the OneNPWT decision tree, step across to PICO™ 7 sNPWT.



Week 3: 1 weeks of treatment with PICO™ sNPWT

Exudate level and consistency: Low and thin
Wound size (length x width x depth): 3cm x 1cm x 0.1cm
Wound edge: Healthy
Tissue type: Granulating
Surrounding skin: Healthy.

PICO dressing used and size: PICO™ 7 sNPWT 10cm x 20cm
Treatment plan: Discontinue PICO™ 7 sNPWT, treat wound with simple dressing and refer patient to vascular services for oedema.

CASE 7: TRAUMA TO LEFT CALF

Author: Edmund Leung, Surgical Oncologist and General Surgeon, New Zealand

PATIENT PRESENTATION AND HISTORY

- Female farmer in her 50s; high body mass index
- She sustained a large trauma wound to her left calf after falling and landing on concrete at her farm
- She lives very remotely, so did not seek medical attention immediately. She self-treated with various ointments and bandaged the leg
- After 2 months she attended the emergency department with signs of systemic infection and sepsis; the wound had become larger, more inflamed and more painful.

WOUND PRESENTATION

- **Wound size:** 13cm (length) x 9cm (width) and deep to fascia (after debridement)
- **Wound bed:** Necrotic and sloughy
- **Surrounding skin:** Ascending cellulitis and sepsis
- **Consistency and exudate level:** Thick and at high level.

MANAGEMENT PLAN AND CLINICAL OUTCOMES

The woman's calf was examined, and it was determined that surgery was necessary. Debridement of necrotic tissue was performed under general anaesthesia and intravenous antibiotics were used to manage sepsis and infection. Because the patient was young and had no other comorbidities, the risk of ischaemic limb was ruled out. Due to the deep nature of the wound after debridement, the wound was packed with foam filler and RENASYS™ tNPWT was initiated on a continuous pressure setting of -120mmHg.

- **NPWT:** RENASYS™ tNPWT
- **Filler:** Foam filler required due to depth of wound
- **Pressure setting:** Continuous at -120mmHg
- **Planned dressing change frequency:** 5 days.

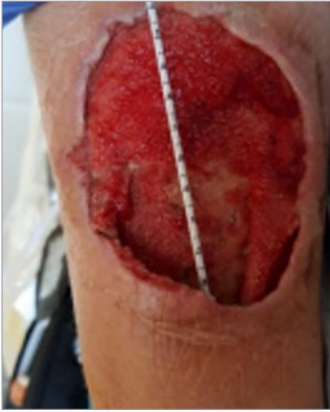Although the patient was keen to stop RENASYS™ tNPWT so she could return to work on the farm, the clinician talked to her about the benefits of continuing with treatment and, with the pressure setting reduced to -80mmHg, she agreed.

By week 2, the recesses of the wound had healed, and it was determined that the wound was healing well. The foam filler was discontinued, and the NPWT method was changed to PICO™ sNPWT using the OneNPWT clinical decision tree.

After one week, PICO™ sNPWT was discontinued as the cavity had filled with granulation tissue and there was minimal exudate.

CONCLUSION

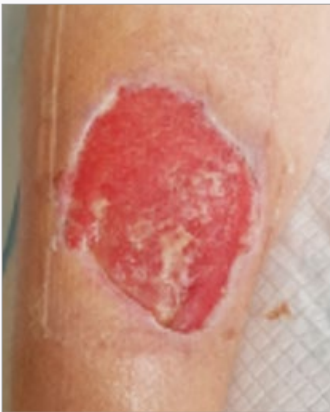RENASYS™ tNPWT and PICO™ sNPWT were used for 2 weeks and 1 week, respectively. During this time, sepsis resolved, the wound bed composition improved, and the depth of the wound reduced to skin level. Before treatment, the wound and patient's health had been deteriorating for 2 months. In just 21 days of active treatment, the wound was on a healing trajectory. Using PICO™ sNPWT increased the patient's mobility compared to RENASYS™ tNPWT, and the treatment continued to improve the wound bed composition and reduce the size of the wound.



Week 1: 1 week of treatment with RENASYS™ tNPWT

Exudate level and consistency: Moderate and thin
Wound size (length x width x depth): 11cm x 8cm x up to 2cm in certain areas
Tissue type: Granulation tissue and slough
Surrounding skin: Healthy.

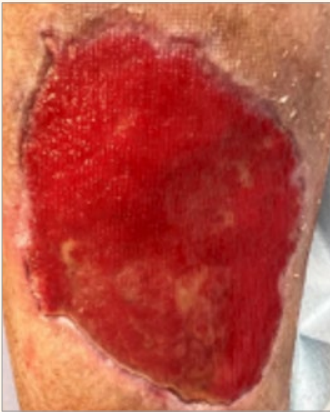Filler: Foam filler
Pressure setting: Continuous at -80mmHg after discussion with the patient
Planned dressing change frequency: 3-5 days
Treatment plan: As per the OneNPWT decision tree, continue RENASYS™ tNPWT.



Week 2: 2 weeks of treatment with RENASYS™ tNPWT

Exudate level and consistency: Low and thin
Wound size (length x width x depth): 10cm x 6cm x up to 0.2cm
Tissue type: Largely granulation tissue almost to the level of the skin
Surrounding skin: Healthy.

Filler: No filler required
Pressure setting: Continuous at -80mmHg
Planned dressing change frequency: 1 week
Treatment plan: As per the OneNPWT decision tree step across to PICO™ sNPWT as wound depth is now less than 2cm and the patient is keen to be more mobile.



Week 3: 1 week of treatment with PICO™ sNPWT

Exudate level and consistency: Minimal and serous
Wound size (length x width x depth): 8cm x 5cm x up to 0cm
Tissue type: Mostly granulated
Surrounding skin: Healthy.

PICO dressing size: 15cm x 15cm
Treatment plan: Discontinue PICO™ sNPWT and refer the patient to a general practitioner for ongoing monitoring and wound care.

CASE 8: VENOUS ULCER ON CALF

Author: Edmund Leung, Surgical Oncologist and General Surgeon, New Zealand

PATIENT PRESENTATION AND HISTORY

- 72-year-old woman with hypertension and well controlled non-insulin-dependent diabetes
- She had a non-healing venous leg ulcer, that had been present for more than 12 months, which had been managed with the repeated application of compression bandages by the primary care team
- Over time, the venous ulcer had become larger and more painful, and on presentation at the outpatient clinic it was producing copious exudate. She reported that the ulcer was significantly negatively impacting her quality of life.

WOUND PRESENTATION

- **Wound size:** 9cm (length) x 5cm (width) x 0.3cm (depth)
- **Wound bed:** Sloughy
- **Surrounding skin:** Oedematous and ischaemic
- **Consistency and exudate level:** Moderate and thick.

MANAGEMENT PLAN AND CLINICAL OUTCOMES

The size of the wound and the presence of moderate level of exudate resulted in the wound care nurse selecting a 10cm x 20cm PICO™ sNPWT dressing to achieve rapid granulation and healing by secondary intention. No filler was required, as the wound was shallow. The patient was advised to continue to elevate her leg while undergoing PICO™ sNPWT and to return to the outpatient clinic on a weekly basis for dressing changes.

- **NPWT:** PICO™ sNPWT
- **Filler:** No foam filler
- **PICO dressing size:** 10cm x 20cm
- **Planned dressing change frequency:** Weekly.

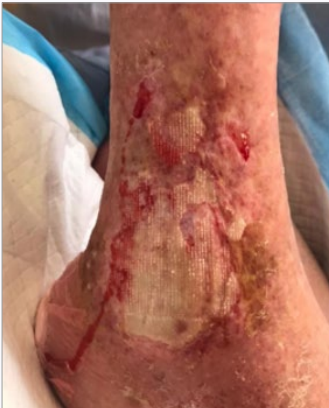The patient's ulcer was debrided to remove any slough present at each dressing change. Dressing changes proved challenging, as the wound care nurse found it difficult to get a seal as the ulcer was located at the gaiter area near the malleolus. During dressing change, the patient did complain of some mild discomfort but this was not significant enough to not proceed with PICO™ sNPWT.

In the 6 weeks during which the patient underwent PICO™ sNPWT, the exudate was well managed, the wound became progressively smaller, and the area covered by granulation tissue increased. At the time PICO™ sNPWT was discontinued, 95% of the ulcer was covered in granulation tissue and there was very little exudate. Four layer compression bandages were restarted, and the patient was advised to continue to elevate the affected leg.

At the 18-week review the ulcer had virtually sealed, leaving a scar, and there were haemosiderin deposits. The ulcer was no longer causing any pain. The patient was pleased with the outcome and felt her quality of life had significantly improved.

CONCLUSION

Over a period of more than a year prior to treatment with PICO™ sNPWT, the patient's leg ulcer had progressively deteriorated, causing greater pain and high exudate levels. The use of PICO™ sNPWT for 6 weeks resulted in significant progress towards healing, with increasing granulation tissue and decreasing exudate volume and viscosity over time. At follow-up, the ulcer had virtually healed, and the patient felt her quality of life had improved significantly because of treatment.



Start of treatment with PICO™ sNPWT

Exudate level and consistency: Moderate and thick

Wound size (length x width x depth): 9cm x 5cm x 0.3cm

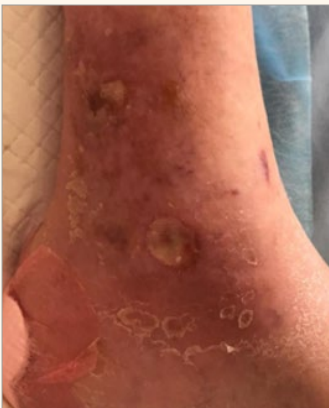Tissue type: Sloughy

Surrounding skin: Oedematous and ischaemic.

Filler: No filler required as wound was shallow

PICO dressing size: 10cm x 20cm

Treatment plan: As per the OneNPWT decision tree, continue PICO™ sNPWT.



18-week review: 6 weeks of treatment with PICO™ sNPWT

Exudate level and consistency: None

Wound size (length x width x depth): Sealed wound

Tissue type: Scar tissue

Surrounding skin: Haemosiderin deposits.

PICO dressing size: 10cm x 20cm

Treatment plan: As per the OneNPWT decision tree, discontinue PICO™ sNPWT after 6 weeks as ulcer had virtually sealed.



A Wounds International publication

www.woundsinternational.com