

## Ten top tips: wound photo documentation



**Authors:**  
Nancy Estocado and Joyce Black

**W**ound images provide a visual reference that is not matched by memory or the written word (Swann, 2010). Wound photography communicates a universal language that can easily translate across the continuum of care and to the stakeholders involved (patient, family/carers, healthcare professionals and the agencies funding treatment). Wound images can provide a timeline for plotting the status of the wound over a period of time.

Wound image technology has evolved and is no longer the role of an expert photographer. These top tips provide assistance to guide the unskilled and skilled photographer to standardise the process when obtaining useful wound images. However, training staff members on how to consistently photograph wounds is crucial (Bradshaw et al, 2011).

Wound images, when combined with the bedside assessment and information gathered for wound history, anatomy, tissue types and touch/view details (HATT), avoid the 'guess method' and drive evidence-based algorithms for the correct classification of wounds and their severity levels while plotting a timeline. Wound care documentation may assist with improved details about the actual condition of the wound on admission, its occurrence and discharge. Standardised wound photo documentation can possibly provide guidance with wound care product selection and services. Consider wound photographic documentation as a quick method for mapping out a timeline for facility discovery on admission or occurrence and for reporting the progression or regression of wound status.

There are three types of wound image work flows:

- Digital camera/printing station/paper photo mount/scanning into the electronic medical record (EMR)
- Digital camera/tethering or uploading into the EMR
- Smartphone app/filing to the EMR.

This article will focus on digital consumer cameras and smartphone digital cameras, with little time spent on paper methods [Figure 1].

**1** **Develop a guideline for your facility on the timing of wound photo documentation:**  
Consider photographic documentation for

all pressure injury wounds that are found on initial skin assessment for proof of presence on admission (within the first 24 hours of admission to a facility). Depending on your knowledge of where and when pressure injury begins in your facility, starting points such as in the emergency department may be helpful. Photographing other types of wounds should also be considered. It is suggested that photographs are taken of wounds prior to discharge for onward communication and as a record of skin status at the point the patient left your facility.

If the patient was admitted to your facility in the past, prior photographic documentation can assist with determining the correct cause of the wound and timeline for occurrence. Refer to the patient's historic photographic gallery to view all wound photos taken for all admissions, in order to more accurately determine wound status (regression or progression to healing).

There will be times when a patient's wound photo has been taken and the patient is no longer in the facility to combine bedside assessment information with photographic information (best practice). The wound image is a part of the medical record and needs to be accompanied by a completed report. In these situations, consider completing the report using the same HATT methodology for assessment but declare in your report that the assessment was completed from the photograph alone and that drainage and touch details are not valid. For example, an accurate photographic report can be obtained from a photograph alone if the patient's history includes poor mobility, the anatomy is the sacral area, and the tissue type viewed in the photo is exposed bone. In our professional experience, touch details of bones are hard to obtain. A photograph of a stage 4 sacral pressure injury, is an important part of the medical record, even if the wound is assessed from the photograph alone [Figure 2].

Recommended times/points of care at which to take photographs are:

- Admission: the first wound photograph should be taken within 24 hours of admission
- On initial discovery: this will be the first wound photo taken, but not within the 24-hour admission window. Depending upon the age of the wound, it may provide evidence that the wound was present on

*Nancy Estocado is Supervisor of Acute Care Physical Medicine and Advanced Wound Care, Sunrise Hospital in Dallas, Texas, US; Joyce Black is Associate Professor, College of Nursing, University of Nebraska Medical Center, Omaha, Nebraska*

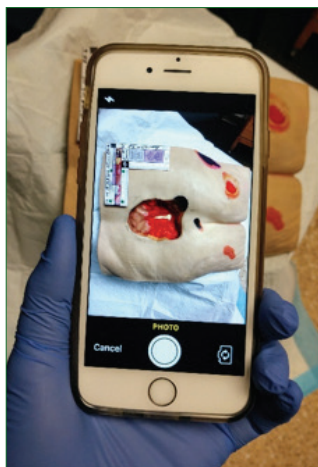


Figure 1. A smartphone app (above) or digital camera should be used consistently to photograph wounds.

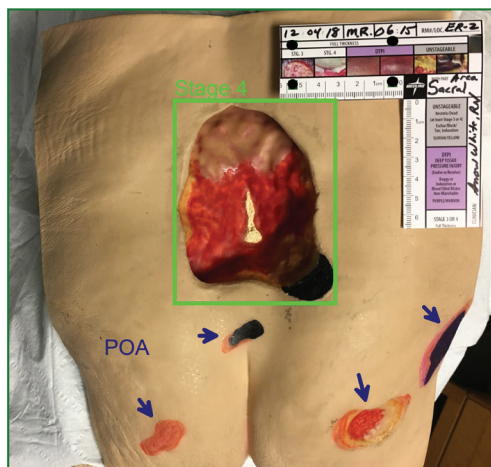


Figure 2. A photograph forms an important part of the medical record, even if an assessment is carried out from the photograph alone.

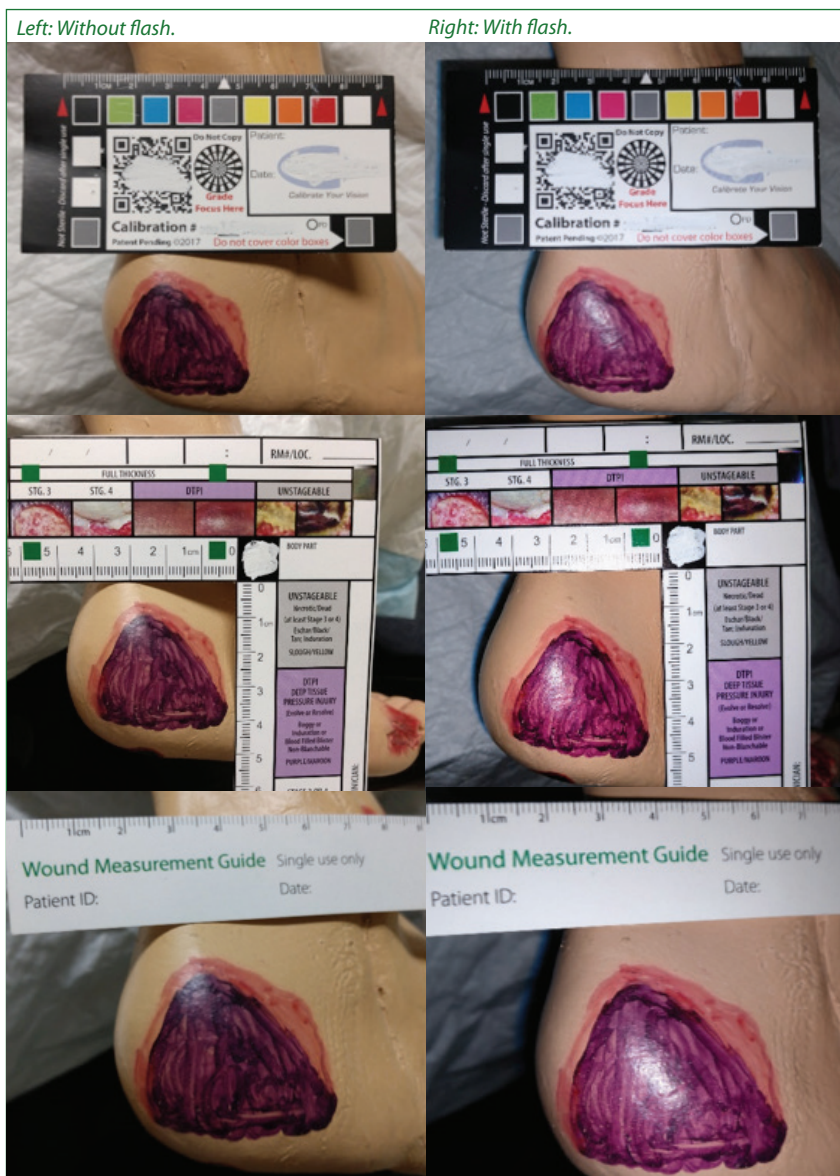


Figure 3. Consider standardising photography methods and aim to achieve natural colours in normal lighting, particularly for intact skin.

admission. An occurrence wound photo report should be completed if the wound developed in the facility

- Follow-up: sequential photograph(s) taken of the wound, usually weekly. It is recommended that the previous photographs are examined and the same reference point rules used for a fair surface area comparison to determine changes in wound size
- Discharge: image(s) taken on the day of discharge.

It is recommended that if there is more than one wound present that wounds are numbered 1, 2, 3, etc. This number system should be continued with subsequent photographs, including re-admission photos.

**2** Develop a system that meets facility security requirements for the protection of privacy: Consider using camera technology devices that can scan the patient's armband whenever possible to prevent any patient identification mistakes and eliminate any protected health information (PHI) from being lost or discarded. The photo then needs to be uploaded or placed on a form that has complete PHI for the medical record. If patient's armband cannot be used as identification, the patient must be identified in another way, such as by using the patient identification number. The location of the identifying information varies with the system used, such as the patient's initials, the date and time, the body part and the room the patient was located in (if he or she is an inpatient) and the name of the photographer.

Determine the best method for securely uploading the photographs into the patient's EMR. Pictures should not be stored on the user's smartphone gallery. If the photographs become part of a paper record, be certain to delete any copies in your camera. Update policies to reflect the safe transfer of photographs to the medical record (Wiedemann, 2010).

When developing a policy or procedure for taking and managing medical photographs, the following additional information needs to be included:

- Discarding duplicate photos or photos that have no ID or poor-quality photos with no value.
- When a photographic document may need the addition of physical examination findings
- How and when to notify the healthcare provider
- How to label the photograph.

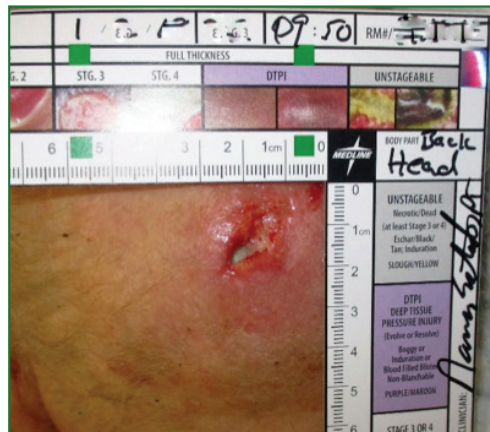

Figure 4. Consider using flash to capture important details that are missing, such as bone.

### 3 Standardise the consent to photograph:

Consent for photography should be a component of the admission consent process. If your facility is not a teaching facility, you should be clear with the patient that the photos will be used for documentation and may be used for teaching or publication. Even though written consent is obtained with admission, verbal consent should be obtained with each subsequent photograph. Patients should understand that photographs taken and used within legal healthcare documentation are owned by the agency or institution.

### 4 Use a consumer digital camera or a facility-owned smartphone camera:

Consider standardising practice and using the camera factory settings, which are generally suited for proper photographic quality for viewing and storing in the EMR [Figure 3]. Photographs should not be manipulated; it is better to let the 'usual and customary defaults' be used. Suggest using the timer shutter button option on the camera device, as this allows you to be as steady as possible when the shutter is activated 5–10 seconds later.

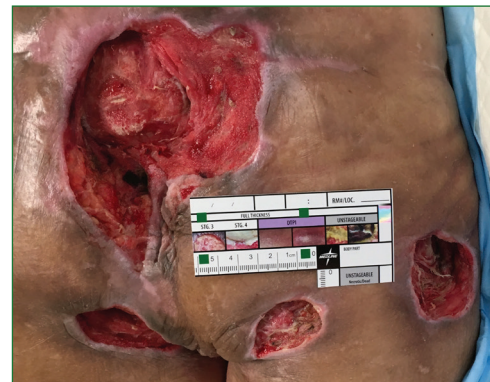


Figure 6. Where speed of documentation is important, a single photograph can capture multiple wounds on the same body part/area, such as the sacral/buttocks area.

Take photos with no flash when possible as an attempt to standardise your method. Consider different lighting situations when taking a wound photo, with the goal of achieving natural colours in normal lighting situations. This is important for intact skin when assessing for pinks, reds and purples that can look more or less severe than they really are in different lighting situations.

Consider taking a second photograph using a flash when important tissue type details are missing, such as when tissue depth cannot be picked up without the flash. A flash may be required to capture the image of an exposed bone, due to the shadowing effects of wound edges in a deep wound [Figure 4].

### 5 Consistently photograph with the patient in the same position:

Use the same wound positioning technique every time, as set forth in the initial photo document. Try to place the patient in a neutral position [Figure 5] without pulling on the body part, as this can distort the location of the wound. Using the same position allows you to determine changes in the wound over time, rather than wondering whether you are looking at the same wound.

Place the patient identification information and measurement device in the wound photo for surface area calculations. The device shown in Figures 4–9 is the NE1 Wound Assessment Tool, which is available from Medline, and has been shown to improve the accuracy of wound assessment (Lilly et al, 2014; Young et al, 2017).

Consider taking a photograph of the entire body or limb — around 1 m (3 feet) from the wound [Figure 6] — then take close-ups from around 30 cm (1 foot) as needed to capture tissue type details and specific single wound measurements so that the length and width

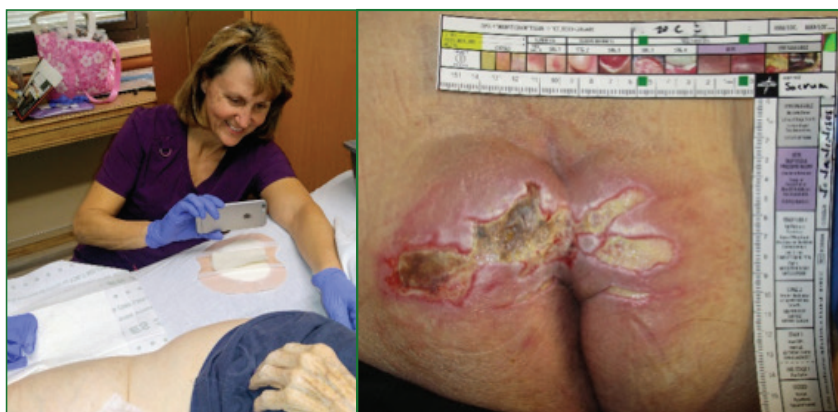

Figure 5. Consistently photograph the patient in the same position.

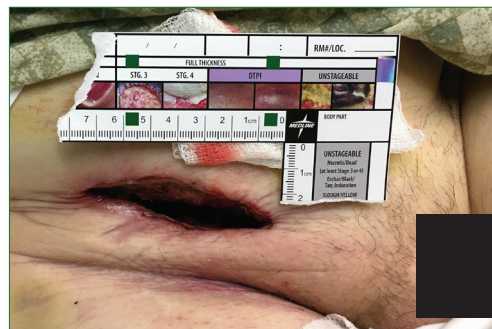


Figure 7. Remove distractions from the wound and nearby area and obscure genitals to maintain dignity.

in centimetres can be determined (Bloemen et al, 2016).

**6 Remove distractions from the wound and surrounding area:** Remove extraneous items from the photograph. If possible, use a blue background to enhance the colour contrast. If the body part must be held by another provider, do not include identifiers (such as their name tags or faces) in the photograph.

Clean the wound of debris or drainage or stool, so that the wound bed can be clearly seen. Unless the wound is on the face or perineum, obscure the face and genitals to maintain dignity [Figure 7].

**7 Consider taking measurements for length and width surface area directly from the photo:** Apply measurement devices for both length and width [Figure 8]. Using only one ruler can lead to distorted measurements. It is best to use a non-bendable measurement tool to improve consistency, as some grids and paper measuring devices bend to fit the body, and this can lead to inaccurate measurements as some systems compute the area of the wound using the grid. One-dimensional measuring tools will lead to an estimated measurement for the adjacent side.

Take the photo perpendicular to the measurement device and not the wound for proper calibration of size. Place the measurement devices in the same area for follow-up photographs.

Measure from wound tissue edge to wound tissue edge. Wound length is measured from head to toe (from 12 to 6 on a clock face). Width is measured from side to side, or from 3 to 9 o'clock. Include inflamed areas and periwound directly related to the wound being measured. Do not include pink resurfaced or repaired scar tissue in the measurements.

Always use the same method each time the wound is measured. Consider taking more advanced measurements for depth, tunnelling and undermining. These measurements should be performed by trained wound champions or experts.

**8 Combine other wound assessment findings with the wound photos:** There are limitations when assessing a wound from an image alone. The bedside assessment captures certain wound character details that cannot be assessed well from a photograph. More valid results are captured from touch, such as when performing a blanch test, detecting soft/

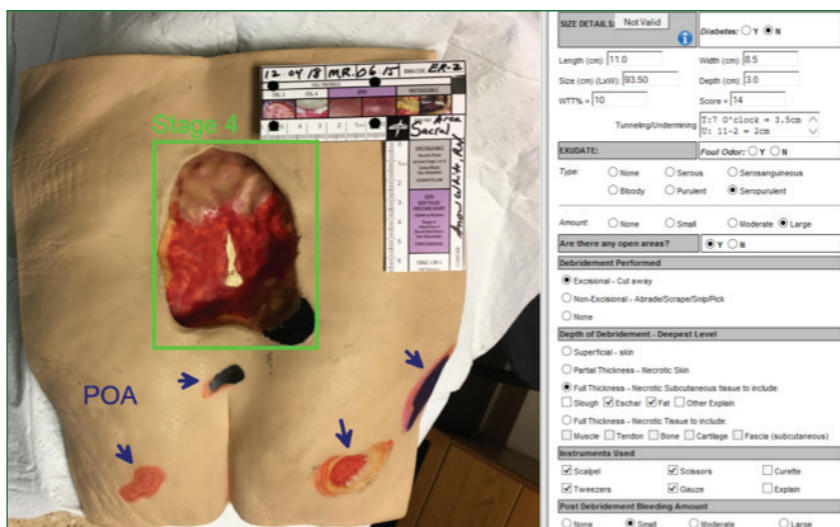


Figure 8. Consider taking measurements for surface area (length x width) directly from the photograph.

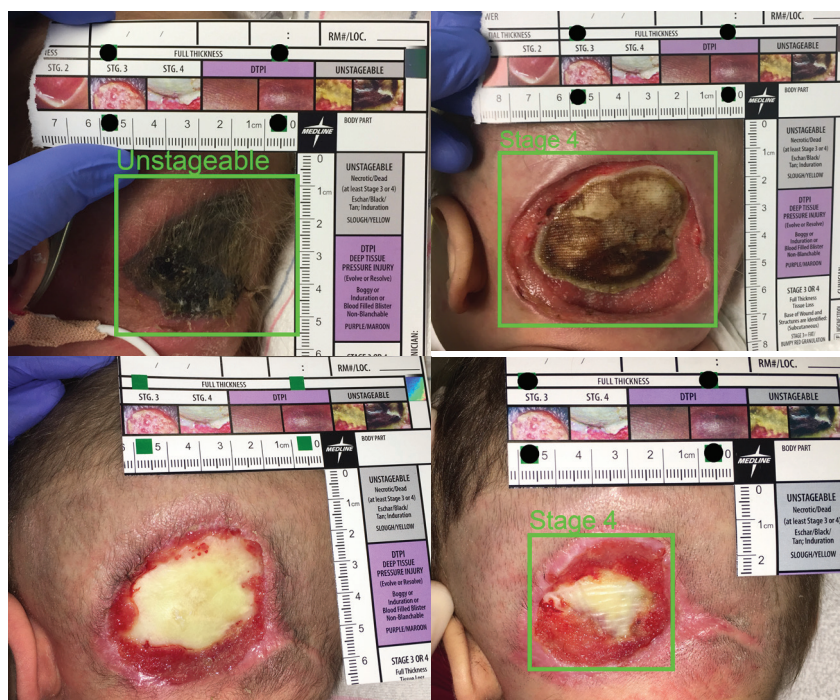


Figure 9. Take photos before and after debridement to validate documentation.

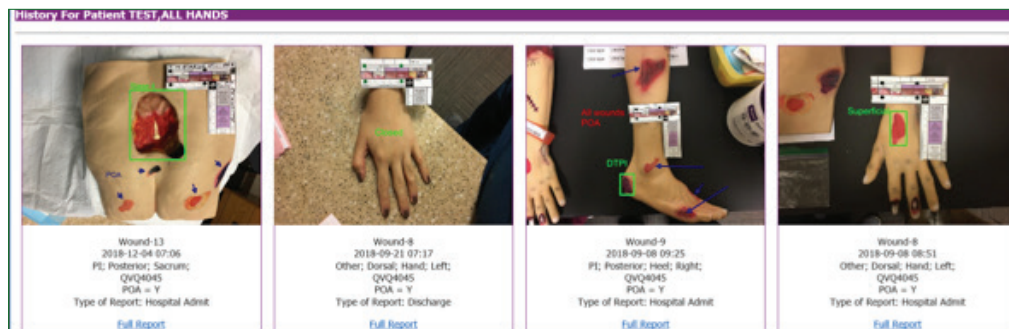

Figure 10. Refer to historical photos of the wounds, as this can assist with wound status (regression or progression).

firm and warm/cool. These touch details are important for evidence-based documentation algorithms for final determination of the wound severity. It is suggested that staff members know the limitations of wound documentation that does not include blanch test, temperature, and the amount of exudate.

## 9 Take photos before and after debridement:

Photographs taken before and after selective sharp debridement of necrotic eschar tissue [Figure 6]. Such images are very helpful to validate documentation of unstageable pressure injuries present on admission, moving to a new wound classification, and for wounds identified as present on admission.

## 10 Consider alternative methods for instances when devices or equipment may be unavailable:

If utilising a smartphone app that has internet connection requirements, consider having a downtime procedure in place that can be used until internet connection is re-established. It is wise to have a digital camera and a colour printer as backup for when downtime may exceed 24 hours to ensure important information is captured about wounds that are present on admission.

## Conclusion

Wound image documentation is becoming standard in practice. The key to ensuring good quality, useful documentation is in standardising the how photographs are taken and wounds measured in your facility, so that relative changes in the same wound can be compared over time.

WINT

## References

- Bloemen EM, Rosen T, Schiroo JA, et al. Photographing injuries in acute care setting: Development and evaluation of a standardized protocol for research, forensics and clinical practice. *Acad Emerg Med* 2016; 23: 653–9
- Bradshaw L, Gregar M, Hooko G. Collaboration in wound photography competency development: a unique approach. *Adv Skin Wound Care* 2011; 24: 85–92
- Lilly D, Estocado N, Spencer-Smith, Englebright, J. Validation of the NE1 Wound Assessment Tool to improve staging of pressure ulcers on admission by registered nurses. *J Nurs Meas* 2014; 22: 438–50
- Swann G. Photography in wound care. *Nurs Times* 2010; 96: 9–12, 14–5
- Wiedemann LA. Using Clinical Photos in EHRs. *J Am Health Informat Manage Assoc* 2010; 81: 44–5
- Young DL, Estocado N, Feng D, Black J. The development and preliminary validity testing of the Healing Progression Rate tool. *Ostomy Wound Manag* 2017; 63: 32–44

*Acknowledgement: The mannequin used in this article is Seymour from VATA industries in the US.*