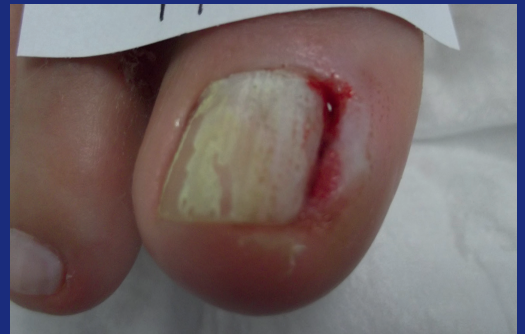
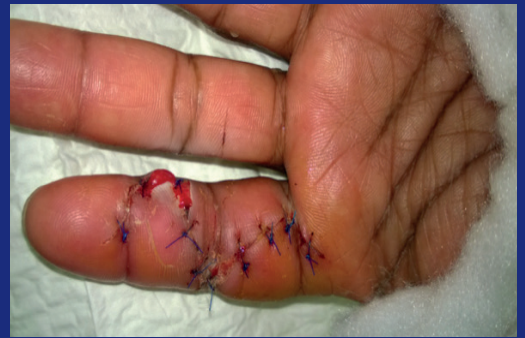
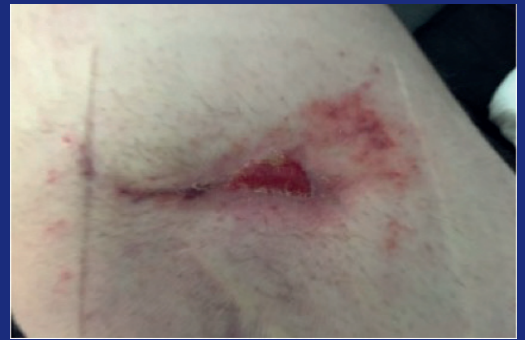INTERNATIONAL  
**CASE STUDIES**

# USING INADINE™ FOR MINOR TRAUMATIC WOUNDS: **CASE STUDIES**

CASE STUDIES SERIES 2015



This document has been jointly developed by Wounds International and Systagenix — an Acelyty company.

For further information about Systagenix please visit: [www.systagenix.com](http://www.systagenix.com)



© Wounds International 2015

**Published by:**  
Wounds International  
Cargo Works  
1-2 Hatfields  
London SE1 9PG, UK  
Tel: + 44 (0)20 7627 1510  
[enquiries@woundsgroup.com](mailto:enquiries@woundsgroup.com)  
[www.woundsinternational.com](http://www.woundsinternational.com)



The case reports presented in this document are the work of the authors and do not necessarily reflect the opinions of Systagenix — an Acelyty company.

**How to cite this document:**  
International case series: *Using INADINE™ for minor traumatic wounds: Case Studies*. London: Wounds International, 2015.

## ABOUT THIS DOCUMENT

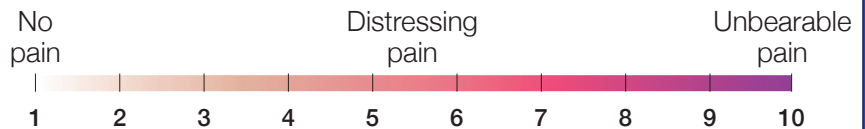This document contains a series of case reports describing the use of INADINE™ (Systagenix — an Acelyty company) in patients with a range of acute wounds (minor traumatic injuries).

Each case study was carried out for a period of 1-2 weeks, or longer if necessary, with assessment to take place on a weekly basis. A photographic record of the wound was to be taken weekly to document progress.

All patients were assessed for:

- frequency of dressing change
- improvement or deterioration to the wound, and change in wound size
- condition of the wound bed and surrounding skin
- signs and symptoms of infection
- exudate levels

Pain assessment was carried out at baseline using a visual analogue scale where 1 = no pain and 10 = unbearable pain.



The clinicians undertaking the study were asked to rate the dressing, from highly satisfied to dissatisfied, and to comment on its ease of use. Patients were also asked to rate their satisfaction with INADINE.

**DISCLAIMER:** The case studies presented here were undertaken by practising clinicians. Individual results may vary.

# INADINE: case studies

Without proper cleansing and treatment, minor traumatic (e.g. burns, abrasions, or lacerations) or post-surgical wounds may be slow to heal or become infected<sup>1</sup>. Such wounds will often be contaminated by the surroundings where an injury occurred, so infection risk is high in this type of wound<sup>2</sup>.

Minor traumatic wounds may have an increased risk of infection if:

- necrotic tissue or foreign bodies are present, particularly in the presence of hypoxia
- they occur following a long operative procedure or are contaminated during surgery
- treatment is delayed<sup>3</sup>.

Localised infection is usually characterised by classical signs and symptoms including pain, heat, swelling, erythema, and loss of function. In surgical wounds, pyrexia may appear 5 to 7 days following surgery. There may be evidence of delayed or stalled healing, abscess or malodour<sup>3</sup>. A spreading or systemic infection will display the same characteristics as local infection, but may also show extension of erythema, lymphangitis, crepitus in the soft tissues, or wound dehiscence<sup>3</sup>.

Due to this high infection risk, there is a need for appropriate topical antimicrobials to be used in minor traumatic injuries<sup>2</sup>. A topical antimicrobial should be used if localised effect is desired and the wound status allows dressing application and change without disruption to the surrounding skin structure<sup>4</sup>.

## What is INADINE?

INADINE PVP-I non-adherent dressing is a topical preparation impregnated with povidone-iodine; the dressing also contains polyethylene glycol and purified water<sup>5</sup>. INADINE has a broad-spectrum antimicrobial effect *in vitro*<sup>6,7</sup> and has been proven effective against MRSA<sup>8-10</sup>.

INADINE is designed to protect wounds even when they are infected, providing long-lasting antiseptic effect, which helps to manage infection by bacterial, protozoal, and fungal organisms. It is suitable for both adults and children, and can be used in conjunction with systemic antibiotics<sup>5</sup>. There is minimal adherence to the wound bed, which reduces the risk of damage to granulation tissue when the dressing is removed<sup>7</sup> and has been shown to reduce pain for patients in clinical practice<sup>10,11</sup>.

INADINE can be used with appropriate secondary dressings (either gauze with simple retention methods or TIELLE™, as recommended by the manufacturer), as long as it is possible to easily observe the dressing for colour change.

In this study, INADINE was to be used on minor traumatic wounds where infection was suspected or confirmed; for example, minor trauma, post-surgical wounds, or minor burns.

### BOX 1: INDICATIONS FOR INADINE

INADINE dressing is indicated for the management of ulcerative wounds and for the prevention of infection in minor burns and minor traumatic skin loss injuries.

### BOX 2: PRECAUTIONS AND CONTRAINDICATIONS FOR THE USE OF INADINE

INADINE dressings should not be used:

- where there is a known iodine hypersensitivity (allergy)
- before and after the use of radio-iodine (until permanent healing)
- if the patient is being treated for kidney problems
- in pregnant and breastfeeding women
- in cases of Duhler's herpetiform dermatitis.

INADINE dressings should be used under medical supervision:

- in patients with any thyroid disease
- in newborn babies and infants of 6 months or less (povidone-iodine may be absorbed through unbroken skin)
- to treat deep ulcerative wounds, burns or large injuries.

### BOX 3: ABOUT INADINE

- For further information about INADINE dressing, please go to: <http://www.systagenix.co.uk/our-products/lets-protect/inadine-204>

**Tips for using INADINE (from the manufacturer's Instructions for Use)****Dressing application**

- Remove the dressing from the packaging using sterile forceps
- Remove the first layer of backing paper, peel the dressing from second layer of backing paper and apply directly to the wound
- Cover and secure with a secondary dressing of choice, taking into account guidance on choice of secondary dressings

**Dressing change and removal**

- When INADINE turns white this indicates loss of antiseptic action and that the dressing should be changed — INADINE may be changed up to twice daily in the initial phase or with highly infected wounds producing high levels of exudate
- It is essential to avoid trauma to the intact skin — removal may be helped by gentle stretching of the dressing at diagonally opposite corners

**Summary of available evidence for INADINE**

Author	Publication year	Title
Boothman S	2009	Iodine white paper
Woo K, et al	2010	INADINE dressing for the management of chronic wounds
Marchal C, et al	2005	Honey vs povidone-iodine following toenail surgery
LeMesurier A, et al	2009	A case series evaluating a new povidone-iodine dressing
Campbell N, Campbell D	2013	Evaluation of a non-adherent, povidone-iodine dressing in case series of chronic wounds
Jeffcoate WJ, et al	2009	Randomised control trial of the use of three dressing preparations in the management of chronic ulceration of the foot in diabetes
Campbell N, Campbell D	2009	Product evaluation case study of povidone-iodine non-adherent for outcomes: wound pain, wound trend, cost-efficiency, and patient opinion

**References**

1. Nicks B, Ayello E, Woo K, Nitzki-George D, Sibbald R. Acute wound management: revisiting the approach to assessment, irrigation, and closure considerations. *Int J Emerg Med* 2010; 3(4): 399-407
2. Sussmann G. Innovations in topical antimicrobials. *Wounds International* 2013; 4(1): 12-4
3. World Union of Wound Healing Societies (WUWHS). *Principles of best practice: Wound infection in clinical practice. An international consensus*. London: MEP Ltd, 2008. Available from [www.mepltd.co.uk](http://www.mepltd.co.uk)
4. Swanson T, Grothier L, Schultz G. Wound Infection Made Easy. *Wounds International* 2015. Available at: [www.woundsinternational.com](http://www.woundsinternational.com)
5. Acelity. INADINE Information for Use. Data on File
6. Han KH, et al. Management of partial skin thickness burn wounds with INADINE™ dressings. *Burns* 1989; Vol.15 (6): 399-402
7. Sibbald RG, Leaper DJ, Queen D. Iodine Made Easy. *Wounds International* 2011; 2(2): s1-s6
8. Langley, SRN. INADINE wound dressings speed healing, reduce patient discomfort and cuts costs by almost 40%. *Burns* 1989; Vol 1
9. Vowden P, Cooper RA. An integrated approach to managing wound infection. Position Document: Management of wound infection. European Wound Management Association (EWMA). London: MEP Ltd, 2006
10. Balmforth V. INADINE Povidone Iodine non adherent dressing as a treatment for superficial wounds infected with Methicillin resistant *Staphylococcus aureus*. Case Study, 1996
11. Gordon J. Clinical significance of methicillin-sensitive and methicillin resistant *Staphylococcus aureus* in UK hospitals and the relevance of povidone iodine in their control. *Postgrad. Med J* 1993; 69(3):106-116
12. Campbell N, Campbell D, et al. Evaluation of a non-adherent, povidone-iodine dressing in a case series of chronic wounds. *JWC* 2013; 22(8)

# Case 1: Deroofed blister to left great toe

## Background

An 86-year-old female presented to the interdisciplinary wound clinic with a blister to her left great toe that had spontaneously burst when she accidentally knocked her toe on her walker. She has diabetes and venous disease, both of which can adversely impact wound healing and increase risk of infection.

On presentation, the wound was 1.5cm x 1.0cm with no depth. The wound bed was dehydrated, with 75% granulation tissue, and some evidence of overgranulation. The surrounding skin appeared dry. There was a low level of serosanguinous exudate and hypergranulation. The wound was considered at risk of infection, with evidence of delayed healing (the wound was 4 weeks old).

## Treatment

The patient was started on INADINE, which was covered using a secondary island dressing. Dressing changes were scheduled for twice weekly with review once a week in the clinic.

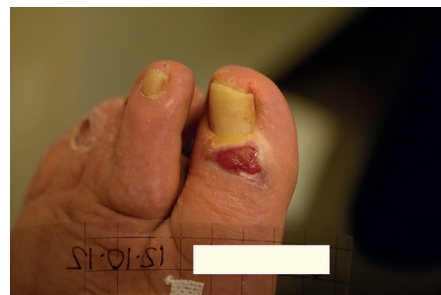At review 1 week later, although the wound size had remained the same, there was increased healthy granulation (90%). The surrounding skin was macerated (likely a result of the secondary dressing), but exudate levels remained low. The patient was very satisfied with the dressing, and it was decided to continue with INADINE and the secondary dressing regimen to progress the wound.

## Outcome

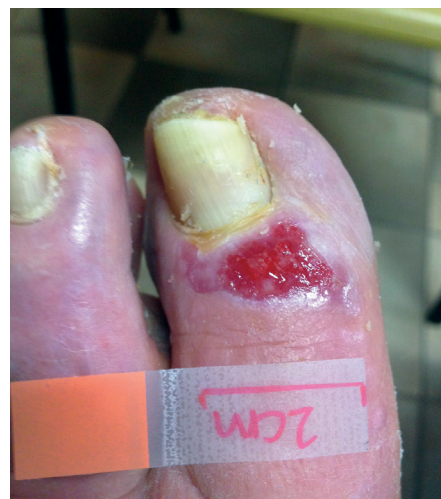The patient was reviewed 10 days later. Although the wound was slightly larger (2.0cm x 1.1cm), the wound bed appeared very clean, with 100% healthy granulation tissue.

As the surrounding skin remained macerated, it was decided to switch to a more absorbent dressing with review in 1 week. Both the clinician and patient were satisfied with the comfort and ease of use of INADINE in combination with the secondary dressing.

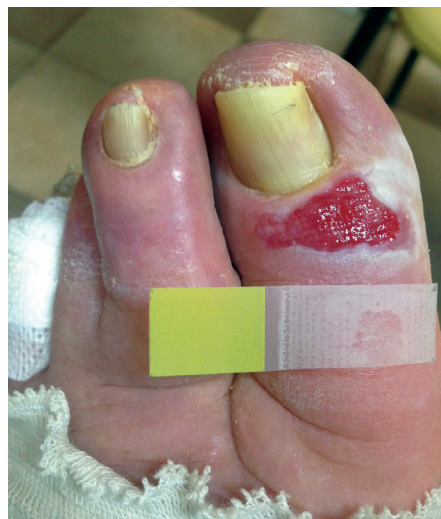*By: Suzanne Kapp, Austin Health Wound Clinic and The University of Melbourne*



Presentation



Review 1



Review 2

- After 17 days, the wound was clean and 100% granulating

## Case 2: Traumatic abrasion injury

### Background

A 74-year-old female with particularly delicate skin, who was involved in a motor vehicle accident, presented with bruising, abrasion injuries and skin tears.

On presentation to the home care clinic, the abrasion on her right forearm measured 30mm x 50mm. The wound was painful and clinical signs of localised infection were present. There were moderate levels of haemopurulent exudate and the wound edge appeared red and inflamed.

### Treatment

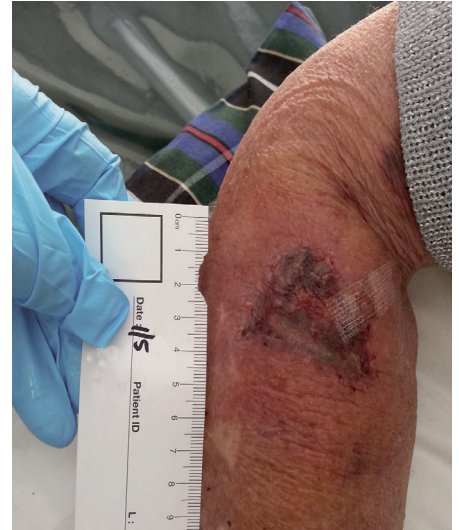To manage the wound bioburden and prevent further trauma, the wound was cleansed with an antimicrobial wound cleansing solution and INADINE was initiated. This was covered with a secondary dressing to manage the exudate. Dressing change was scheduled for 5 days later.

### Outcome

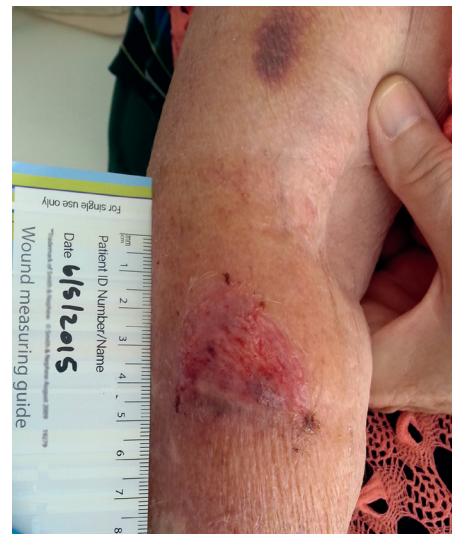At review 5 days later, there was good epithelialisation of the wound, and clinical signs and symptoms of infection had resolved. Exudate levels were low.

The clinician reported a high satisfaction level with the dressing; it was easy to apply and remove, and was pain-free for the patient. As the goals of treatment had been achieved, INADINE was discontinued and treatment was stepped down to a silicone foam dressing to promote final closure and protect the wound.

*By: Leizl Naude, Wound Management Specialist, Eloquent Health & Wellness, Pretoria, South Africa*



Presentation



Review 1

- After 5 days, signs and symptoms of infection had resolved and exudate levels were low

## Case 3: Skin graft donor site

### Background

A 30-year-old gentleman with Langer-Giedion Syndrome (TRPS2) presented to the home care clinic after sustaining a fracture to his radius ulna. The patient had severe compartment syndrome, and two incisions were made to enable tissue release and prevent further damage. When these incisions failed to close completely, the decision was made to use a skin graft.

The patient complained of a painful skin graft donor site that was exuding. The skin graft donor site was located on the right lateral thigh and measured 100mm x 120mm. Clinical signs and symptoms of infection were present, with moderate levels of haemopurulent exudate, bleeding, and friable, dark granulation tissue. The wound was painful (rated 7 out of 10 on a visual analogue scale of 1-10). The surrounding skin appeared healthy.

### Treatment

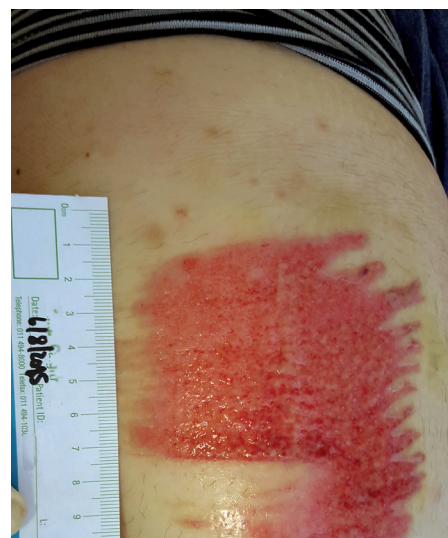The wound was cleansed with an antimicrobial wound cleansing solution and INADINE was applied to manage the bioburden and prevent further trauma. A secondary adherent foam dressing was used to secure the INADINE dressing. Dressing change was scheduled for 1 week later.

### Outcome

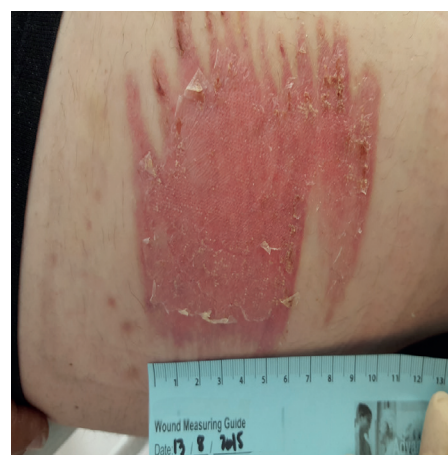
At review 1 week later, the wound was epithelialising and there were no clinical signs and symptoms of infection.

Since the goals of treatment had been reached, INADINE was discontinued and a thin hydrocolloid dressing was used to progress the wound to complete closure. The clinician rated the dressing highly; it was easy to use and did not cause trauma on removal.

*By: Leizl Naude, Wound Management Specialist, Eloquent Health & Wellness, Pretoria, South Africa*



Presentation



Review 1

- After 1 week, there were no signs and symptoms of infection and the wound was epithelialising

## Case 4: Laceration to right knee

### Background

A 53-year-old female with a 7-year history of type 2 diabetes and high cholesterol developed a laceration to her right knee following a work accident in May 2015. The injured area was sutured and she was sent home from the emergency department with a dry gauze dressing.

A few days after the injury, she was seen by her family doctor and received a short course of systemic antibiotics due to wound dehiscence. However, the wound failed to progress and when the patient was seen in the clinic in July 2015, it measured 2.4cm (length) x 1.0cm (width). The wound bed comprised overgranulation tissue, which was friable, and exudate levels were moderate. The surrounding skin was healthy. The patient complained of wound-related pain, scoring 6 out of 10 on a 1-10 visual analogue scale.

### Treatment

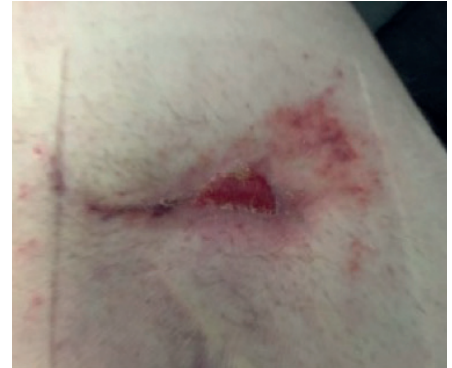Treatment with INADINE was initiated due to the risk of infection and signs of increased bacterial burden (e.g. exudate, increased pain). This was covered with a dressing pad and secured with a polyurethane film dressing. The patient was advised that she would still be able to shower daily due to the film dressing. Dressing changes were scheduled for three times weekly.

### Outcome

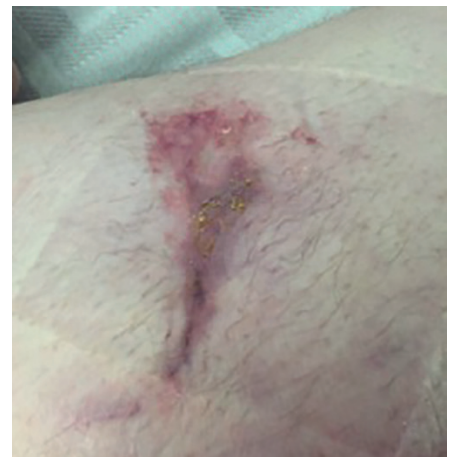The patient was seen in the clinic 1 week later. The wound was healed, the surrounding skin was healthy and she had no pain.

The patient and clinician were both very satisfied with the performance of INADINE, which was discontinued. The patient had found the dressing easy to remove and had been able to follow the planned instructions. No follow-up was required.

By: Kevin Woo, Assistant Professor, Queen's University, Canada



Presentation



Review 1

- After 1 week, the wound had healed and the surrounding skin was healthy



## Case 5: Laceration to left thumb

### Background

A 24-year-old gentleman sustained a laceration to the tip of his left thumb following an accident using a Stanley knife. He has no past medical history.

The laceration measured 2cm (length) x 0.5cm (width). It was cleaned and Steristrips were applied in the emergency department. Three days later he presented to the wound management clinic with an open wound. The patient reported a pain score of 7 out of 10 on a 1-10 visual analogue scale. Exudate levels were low, the surrounding tissue was macerated and granulation tissue in the wound bed was becoming proud.

### Treatment

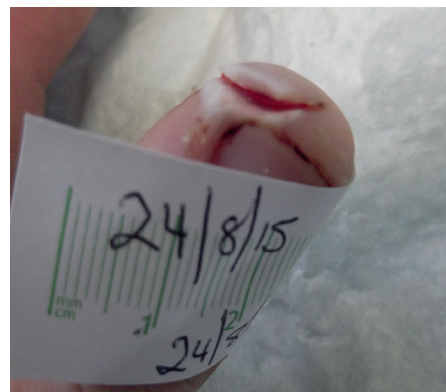INADINE was applied as the wound was considered at risk of infection. This was covered with a simple island dressing. The patient was instructed to clean the wound daily and reapply the dressings.

### Outcome

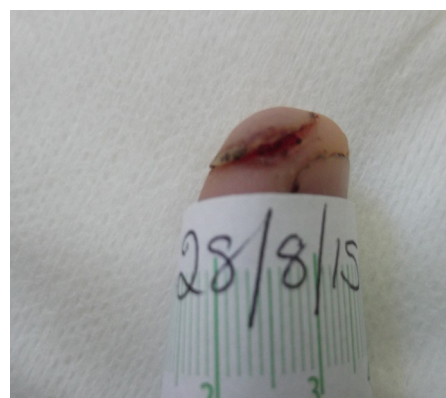Four days later, the patient was reviewed in the clinic. The dressings had been changed three times and had been easy to remove. The wound remained 2cm in length but had almost closed, with the edges of the wound 98% together. The surrounding skin was healthy and there was no exudate. Signs of infection were absent.

INADINE was discontinued with no follow-up required. The patient was advised to apply the island dressing to protect the wound for a further 4–5 days. The patient and clinician were both very satisfied with the performance of INADINE.

*By: Helen Strapp, Tissue Viability Clinical Nurse Specialist, Tallaght Hospital, Dublin, Ireland*



Presentation



Review 1

- After 4 days, the wound edges had almost closed, and the surrounding skin was healthy. There were no signs of infection and exudate was low

## Case 6: Infected ingrown toenail

### Background

A 26-year-old female presented with an infection to the side of her right great toenail, which had failed to improve despite a course of oral antibiotics. She has no past medical history.

The patient underwent wedge resection and debridement of overgranulation tissue in the emergency department using a digital nerve block. At follow-up in the wound management clinic the next day, the wound measured 12mm (length) x 5mm (width) x 4mm (depth). The wound bed comprised 100% granulation tissue, which was slightly friable, and there was slight redness of the surrounding skin. Exudate levels were low. The patient reported a pain score of 4 out of 10 on a 1-10 visual analogue scale.

### Treatment

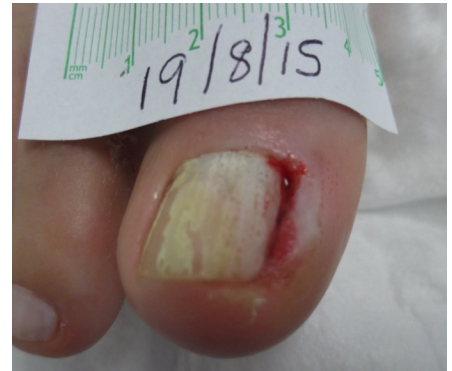INADINE was applied to manage the bioburden. It was covered using a small piece of gauze and secured with a simple island dressing. The patient was instructed to wash the wound daily and reapply the dressings.

### Outcome

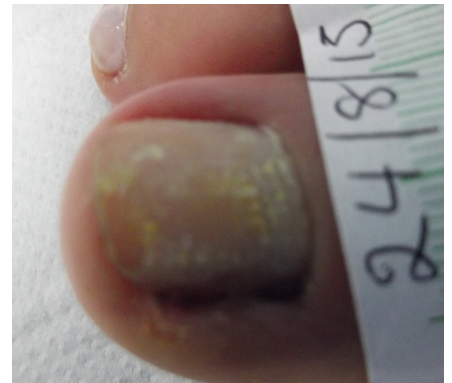Five days later the patient was reviewed in clinic. The dressings had been changed four times since the last visit and these had been easy to remove. The wound was 100% epithelialising and measured 12mm in length, with no depth. The surrounding tissue was healthy and there was no exudate.

INADINE was discontinued and the patient was advised to continue to cover the wound with gauze and the simple island dressing for a further 4 days. Both the patient and clinician were very satisfied with the performance of INADINE. The patient was discharged with no follow-up planned.

*By: Helen Strapp, Tissue Viability Clinical Nurse Specialist, Tallaght Hospital, Dublin, Ireland*



Presentation



Review 1

- After 5 days, the wound was 100% epithelialising, the surrounding skin was healthy and there was no exudate

## Case 7: Laceration injury to left index finger

### Background

A 54-year-old male was admitted to hospital under the care of the orthopaedic team having sustained a deep laceration to his left index finger following a domestic injury. He has no previous medical history and is not on any medications.

The following day, the patient underwent surgery for debridement and repair of his left index finger flexor tendon. When seen by the tissue viability nurse 3 days later, the sutured wound measured 4cm x 2cm and appeared inflamed (slightly red and swollen), with maceration to the surrounding skin. Hypergranulation was also noted on the distal medial aspect of the wound, while exudate levels were low.

### Treatment

INADINE was applied to reduce inflammation and address the risk of infection. The patient was advised to keep the dressing dry, with dressing changes planned for every 2 days.

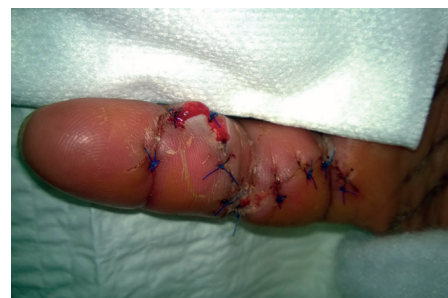The patient was reviewed in the tissue viability clinic 7 days later and, although the wound was improving, it had not reduced in size. The wound bed was cleaner, with reduced maceration to the surrounding skin and less oedema. Exudate levels were minimal. Sutures remained *in situ*.

INADINE was continued as there was still a small amount of oedema and overgranulation. Dressing changes were planned for three times weekly.

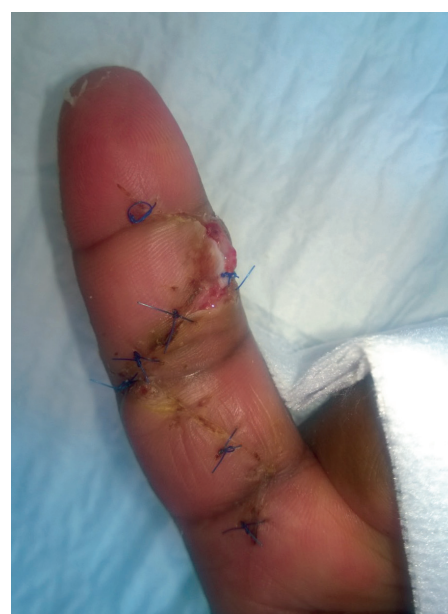### Outcome

At review 1 week later, the wound had reduced in size to 1cm x 0.3cm and was almost completely epithelialised (90%), with some dry flaky skin (10%). INADINE was discontinued as the treatment goals had been met. The patient and clinician were both very satisfied with the performance of the dressing.

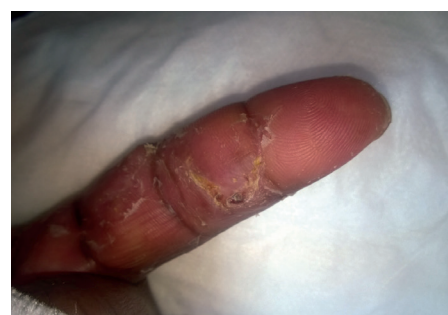By: Emma Cullen Gill, Tissue Viability Manager, Al Ain Hospital, Abu Dhabi, UAE



Presentation



Review 1



Final review

- After 2 weeks, the wound had reduced in size and was 90% epithelialised



A Wounds International publication  
[www.woundsinternational.com](http://www.woundsinternational.com)