

Use of honey to treat a necrotic wound after laryngectomy and neck radiotherapy

Authors:



Sonia Pereira



Pedro Ângelo



Ligia Ferreira

Sonia Pereira is Otolaryngology resident of the CHLC — Hospital de São José, Lisbon, Portugal, and a Navy physician working with hyperbaric oxygen at Centro de Medicina Subaquática e Hiperbárica, Lisbon; Pedro Ângelo is Otolaryngology resident at the CHLN — Hospital Pulido Valente, Lisbon; and Ligia Ferreira is Otolaryngologist at the Portuguese Oncology Institute, Lisbon.

Treatment of laryngeal cancer by laryngectomy requires effective management to diminish wound infection and accelerate healing. This case report outlines the use of a honey-based ointment to manage the supra-tracheostomy necrosis that occurred post-laryngectomy. This resulted in successful healing; honey-based products may accelerate healing as a result of anti-inflammatory and antibacterial action and fibroblast stimulation.

Otolaryngologists from the Portuguese Oncology Institute perform an average of 100 laryngectomies per year in the treatment of laryngeal cancer. Common challenges faced include haematoma formation, wound infection, wound dehiscence and pharyngocutaneous fistula. Persistent non-healing wound dehiscence is relatively frequent despite antibiotic coverage and local wound care, because of the underlying bad condition of the skin and the severe comorbidities of the patients. The skin of the neck is usually in a bad condition because patients requiring a laryngectomy frequently have a poor nutritional status and are immunocompromised (because of the cancer). Additionally, a significant number of them are submitted to local radiotherapy before surgery.

The management of such situations is difficult, expensive and both time- and resource-consuming, often involving repairing surgical flap coverage, which is not always successful. More effective treatments are needed for these patients, which accelerate healing and diminish wound infection in a quicker manner than current local and surgical treatments.

CASE REPORT

A 64-year-old man presented with progressive, long-term dysphonia. He was a heavy smoker and a recovering alcoholic. He also suffered from hypercholesterolemia and chronic obstructive pulmonary disease. At physical examination, a flexible laryngoscopy showed lesions of both vocal cords with extension to the anterior commissure and subglottis. The neck exam was negative for adenopathies.

This patient was diagnosed with a laryngeal tumour (T2N0M0). As he represented a serious surgical risk, he was treated with radiotherapy in November 2010. Failure of the primary treatment led to laryngectomy and bilateral selective neck dissection in June 2011.

Ten days later, extensive supra-tracheostomy necrosis developed. This is common in patients with head and neck cancer because of the aforementioned 'bad condition of the skin'. The risk increases in patients submitted to radiotherapy before surgery, since radiotherapy itself can cause severe lesions to the skin. Mechanical debridement and daily silver dressings (Atrauman®, Hartmann) were performed. One week after this, no significant improvement had occurred.

METHOD

After receiving the patient's consent, the authors introduced a honey-based ointment (L-Mesitran®; Triticum) on 11 July 2011. The surgical wound was cleaned with saline, and L-Mesitran was applied daily in a thin layer, then covered with an absorbent hydrofiber dressing (Aquacel®; Convatec). The surrounding skin was treated with a hypoallergenic, semi-permeable barrier cream (Cavilon®; 3M) to avoid friction and the development of lesions on the healthy skin. The primary dressing was covered and fixed with a self-adherent dressing made of apertured, non-woven polyester fabric coated with a layer of an acrylic adhesive (Mefix®; Mölnlycke Health Care). The patient did not experience any pain during dressing changes. There were no fetid odours and no antibiotics were prescribed.


A hive of Activity



The Advancis Medical honey range has expanded...



NEW!



Scan for more information, call 01623 751 500
or email info@advancis.co.uk

Advancis
Medical
www.advancis.co.uk



“Three days after the application of L-Mesitran® (Triticum), the wound started to improve and closed in approximately 2 months without requiring surgical procedures.”

RESULTS

Three days after the application of L-Mesitran, the wound started to improve and a skin graft was considered. Seven days after, granulation tissue covered more than 80% of the surgical wound. The wound closed on 8 September 2011, in approximately 2 months and without requiring surgical procedures, such as skin graft or flap coverage (see Figures 1–6).

DISCUSSION

Laryngeal cancer is the second most common type of head and neck cancer and makes up 1–2% of all malignancies

worldwide^[1,2]. Approximately 12 500 new cases of laryngeal carcinoma are diagnosed each year in the USA, and the incidence is higher in certain European countries (Spain, France, Italy and Poland)^[2].

Tobacco and alcohol are recognised as the major risk factors for developing malignant tumours of the larynx, but others are gaining importance, such as infection with human papilloma virus (in younger patients, with higher social status)^[3,4]. This is relevant as the authors believe there will be a change in the demographics of patients, who will not be as old, or educationally and economically disadvantaged as current patients.

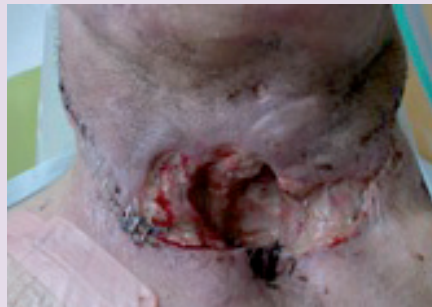

Figure 1. 7 July 2011 — supra-tracheostomy necrosis post-laryngectomy.

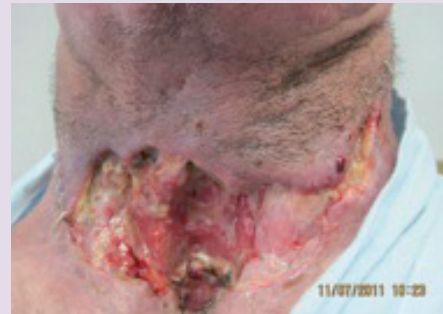

Figure 2. 11 July 2011 — start of honey treatment.

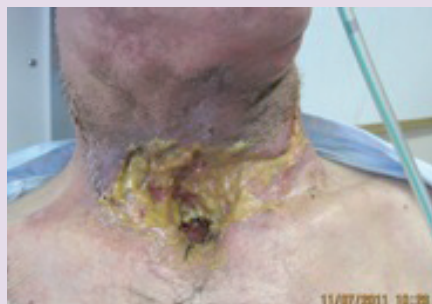

Figure 3. 11 July 2011 — the honey applied.

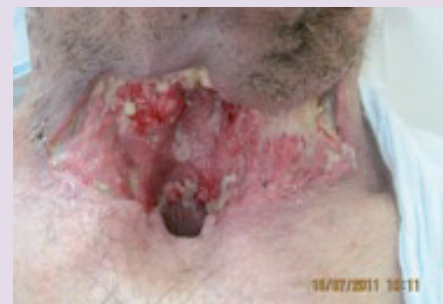

Figure 4. 15 July 2011.

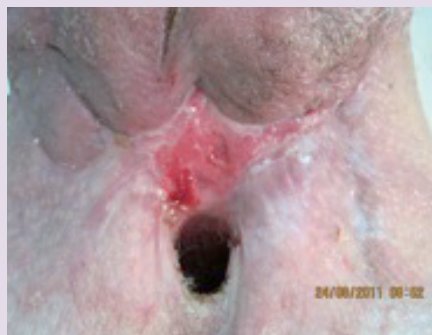

Figure 5. 24 August 2011.

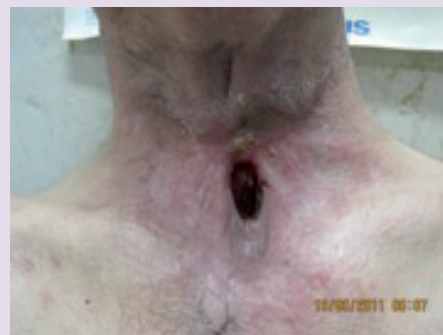

Figure 6. 19 September 2011 — wound fully healed.

The treatment of such a condition relies on the stage of the tumour. Earlier stages (I–II) can be treated with less invasive laser surgery or radiotherapy, whereas more advanced stages (III–IV) are treated with chemo-radiotherapy or aggressive surgery, such as total laryngectomy^[5].

This patient was at stage II on referral, but failed to respond to radiotherapy, which led to a total laryngectomy salvage. Early complications following this procedure are haematoma formation, wound infection, wound dehiscence and pharyngocutaneous fistula^[1,2,5].

Previously irradiated patients have a higher risk of postoperative complications, such as wound dehiscence and/or infection, as a result of poor wound healing and soft tissue fibrosis, frequently worsened by poor nutritional status and other comorbidities. The treatment of such wounds requires local care with daily dressings and, sometimes, surgical closure, along with a longer length of stay in hospital^[1,2,5].

In this case, the patient developed an extensive wound dehiscence, which did not respond to standard local wound care. Silver dressings had been tried and were not considered suitable in this case, because of the need for prolonged use.^[6,7,8] Honey-based products may accelerate healing as a result of their anti-inflammatory^[9] and debriding action^[10], antibacterial activity^[11,12] and fibroblast stimulation effect^[9,13]. In this case, the regeneration of tissue was evident and was completed within 2 months.

CONCLUSION

In this case, honey-based dressings showed significantly better results over other dressings that had been previously used, achieving full healing of an extensive necrotic wound in a few weeks, with no adverse events and without the need for extra surgery and grafting. Honey dressings appear to be a cost-efficient, non-invasive and safe therapy in irradiated, laryngectomised patients who develop postoperative wound dehiscence and/or infection. ■

References

1. Lydiatt WM, Lydiatt DD, Snyder MC (2012) Glottic cancer. Available at: <http://emedicine.medscape.com/article/853055-overview> (accessed 22 November 2013)
2. Hornig JD (2013) Supraglottic cancer. Available at: <http://emedicine.medscape.com/article/852908-overview> (accessed 22 November 2013)
3. Torrente MC, Rodrigo JP, Haigentz M Jr et al (2011) Human papillomavirus infections in laryngeal cancer. *Head Neck* 33(4): 581–6
4. Stephen JK, Chen KM, Shah V et al (2012) Human Papillomavirus outcomes in an access-to-care laryngeal cancer cohort. *Otolaryngol Head Neck Surg* 146(5): 730–8
5. Johnson JT (2012) Malignant tumors of the larynx. Available at: <http://emedicine.medscape.com/article/848592-overview> (accessed 22 November 2013)
6. Jull AB, Rodgers A, Walker N (2008) Honey as a topical treatment for wounds. *Cochrane Database Syst Rev* Oct 8(4):CD005083. Available at: <http://www.ncbi.nlm.nih.gov/pubmed/18843679> (accessed 22 November 2013)
7. Thomas GW, Rael LT, Bar-Oh R et al (2009) Mechanisms of delayed wound healing by commonly used antiseptics. *J Trauma* 66(1): 82–90, discussion 90–1
8. Bradshaw CE (2011) An *in-vitro* comparison of the antimicrobial activity of honey, iodine and silver wound dressings. *Bioscience Horizons* 4(1): 61–70
9. Molan PC (2006) The evidence supporting the use of honey as a wound dressing. *Int J Low Extrem Wounds* 5(1): 40–54
10. Subrahmanyam M (1991) Topical application of honey in treatment of burns. *Br J Surg* 78(7): 497–8
11. Cooper R, Molan PC, Hardling KG (1999) Antibacterial activity of honey against strains of *Staphylococcus aureus* from infected wounds. *J R Soc Med* 92(6): 283–5
12. Cooper R, Molan P (1999) The use of honey as an antiseptic in managing *Pseudomonas* infection. *J Wound Care* 8(4): 161–4
13. DuToit DF, Page B (2009) An *in-vitro* evaluation of the cell toxicity of honey and silver dressings. *J Wound Care* 18(9): 383–9

This case study was conducted with the patient's consent. It was part of a preliminary study carried out to evaluate the effectiveness of honey as a topical therapy in the treatment of complicated wounds. The purpose was to gather clinical data about this product's benefits and risks, in order to ascertain the utility of its incorporation in standard hospital treatment protocol. The authors declare no conflicting interests.