

TECHNOLOGY UPDATE:

Using telehealth and photography for wound assessment in Western Australia



Author:
Beth Sperring

This article examines the use of telehealth in rural Western Australia. The author provides case studies to explain how clinicians use photography, secured communication and videoconferencing to advise on treatment plans and monitor care pathways. Thus telehealth supports staff working in remote sites and enables expert wound care to be provided to patients no matter how rural their location.

Telehealth has been described as “the use of telecommunication technologies to provide healthcare services across distances”^[1]. One-quarter of the population of Western Australia live in remote and rural sites and, according to Moffatt and Eley^[2], rural Australians have benefited from telehealth because it has increased access to health services and improved the skills of healthcare professionals, which in turn has decreased disparities in rural and urban health.

The Plastic Surgery Telehealth Service was established at the Royal Perth Hospital (RPH) to provide equitable and timely expert review for all Western Australians. Delivery of this interdisciplinary telehealth service relies on two basic forms:

- Videoconferencing.
- Store and forward.

Videoconferencing lets clinicians discuss and observe in real time with remote patients and staff. Despite the benefits offered by this immediacy and interactivity, videoconference images frequently lack the crisp, clear perspective required for effective wound assessment, necessitating the use of store and forward.

Store and forward refers to technologies and processes that allow clinical data, X-rays and digital images be captured, stored locally and transmitted securely to another site, where the information is reviewed. Store and forward is asynchronous — images are

frequently taken and sent during separate time frames from related videoconferences — allowing flexibility in timing for capturing and transmitting images.

IMAGE QUALITY

When associated with comprehensive patient histories, good-quality wound and trauma images can validate and enhance wound assessment^[3]. Images that provide “an objective view of the wound” can be used to track wound healing^[4], and images that incorporate environmental factors, such as seating or mobility devices, can help clinicians detect the factors that may inhibit healing.

Swann^[5] discusses the importance of achieving sharp, clear images and standardising images to achieve uniform size or quality, allowing for comparison of the wound over time. Photographic skills of nurses and patients vary, affecting the quality of the images produced, but the requisite skills can be acquired and improved through practice^[4].

High-resolution wound images may even show more detailed views of wounds^[6], which can improve assessment and lead to more effective management. In a teledermatology study in which image colour and sharpness were nearly always rated “good to excellent”, Krupinski et al^[7] reported 83% concordance between in-person and digital diagnoses and 76% concordance between biopsy results and digital diagnoses.

Beth Sperring is Acting Clinical Nurse Consultant, Plastic Surgery Telehealth Service, Royal Perth Hospital, Perth, Western Australia, Australia.

Sikka et al^[8] studied images taken on mobile phones and although image quality was described as moderate (and not all images were of usable quality), still found a high rate of agreement in management. These findings suggest images of lesser quality may still prove to be useful.

EDUCATION AND TRAINING

Although the literature agrees about the advantages of using digital images^[9,10], there is much discussion around the need for appropriate training for all clinicians^[11], the skill level of clinicians required to reduce variability^[12] and the obstacles preventing the use of telemedicine, such as lack of evidence and the need to create a shift in culture^[13].

In Western Australia, clinicians are trained in the taking, transmitting and storing of digital images. Guidelines for standardising images are available to all staff on the intranet and Internet. Quality control involves the review of images received at the tertiary centre, providing feedback to the nurse photographer and reporting to management when image quality is poor. In instances of poor image quality, resource availability is investigated and further education is provided to up-skill the nurse photographer as required.

Guidelines for standardising images have been published by the Western Australian Department of Health (WoundsWest)^[14]. These cover:

- The optimum distance of the camera from the wound.
- The correct camera settings to achieve optimum image quality.
- The required perspectives (similar to the lateral and oblique perspectives used to take X-rays).
- The use of lighting and/or flash.
- The importance of reducing background clutter.
- The best size and format to enable image storing and forwarding.

CLINICAL APPLICATIONS

Digital photography is a relatively cost-effective way of documenting the progression of a wound, can be easily incorporated into nursing practice^[15] and can aid in diagnosis^[16]. As such, digital photography is an important tool in determining treatment options. The following case studies illustrate the use of videoconferencing and store and forward to

manage plastic surgery trauma patients at a distance. Informed consent was obtained from both patients.

Case study 1

Mr A is a 58-year-old man who lives 1500 km north of Perth. He was referred for specialist review after a metal sheet fell on his shin, causing a laceration. The injury resulted in a traumatic, distally based necrotic skin flap. Initial surgical debridement was undertaken at the regional site but, because of complications with the skin flap's viability, he was transferred to Perth for secondary debridement and returned home a few days later.

Figure 1 was taken by the regional nurse 1 week post-surgery, before the videoconference. The image shows a swollen, dusky skin flap with debris present within the wound bed. The videoconference took place with a nurse at both sites. The author, [at the RPH site] used the photographs and wound description provided by the rural nurse to confirm the debris were dressing-product residue. Options for removing the debris included conservative fine sharp wound debridement (CFSWD) or autolytic debridement. The regional nurse stated that she was neither confident nor skilled in CFSWD, so options for achieving autolytic debridement were discussed and a hydrocolloid dressing decided on. The author also stressed the importance of good wound cleansing and skin hygiene.

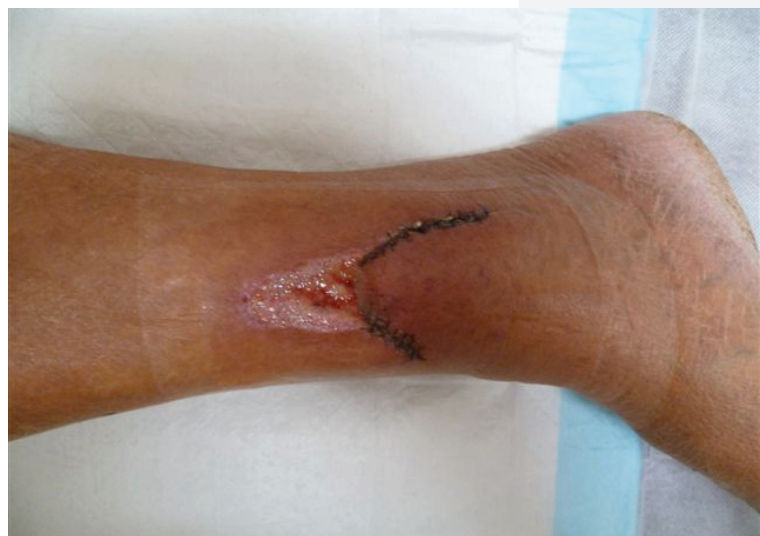

Figure 1. Wound presented at a videoconference. It was established that the debris around the skin flap was dressing-product residue, and a treatment plan was given via the videoconference to the regional nurses and rural patient.

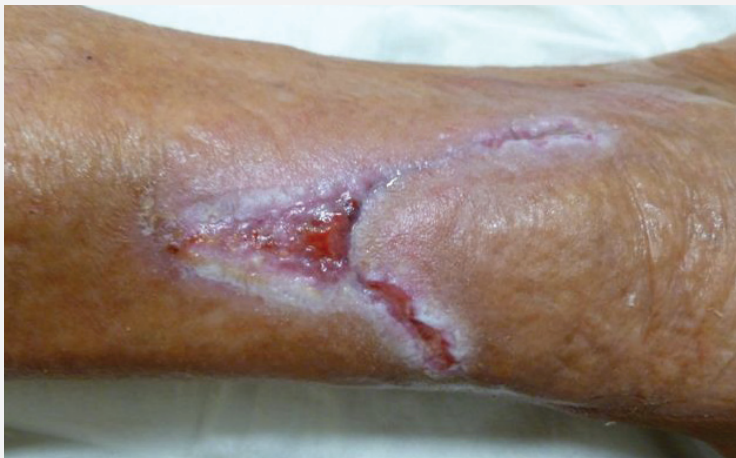

Figure 2. Wound 2 weeks after surgery showing healing progression; the rural nurse confirmed that the maceration seen here went on to resolve.

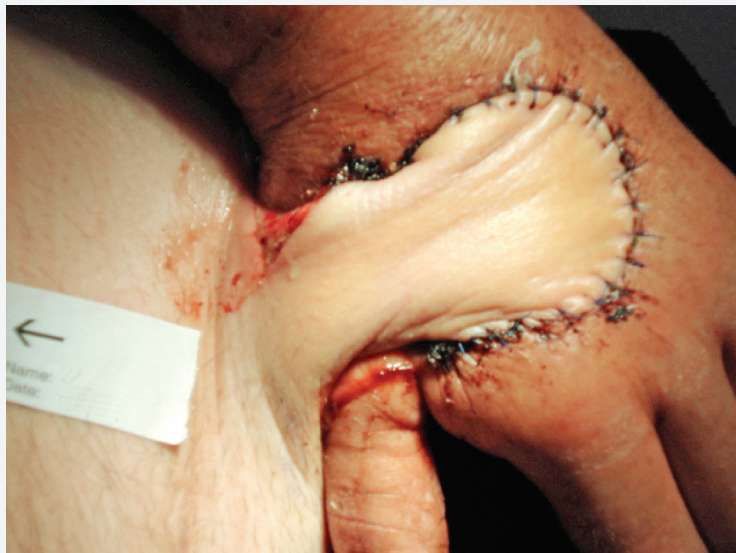


Figure 3. After sustaining a crush injury this patient was transferred to hospital for surgical repair with a groin flap covering the deficit skin of his left hand.

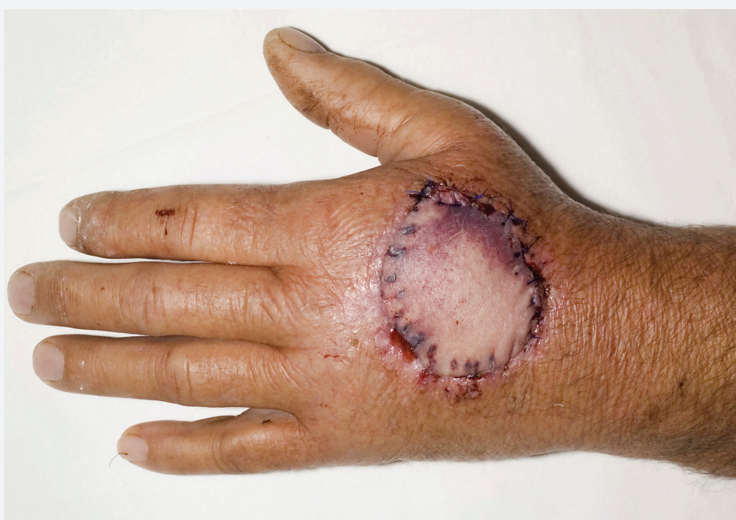

Figure 4. Videoconferencing and digital photography were used to monitor wound healing after flap division to allow the patient to be discharged to his rural home.

The wound image also showed swelling in the foot and ankle. The interactive nature of videoconferencing allowed the nurses and Mr A to discuss treatment options to reduce the swelling that would be compatible with Mr A's lifestyle. Consideration was given to:

- Local temperatures — these can reach 35°C, plus humidity, which affects wound care choices as hydrogel dressings dry out and emollients melt.
- Mr A's ability to self-care — his ability to effectively undertake dressing changes himself were crucial, as he lives outside the catchment area for domiciliary care services and too far from the regional hospital to attend for regular dressing changes.
- Product availability — the range of dressing products was reduced.
- Mr A's home and work environment — dust, dirt and air-conditioning had to be accounted for.

Figure 2, taken 2 weeks post-surgery, shows the progress towards healing. The wound bed had healthy granulation tissue and the wound margins were epithelialising. In discussion with the rural nurse, it was confirmed that the maceration seen in the image had resolved. After suture removal, the suture line was flat, pink and soft, suggestive of a good scar outcome.

Case study 2

Mr B is a 62-year-old man who sustained a crush injury to his left hand while working at home, 400 km northeast of Perth. The Royal Flying Doctor Service transferred him to RPH, where surgical repair included a groin flap to cover the skin deficit to the dorsum of the left hand (Figure 3).

Postoperative review was undertaken via videoconference and the use of photography; photos of the groin flap were taken weekly and shared with the tertiary site using a secure network. The images were used to assess the colour and positioning of the flap. Further assessment, including the warmth and texture of the flap, was made in discussion with the regional nurse and patient.

Clinical problem-solving, discussion of the wound care options and the planning of readmission for flap division were all undertaken during videoconference sessions. After division of the groin flap (Figure 5), the patient's rehabilitation, including wound review, scar management and range of movement, were supervised using videoconferencing and digital photographs.

CONSENT AND SECURITY

Managing wound images and patient information involves issues of consent, confidentiality, privacy and security. Addressing these issues involves all health services and professionals. Secured messaging systems must be used to ensure compliance with policies, regulations and acts that govern practice^[17]. At RPH, digital images are catalogued using a unique identification system that complies with the Freedom of Information Act, the Western Australian Health Data Management Policy and the Federal Privacy Act. Images are accessible and easily retrieved by those who have the right to access them. Written permission for the use of images is gained from each patient if being used to support clinical review across health services or being shared with a GP. Patients and staff recognise that this process of collaboration is important in improving outcomes.

Although there is increased awareness of the medico-legal issues associated with the sharing of information across organisations and between service providers, new and advancing technologies pose a grey area. Many such technologies allow increased access and the ability to share, without the appropriate level of security, potentially leading to information or images reaching unsecured sites. Bypassing the constraints of a secure system may improve information-sharing and timeliness of decision-making, but clinicians should proceed with caution, as issues of technical and clinical standards to ensure patient privacy and standardised practice are as yet unresolved^[18].

DISCUSSION

Videoconferencing that incorporates digital still images in the store and forward format has improved the effectiveness and timeliness of patient review by the RPH Plastic Surgery Telehealth Service. A combination of digital images, videoconferencing and phone communication allows for quick and effective reassessment when complications arise.

Secure electronic networking across health services assists in care delivery. With patient consent, a digital image and a discharge summary can be shared with the extended team, including the GP or community-based service provider. Photographic images are used to comparatively assess wounds and plan treatment options. This encourages improved communication, strengthening service provision.

Other benefits include reduced travel and transport costs, as neither the specialist team nor the patient needs to travel long distances for

wound reviews. Minimising patient travel also leads to reduced time away from home, family and community, which could increase quality of life.

Each videoconference session provides an opportunity for continuing education, while members of the specialist team gain an understanding of varied work environments throughout the state. Support and encouragement in the use of videoconferencing and photographic equipment from the Western Australian Department of Health has built confidence within the workforce, and nurses from rural sites report that access to expert advice has encouraged them to become more involved in wound care.

CONCLUSION

Wound assessments using videoconferencing and digital clinical images will be successful if the images are sharp, well-composed and exhibit the appropriate colour contrast. The images must be reviewed in association with a comprehensive medical and wound history and sent in a timely manner to a clinician who has the technology and skill to interpret the images. Wound treatment plans generated by this collaborative approach need to reflect the skill of the clinicians providing the care and the resources available while remaining focused on the patient and their wound.

Telehealth can provide benefits for clinicians and patients. It is an excellent example of how technology can be used to build stronger partnerships in wound care, support staff working in remote and rural sites and provide expert care to patients regardless of their location. ■

Acknowledgements

The author acknowledges: the Western Australian Country Health Service; the Medical Illustrations Department at Royal Perth Hospital; Alan Hamilton, Manager of the State Telehealth Service; and the patients who have agreed to share their stories.

References

1. Mosby (2009) *Mosby's Medical Dictionary*. 8th edn. Elsevier, Amsterdam
2. Moffatt JS, Eley DS (2010) The reported benefits of telehealth for rural Australia. *Austral Health Rev* 43(3): 276–81
3. Bradshaw LM, Gergar ME, Ginger A (2011) Collaboration in wound photography. *J Adv Skin Wound Care* 24(2): 85–92
4. Buckley KM, Adelson LK, Agazio JG (2009) Reducing the risks of wound consultation. *J Wound Ostomy Continence Nurs* 36(2): 163–70
5. Swann G (2010) Photography in wound care. *Nurs Times*

96(45): 9

6. Debray M, Couturier P, Greuillet F et al (2001) A preliminary study of the feasibility of wound telecare for the elderly. *J Telemed Telecare* 7: 353–8
7. Krupinski E, LeSueur B, Ellsworth L et al (1999) Diagnostic accuracy and image quality using a digital camera for teledermatology. *Telemed J* 5(3): 257–63
8. Sikka N, Pirri M, Carlin KN, Strauss R, Rahmimi F, Pines J (2012) The use of mobile phone cameras in guiding treatment decisions for laceration care. *Telemed e-Health* 18(7): 554–7
9. Samad A, Hayes S, French L, Dodds S (2002) Digital imaging versus conventional contact tracing for the objective measurement of venous leg ulcers. *J Wound Care* 11(4): 137–40
10. Santamaria N, Carville K, Ellis I, Prentice J (2004) The effectiveness of digital imaging and remote expert wound consultation on healing rates in chronic lower leg ulcers in the Kimberley region of Western Australia. *Primary Intention* 12(2): 62–70
11. Murphy RX, Bain MA, Wasser TE, Wilson E, Okunski W (2006) The reliability of digital imaging in the remote assessment of wounds defining a standard. *Ann Plast Surg* 56(4): 431–6
12. Houghton PE, Kincaid CB, Campbell KE, Woodbury MG, Keast DH (2000) Photographic assessment of the appearance of chronic pressure and leg ulcers. *Ostomy Wound Manage* 46(4): 20–30
13. Saffle JR, Edelman L, Theurer L, Morris SE, Cochran A (2009) Telemedicine evaluation of acute burns is accurate and cost-effective. *J Trauma* 67(2): 358–65
14. Prentice J, Baker R (2013) *Digital Photography in Wound Management*. Department of Health WoundsWest, Perth, Western Australia
15. Phillips K (2006) Incorporating digital photography into your wound-care practice. *Wound Care Can* 4(2): 16–18
16. Hayes S (2003) Digital photography in wound care. *Nursing Times* 99(42): 48–52
17. Ruotsalainen P (2010) Privacy and security in teleradiology. *Eur J Radiol* 73(1): 31–5
18. Silverman RD (2003) Current legal and ethical concerns in telemedicine and e-medicine. *J Telemed Telecare* 9(51): 67–9