

Hyperbaric oxygen therapy as adjunctive treatment for diabetic foot ulcers

Authors:

Luinio Tongson,

Danielle L. Habawel,

Rachelle Evangelista,

John Lerry Tan

The gold standard for diabetic foot ulcer treatment includes debridement of devitalised wound tissue, management of any infection, revascularisation procedures when indicated and offloading of the ulcer.

Hyperbaric oxygen therapy (HBOT) has been promoted as an effective adjunctive treatment for diabetic foot wounds^[1]. The effects of HBOT on improving wound tissue hypoxia make it a useful adjunct in clinical practice for diabetic foot ulcers. It may reduce the risk of lower-extremity amputation and improve healing in people with diabetes with foot ulcers^[1].

Diabetic foot ulcers are one of the most significant and devastating complications of diabetes. The prevalence of foot ulceration in the diabetic population is 4–10%^[2]. It is estimated that about 5% of all people with diabetes present with a history of foot ulceration, and the lifetime risk of these people developing this complication is 15%^[2,3,4]. In the study by Moxey et al, 70% of all non-traumatic amputations of the lower limbs occurred in patients with diabetes^[5].

The aim of the authors' study was to evaluate the effects of systemic HBOT on the healing course of diabetic foot wounds and the amputation rate relating to foot ulcers in people with diabetes.

METHODS

Between March 2012 and July 2013, 54 diabetic foot patients with either Wagner grade 3 or 4 wounds who underwent HBOT at the Dr James G. Dy Wound Healing and Diabetic Foot Centre, Chinese General Hospital and Medical Centre, Manila, Philippines, were included in the study. The protocol for the diabetic foot wounds was HBOT at 2.5 absolute atmospheres, administered once a day, 5 days a week, with each session lasting 90 minutes. Alongside HBOT, standard care included debridement, modern moist dressings and negative pressure therapy if indicated, as well as metabolic and nutritional management.

The study end point was ulcer healing and determining the amputation rate of those patients who underwent HBOT. A Wagner grade 3 ulcer was considered healed when it was completely epithelialised and remained so until the next visit in the study. Wagner grade 4 ulcers were considered healed when the gangrene had separated and the ulcer below was completely epithelialised. An improved grade 3 wound was defined in this study as the presence of granulation tissue

after 4 weeks of HBOT. For grade 4 ulcers, improvement was considered to be the separation of gangrene from the ulcer below with the presence of granulation tissue. If extirpation was above the ankle, it was categorised as major amputation.

RESULTS

The recommended minimum number of HBOT session for people with diabetes and foot ulceration is 30^[6]; the minimum number of hyperbaric treatments included in this study was five sessions, and the maximum number of treatments was 30 (giving an average of 13 treatments). Thirteen patients were excluded from the study because they received less than five sessions of HBOT. Of the remaining 41 individuals, 24 were male and 17 female, with an age range of 39–97 years (average age, 65 years).

A total of 88% (36/41) of the participants showed an improvement in their condition, while 12% underwent major amputation. Of those 36 patients whose condition improved with HBOT, 86% (31/36) had complete healing of their diabetic foot ulcer and 14% had partial healing, where there was granulation tissue in the wound bed but the wound had not fully epithelialised by study end. *Figures 1–2* show two examples of diabetic foot ulcer healing after receiving HBOT.

Table 1 shows outcomes in relation to the number of HBOT sessions. Of those patients who had 5–10 sessions of HBOT, 85% (12/14) with a Wagner grade 3 ulcer and 80% (8/10) with a Wagner grade 4 ulcer showed wound improvement and did not require a major amputation; thus, the amputation rate was 15% (2/14) in those with a Wagner grade 3 ulcer and 20% (2/10) in those with a Wagner grade 4 ulcer.

In those patients who received 10–20 sessions of HBOT, there was an improvement in 85% (6/7) and 100% (4/4) in patients with Wagner grade 3 and 4 ulcers, respectively. There was a 15% (1/7) amputation rate among those with a Wagner grade 3 ulcer. After 21–30 sessions of HBOT there was a 100% improvement of both Wagner grade 3 (1/1) and 4 (5/5) ulcers.

DISCUSSION

The amputation rate for people with diabetes and foot ulcers is 15–70 times higher than of the general population^[7]. Ischaemia, infection and retarded wound healing are the most common causes of amputation. Wound healing is oxygen dependent and is limited by its availability at the cellular level. Elevated tension of oxygen in plasma causes upregulation of growth factors, down-regulation of inflammatory cytokines, increased fibroblast activation, angiogenesis, antibacterial effects and enhanced antibiotic action^[7,8,9].

Treatment with HBOT involves the intermittent administration of 100% oxygen at a pressure greater than that at sea level. It is performed in a chamber with the patient breathing 100% oxygen while the atmospheric pressure is increased to 2–3 absolute atmospheres. This results in an increase in the concentration of oxygen in

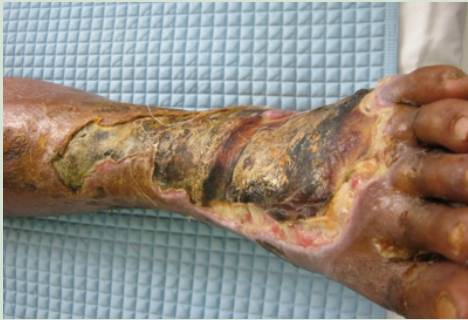

Figure 1a. Diabetic foot ulcer (Wagner grade 3), which had been a non-healing wound for 2.5 months. There was a black, hard covering on the wound site with foul, purulent discharge oozing from the wound.

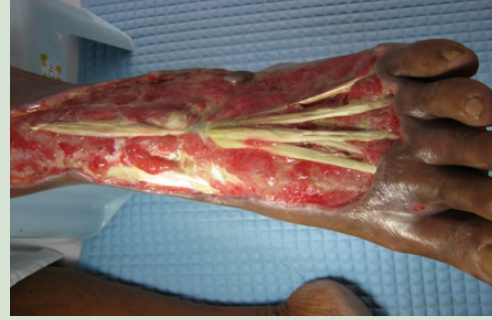

Figure 1b. Surgical debridement was performed and the dressing changed daily; a broad-spectrum antibiotic was given, and granulation was noted after five sessions of hyperbaric oxygen therapy (HBOT).

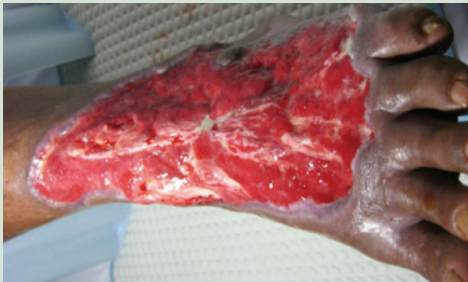

Figure 1c. Two weeks after 10 sessions of HBOT, with autolytic debridement and daily dressing changes, granulation and epithelialisation were observed.

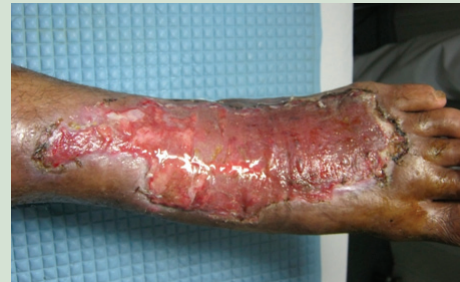

Figure 1d. Improved wound post-skin graft after 2.5 months of treatment and adjunctive therapy.

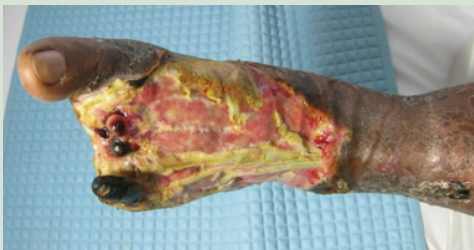

Figure 2a. A diabetic foot ulcer (Wagner grade 4), which had not healed for 3 months; necrosis and slough were noted.

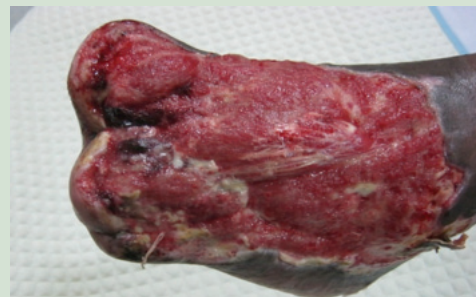

Figure 2b. Transmetatarsal amputation was performed, and granulation was observed after five sessions of HBOT.

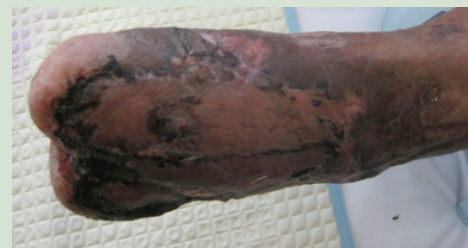

Figure 2c. Three weeks after skin graft and 10 sessions of HBOT.

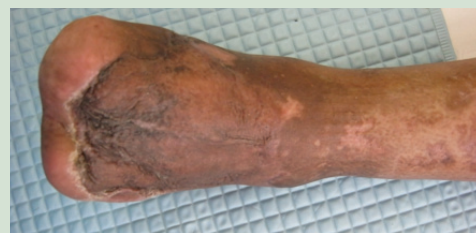

Figure 2d. The wound was completely healed after 3 months.

Table 1. Number of hyperbaric oxygen therapy sessions and their effect on the healing of diabetic foot ulcers

Number of sessions of hyperbaric oxygen therapy	Wagner grade 3 diabetic foot ulcer		Wagner grade 4 diabetic foot ulcer	
	Improved	Amputated	Improved	Amputated
5–10	12 (85%)	2 (15%)	8 (80%)	2 (20%)
10–20	6 (85%)	1 (15%)	4 (100%)	0
21–30	1 (100%)	0	5 (100%)	0

the blood and an increase in the diffusion capacity to the tissues. The partial pressure of oxygen in the tissues is increased, which stimulates neovascularisation and fibroblast replication and increases phagocytosis and leukocyte-mediated killing of pathogens in the wound. There is strong evidence that fibroblasts, endothelial cells and keratinocytes replicate at higher rates in an oxygen-rich environment^[10]. Based on these data, the concept is that the administration of oxygen at high concentrations and pressures might accelerate wound healing in diabetes.

The Undersea and Hyperbaric Medical Society's indications for the use of hyperbaric oxygen in wound care includes the treatment of *Clostridial myositis* and *myonecrosis* (gas gangrene), crush injury, compartment syndrome and other acute traumatic ischaemias, arterial insufficiencies, enhancement of healing in selected problem wounds, soft tissue infections, refractory osteomyelitis, delayed radiation injury, compromised grafts, and flap and acute thermal burn injury^[11]. Additional indications recommended by the 2004 European Consensus Conference on Hyperbaric Medicine^[12] are surgery and implant in irradiated tissue, post-vascular procedure reperfusion syndrome and limb replantation. In the USA, the new Medicare- and Medicaid-approved indication is diabetic wounds of the lower extremity with the following criteria: patients with type 1 or type 2 diabetes with a lower extremity wound as a result of diabetes; wounds that are Wagner grade 3 or higher; and patients that have failed a 30-day course of standard, conventional wound therapy^[13]. Meanwhile, the Wound Healing Society has given HBOT a level I evidence rating in their *Guidelines For The Best Care Of Chronic Wounds*^[14].

In the study by Faglia et al^[15], HBOT was associated with a reduction in amputation rates among patients who were at risk of below-knee or above-knee amputation because of severe ischaemia, underlying osteomyelitis, or both. In the analysis of Heyneman and Lawless-Liday^[16] on the different clinical trials assessing the usefulness of HBOT for the treatment of diabetic foot ulcers, amputation was prevented in 82–95% of patients. HBOT resulted in a mean limb salvage rate of 89%, compared with prevention of

amputation in 61% of patients who received conventional therapy alone.

Chen et al^[17] found that HBOT significantly improves healing of diabetic foot ulcers in a dose-dependent manner. They compared the efficacy of <10 HBOT sessions with >10 HBOT sessions for the treatment of diabetic foot ulcers. The investigators found that in the group that had <10 HBOT sessions, limbs were preserved from amputation in 33.3% of the group; in those patients who had >10 HBOT sessions (mean, 22.8 sessions), 78.3% had their feet preserved from amputation. In the present study, the likelihood of wound healing and limb preservation increased with the number of HBOT sessions received.

HBOT is recommended in Wagner 3 or higher diabetic foot wounds and is initiated at the authors' institution when 1 month of standard therapy fails to achieve results. The authors found no data on the effect on healing and amputation in patients with earlier treatment of HBOT. HBOT may be unnecessary for the great majority of patients who respond to appropriate standard wound care; however, for those patients at risk of amputation, their wound needs to be healed promptly with available adjunct therapies, such as HBOT.

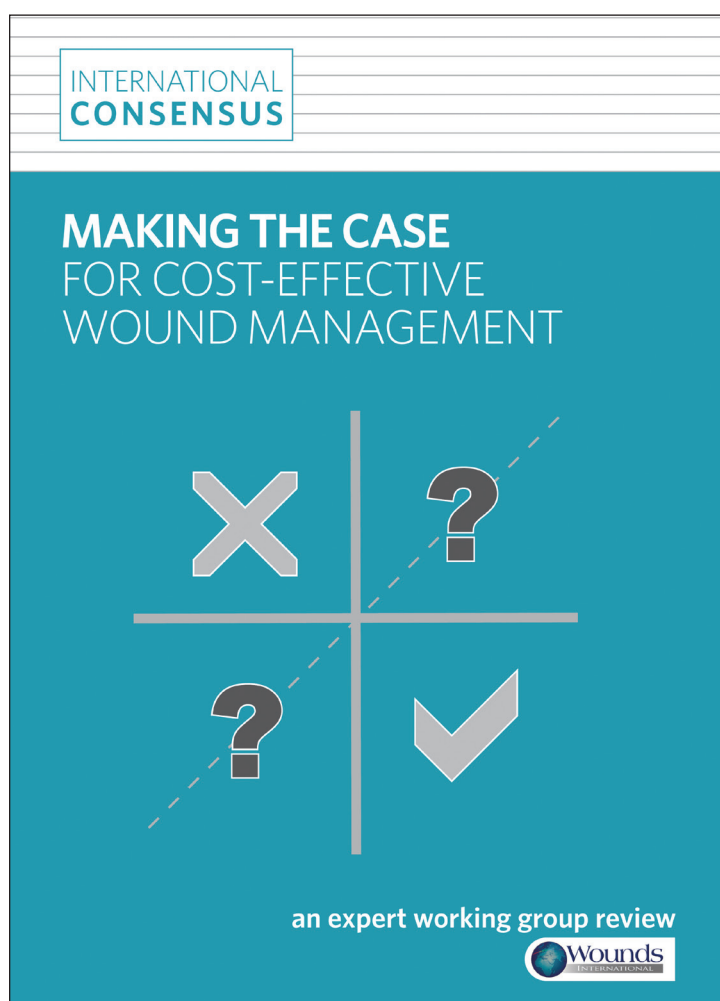
CONCLUSION

Treatment of diabetic foot wounds with an aggressive, multidisciplinary therapeutic protocol in conjunction with HBOT is effective in decreasing major amputations. It seems that HBOT improves healing of diabetic foot ulcers in a dose-dependent manner. The preliminary results are promising, but large randomised controlled trials are necessary to establish the efficacy of HBOT in the treatment of diabetic foot ulcers. ■

AUTHORS' DETAILS

Luinio Tongson is Head, Dr James G. Dy Wound Healing and Diabetic Foot Centre, General Surgeon and Wound Care Specialist, Danielle L. Habawel, Rachele Evangelista and John Lerry Tan are HBOT and Wound Care Nurses, Dr James G. Dy Wound Healing and Diabetic Foot Centre, Chinese General Hospital and Medical Centre, Manila, Philippines.

Do you need to demonstrate that a wound care intervention offers value for money?



A new international consensus can help

- ✓ Understand what is meant by 'cost-effective wound management'
- ✓ Appreciate the different types of economic analysis used in healthcare
- ✓ Interpret information on cost and cost-effectiveness of wound care modalities and protocols
- ✓ Set up systems to collect the data for analysis
- ✓ Make an appropriate case for cost-effective wound management

Free to download from
www.woundsinternational.com

Soon to be available in French, German, Italian and Spanish

References

1. Lipsky BA, Berendt AR (2010) Hyperbaric oxygen therapy for diabetic wounds: has hope hurdled hype? *Diabetes Care* 33(5): 1143–5
2. Abbott CA, Carrington AL, Ashe H, North-West Diabetes Foot Care Study et al (2002) The North-West Diabetes Foot Care Study: incidence of, and risk factors for, new diabetic foot ulceration in a community-based patient cohort. *Diabet Med* 19: 377–84
3. Centers for Disease Control and Prevention (2005) Lower extremity disease among persons aged ≥40 years with and without diabetes: United States, 1999–2002. *MMWR Morb Mortal Wkly Rep* 54: 1158–60
4. Lauterbach S, Kostev K, Kohlmann T (2010) Prevalence of diabetic foot syndrome and its risk factors in the UK. *J Wound Care* 19: 333–7
5. Moxey PW, Gogalniceanu P, Hinchliffe RJ et al (2011) Lower extremity amputations—a review of global variability in incidence. *Diabet Med* 28: 1144–53
6. Latham E (2013) Hyperbaric oxygen therapy: enhancement of healing in selected problem wounds. Medscape. Available at: <http://bit.ly/1f3TBdt> (accessed 10.12.13)
7. Roeckl-Wiedmann I, Bennett M, Kranke P (2005) Systematic review of hyperbaric oxygen in the management of chronic wounds. *Br J Surg* 92: 24–32
8. Chen SJ, Yu CT, Cheng YL, Yu SY, Lo HC (2007) Effects of hyperbaric oxygen therapy on circulating interleukin-8, nitric oxide and insulin-like growth factors in patients with type 2 diabetes mellitus. *Clin Biochem* 40: 30–6
9. Steed DL, Attinger C, Colaizzi T et al (2006) Guidelines for the treatment of diabetic ulcers. *Wound Repair Regen* 14(6): 680–92
10. Katsilambros N, Dounis E, Makrilakis K, Tentolouris N, Tsapogas P (2010) *Atlas of the Diabetic Foot*. 2nd edn. Wiley-Blackwell: 220. Available at: <http://bit.ly/1jlqz6A> (accessed 10.12.13)
11. Gesell L (2008) *Hyperbaric Oxygen Therapy Indications*. 12th edn. The Hypberbaric Oxygen Therapy Committee report. Undersea and Hyperbaric Medical Society, Durham, NC
12. European Committee for Hyperbaric Medicine (2004) 7th European Consensus Conference on Hyperbaric Medicine. ECHM, Lille. Available at: <http://bit.ly/1CQ7E8> (accessed 10.12.13)
13. CMS.gov (2003) Medicare national coverage determination for hyperbaric oxygen therapy (20.29). Available at: <http://go.cms.gov/1jlu5Oq> (accessed 10.12.13)
14. Robson MC, Barbul A on behalf of the Wound Healing Society (2006) Guidelines for the best care of chronic wounds. *Wound Regen Repair* 14(6): 647–8
15. Faglia E, Favales F, Aldeghi A et al (1996) Adjunctive systemic hyperbaric oxygen therapy in treatment of severe prevalently ischemic diabetic foot ulcer. *Diabetes Care* 19(12): 1338–43
16. Heyneman CA, Lawless-Liday C (2002) Using hyperbaric oxygen to treat diabetic foot ulcers: safety and effectiveness. *Crit Care Nurse* 22(6): 52–60
17. Chen C-E, Ko Y-H, Fong C-Y, Juhn R-J (2010) Treatment of diabetic foot infection with hyperbaric oxygen therapy. *Foot Ankle Surg* 16: 91–5

Advances in wound dressing technology



Author: Professor Geoff Sussman

Over the past 50 years or so, the emphasis in wound care research has been on developing a range of wound dressings with properties of absorption, hydration and more recently antibacterial activity^[1]. The new developments have lead to a shift from simple dressings to more advanced

devices and products that incorporate pharmaceutically active ingredients.

There is a need to improve the condition of wound bed tissue and provide products that repair and regenerate damaged tissue and optimise healing. This can be achieved either by the addition of essential healing components or by removing or neutralising elements that retard healing or lead to ongoing tissue damage.

An urgent requirement is to develop effective point-of-care diagnostic tests to identify and define the underlying cause of wound breakdown. A point-of-care test that can detect elevated protease levels is now available^[2,3], but much could be done if we had a better understanding of the presence of inflammatory cytokines, wound pH, autoimmune antibodies and other markers of infection.

There are cost implications with these newer treatments and diagnostic tests, and it is important to not only look at the unit cost of a product but also to explore the cost-effectiveness of the intervention in relation to associated and long-term costs, as well as cost savings^[4,5]. If newer methods of treatment prevent or reduce the length of hospital stay and speed healing, then in the long term it is possible to make an economic case for using them.

KERATIN-BASED WOUND MANAGEMENT

An interesting example of a new wound treatment is the development of keratin-based wound care products. The ability of keratinocytes to migrate is critical for wound re-epithelialisation^[6,7]. Keratins are the major proteins in keratinocytes and are essential for many cellular functions (e.g. cell migration), and upregulation of keratin expression has been observed in response to wounding^[8,9].

Keratin-based products have been approved for use in several regions of the world, including Australia, New Zealand and the USA. A robust keratin matrix (Keramatrix[®]; Keraplast Technologies LLC), designed for use on wounds with moderate exudate levels or for use as an interface with negative pressure wound therapy, has shown positive results^[6,8]. As the wound heals, the keratin matrix