

Use of a two-layer compression system in severe bilateral leg lymphoedema with ulceration: A case report

Malou van Zanten, Beth Kean

Key words

Chronic ulcer, compression, lymphoedema, wound healing

Malou van Zanten, Research Officer and PhD candidate, Lymphoedema Research Unit, Department of Surgery, School of Medicine, Flinders University, South Australia, Australia. Beth Kean, Lymphoedema Research Unit Coordinator, Lymphoedema Research Unit, Department of Surgery, School of Medicine, Flinders University, South Australia, Australia

Declaration of interest: None.

Research into the benefits of compression on venous congestion and associated ulceration has been widely documented (Milic et al, 2010; Stucker et al, 2013). However, research into the correct level of compression for lymphoedema is difficult to obtain, most likely due to a lack of inclusion of rigorous undergarment pressure measurements in reports. The preferred method of lymphoedema treatment is usually compression of the limb, due to its ability to enhance venous return, reduce capillary filtration, and increase lymphatic reabsorption and the breakdown of fibrotic tissue (Moffatt et al, 2011; Muldoon and Charles, 2013).

It is vital that, during the intensive treatment phase for lymphoedema, the compression garment does not hinder an individual's range of movement to ensure maximum lymph flow from the affected area. It has been documented that muscle contraction while wearing compression produces a higher peak in blood and lymph flow velocity (Partsch and Moffatt, 2012).

Abstract

Background: In this case report the authors present an individual with a medical history of severe bilateral leg lymphoedema, multiple bilateral ulceration, type 2 diabetes, and morbid obesity. **Aim:** To determine the efficacy of a commercially available compression system (Coban™ 2 Compression System; 3M) on an individual with severe bilateral leg lymphoedema, and multiple bilateral ulceration. **Methods:** Employing the Coban 2 Compression System toe-boot bandaging technique, objective and subjective data on leg volume, tissue compositional changes and wound healing were collected at baseline and three times per week over a 4-week follow-up period. Under-bandage pressures were controlled using a pressure monitor during bandage application. **Results:** The patient's total limb volume decreased during treatment; circumference volume measurements showed a 3 L reduction in the left leg, and a 1.3 L reduction in the right leg. Limb volume decreased by 2.1 L in the left leg, and 2.1 L in the right. Bioimpedance spectroscopy data measured a reduction of 3.2 L in the left leg and 3.0 L in the right leg. Tissue fluids reduced by 55% in the superficial tissue of both calves during the intervention period. The reduction of the total wound size was 21.7 cm² in the left leg and 19.95 cm² in the right leg. **Conclusion:** Treatment with Coban 2 Compression System improved wound healing and decreased leg volume in the present case.

The Coban™ 2 Compression System (3M) is a two-layer, latex-free, self-adherent compression bandage. Its rigidity and inelastic properties ensure a high working pressure and low resting pressure. The Coban 2 Compression System has been shown to be useful in lymphoedema reduction and venous ulcer healing in multicentre, randomised, controlled trial settings (3M, 2011; Moffatt et al, 2011; Morgan et al, 2011). These studies account for the user-friendliness of the application for the clinician, as well as monitoring slippage, patient comfort, and mobility.

The burden of chronic wounds

Chronic nonhealing wounds frequently occur in the latter stages of lymphoedema. They are especially problematic in the lower legs due to their dependency. Chronic wounds can be costly and are a major public health problem in addition to significantly reducing the quality of life of the affected person (Agale, 2013). A high incidence of venous ulcers and recurrence has been reported within the

Australian community (Barker and Weller, 2010). Chronic leg ulcers are believed to affect more than 3% of the population aged ≥65 years, with a 56% chance of reoccurrence within 3 months of healing (Barker, 2010).

Case study

A 61-year-old Caucasian male (Patient X) presented at the Lymphoedema Research Unit at Flinders University in April 2013 with severe bilateral lymphoedema, that had persisted since 2009. He had received several intensive reduction treatments since that time; however, due to high treatment costs, he ceased them in early 2011.

The patient reported that in March 2008 he had multiple fibromas removed from the groin. The fibromas penetrated deeper than initially anticipated. Within 2 days of surgery, the postoperative deep tissue wounds had become infected, and the participant was admitted for multiple daily dressing changes. Three days later, the wounds showed signs of continued breakdown and an increase in necrotic tissue. Patient X was immediately admitted to

emergency surgery to prevent the spread of gangrene. The extent of soft tissue trauma, major infection, and possibly lymphatic vessel disruption is likely to have evoked the onset of lymphoedema in 2009.

In October 2012, a lymphoscintigram showed functional lymphatic insufficiency, but no indication of dermal backflow. Lymph drainage from both legs was within normal limits. Deep vein thrombosis was discounted and a chest X-ray did not show overt cardiac failure.

With a history of morbid obesity, hypertension, and type 2 diabetes, the skin on the patient's lower legs showed signs of dryness, fissures, and weeping ulcers. He also suffered recurrent episodes of erysipelas, further compounding the lymphoedema. A lower-back injury prevented him from wearing a compression garment. To manage his condition and to respond to frequent flare ups, he visited the emergency department on a weekly basis for dressing changes and antibiotics, if needed. Wound dressings alone did not facilitate wound healing, with limb volumes and his wounds continuing to worsen, so it was decided that an intensive compression therapy programme would be initiated, with the main aims being to reduce lymphoedema and associated wound discomfort.

Clinical presentation lymphoedema

Patient X presented with extremely dry and scaly skin, and pitting on the lower legs and dorsal surfaces of both feet. The upper legs and knees seemed unaffected and bilateral positive Stemmer's sign was present. Skin changes, hyper pigmentation on both lower limbs, papillomatosis on the base of the toes, and fibrotic tissue in the mid area of the tibia (bilateral) were also present. The limbs were categorised as stage III lymphoedema, as per International Society of Lymphology consensus (2009). There were no signs of neuropathy, despite the individual having diabetes.

Patient X is retired and resides with his

sibling. He explained he is very fond of computer games and can spend hours sitting on a computer chair without laying supine for a night's rest.

Both legs had multiple wounds with excess yellowish-clear exudate. Granulation tissue was visible, but all wounds were covered with debris and showed signs of infection (*Figure 1*).

Materials

Patient X's lower legs were bandaged using a toe-boot application with the Coban 2 Compression System. This intervention was applied every second day for a duration of 4 weeks due to leakage of the wound areas.

The following bilateral duplicated measurements were obtained at every clinic visit:

- Wound size and perimeter using a Visitrak wound measurement grid (Smith & Nephew).
- Limb circumferences using a Perometer 350S (Pero-System Messgeräte) every 3.7mm and a standard tape measure every 4 cm.
- Total body water (intracellular and extracellular), limb fluid volumes, fat and muscle masses using a whole-body Bioimpedance Spectroscopy Unit (InBody)
- Site-specific tissue fluid (MoistureMeter D; Delfin Technologies).
- Undergarment pressure in supine position (Kikuhime; mediGroup) on the lateral side of lower limb, large probe.
- Transepidermal water loss (TEWL; VapoMeter).
- Tissue resistance using an indurometer (Flinders Biomedical Engineering).
- A quality of life questionnaire was also completed and photos taken (Keeley et al, 2010).

Methods

Patient X's lower legs, including the feet and toes, were cleansed with lukewarm water and a surgical sponge (Medisponge, Filtrona Porous Technologies) and dried prior to all

measurements being taken. The limb was then bandaged with Coban 2 Compression System, using the toe-boot application method (3M, 2011). Bandage slippage was monitored with a simple mark on the skin with a marker pen and measured with measuring tape upon return appointments. While applying bandages in the supine position, 42mmHg–45mmHg was required to reach the desired 50mmHg of under-bandage pressure when standing.

Site-specific tissue fluid was measured at anterior mid-thigh (15cm proximal from patella), posterior mid-thigh (15cm proximal from knee crease), and posterior lower limb (15cm distal from knee crease). A bilateral dorsal site measurement was also taken (medium probe, 2.5mm–5mm in skin), 5cm from the base of the toes using the MoistureMeter D.

Results

Treatment with the Coban2 Compression System over 4 weeks significantly decreased Patient X's total limb volume. During the active bandaging time (between baseline and final visit) limb volume as measured by the Perometer was reduced by 2.1L in the left leg and 2.1L in the right leg. The right leg increased in volume from week four to follow up by 0.4L and the left leg increased by 0.1L, which was expected as active intervention had ceased.

Lower extremity total volumes were calculated from the circumference measurements using the truncated cone formula; a limb volume reduction of 3.1L in the left leg and 1.7L in the right leg was observed. During the active bandaging period (4 weeks), the Bioimpedance Spectroscopy (InBody) measurement showed a reduction of 3.2L in the left leg and 3.0L in the right leg. At the follow-up appointment, further fluid reduction was measured, despite no active intervention (Patient X was wearing bilateral compression garments).

Multiple wounds were present bilaterally, on the distal posteriors of the lower limbs. At baseline, the left leg had a total wound size of 25.8 cm² and right leg was 29.7 cm². Patient X's wound size reduced by 21.7 cm² in the left leg and 17.7 cm² in the right leg between baseline and final visit. It was observed at follow up (4 weeks post treatment) that no wounds were present on the left leg, while the right leg wounds had continued to decrease in size by 2.25 cm², giving a total reduction of 19.95 cm² (*Figure 2*).

The TEWL readings fluctuated during the taking of measurements. This could be due to

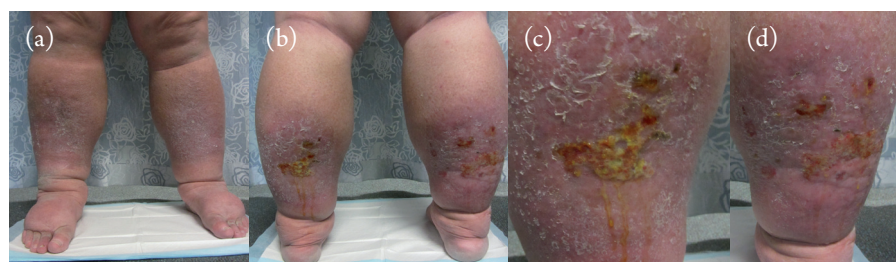
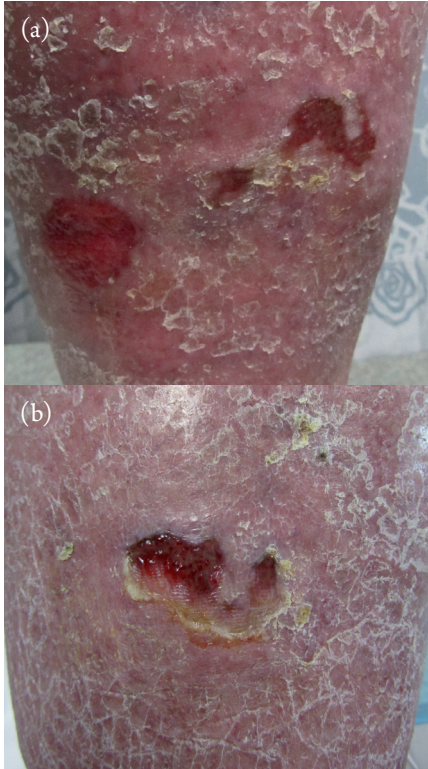


Figure 1. Patient X's legs at baseline in (a) anterior and (b) posterior views, and detailed images of the patient's (c) left and (d) right leg wounds.

Case report

Figure 2. Patient X's (a) left and (b) right posterior leg wounds following 4 weeks' treatment with the Coban™ 2 Compression System (3M).



the bandaging material being removed and cleansing of the legs before the measurements were taken. The authors waited for the skin to cool and dry, however, the lower limbs were often damp with perspiration. Higher TEWL readings in the right leg suggested a loss of barrier function. This was consistent with the authors' prediction, as the wounds on the right leg were larger and harder to heal than those present on the left leg.

A 55% reduction in fluids in the superficial tissue of both calves (mean 34.4 units of calf area) was measured

by MositureMeter D between baseline and final appointment. At the follow-up appointment it was noted that all fluid levels had increased again, which is to be expected given that the compression garment did not provide as high a pressure as the bandage did. A correlation was discovered between the thigh area measurement fluid increase and the indurometer data measured at baseline and follow up.

The indurometer showed a higher reading within the thigh areas, possibly indicating that fluid has been pushed up from the calf areas due to the compression bandaging and has made the upper-leg tissue softer. There were no significant indurometer findings at the other measurement sites (Figure 3).

Quality of life

There was no change in Patient X's quality of life score over the case study period, with the participant rating 8 on a scale of 10 (0 = no quality of life, 10 = highest quality of life; Keeley et al, 2010). However, at week four, he reported less difficulty in areas such as walking, bending, and undertaking housework, in comparison to baseline. Patient X also reported that the swelling did not affect how he felt about himself "at all" by week four, compared to "a little" at baseline.

Overall, the Patient X reported an increase in ease of living from baseline to week four. However, at follow up, his answers were similar to baseline. At follow up, Patient X marked the same subjective scale numbers as baseline, however, he commented that his quality of life had improved. Patient X had "enjoyed coming for appointments" and discussing lifestyle and daily events with the researchers. The increase in quality of life throughout the treatment phase could

be attributed to both the bandaging and the regular friendly contact of the authors. Patient X was compliant in wearing bandages throughout the 4-week treatment regimen. Although he reported some heat-induced discomfort at night, he found the bandages comfortable and noninvasive.

Conclusion

The compression bandaging used in this case report proved effective in reducing Patient X's lymphoedema fluids, subsequently resolving his wounds. The removal of this fluid is essential for wound healing. Early detection is crucial to prevent further progression in lymphoedema, including skin breakdown and the appearance of chronic wounds. Cost is often a factor for both patient and clinician in treatment options and bandaging may prove a more cost-effective intervention that may halt wound progression. Bandaging must be applied correctly, with the right pressure and pressure gradient, and adapted to each patient's needs, including mobility, comfort, and cost.

References

- 3M (2011) *Training Manual Lymphoedema Intensive Therapy*. 3M Health Care, Australia
- Agale SV (2013) *Chronic Leg Ulcers: Epidemiology, Aetiopathogenesis, and Management*. Available at: <http://bit.ly/1b4akc5> (accessed on 27.11.2013)
- Barker J, Weller C (2010) Developing clinical practice guidelines for the prevention and management of venous leg ulcers. *Wound Pract Res* 18(2): 62–71
- Keeley V, Crooks S, Locke J et al (2010) A quality of life measure for limb lymphoedema (LYMQOL). *Journal of Lymphoedema* 5(1): 26–37
- Lymphoedema Framework (2006) *Compression Therapy: A Position Document on Compression Bandaging. International Consensus*. MEP Ltd, London: 12–23
- Milic DJ, Zivic SS, Bogdanovic et al (2010) The influence on different sub-bandage pressure values on venous ulcer healing when treated with compression therapy. *J Vasc Surg* 51(3): 655–61
- Moffatt CJ, Franks PJ, Hardy D et al (2011) A preliminary randomized controlled study to determine the application frequency of a new lymphoedema bandaging system. *British Journal of Dermatology* 166(3): 624–32
- Morgan PA, Murray S, Moffatt CJ, Young H (2011) The experience of patients with lymphoedema undergoing a period of compression bandaging in the UK and Canada using the 3M Coban 2 compression system. *Int Wound J* 8(6): 586–98
- Muldoon J, Charles H (2013) Clinical effectiveness and patient considerations in oedema management. *Journal of Lymphoedema* 8(1): 51–2
- Stücker M, Link K, Reich-Schupke S et al (2013) Compression and venous ulcers. *Phlebology* 28 (Suppl 1): 68–72

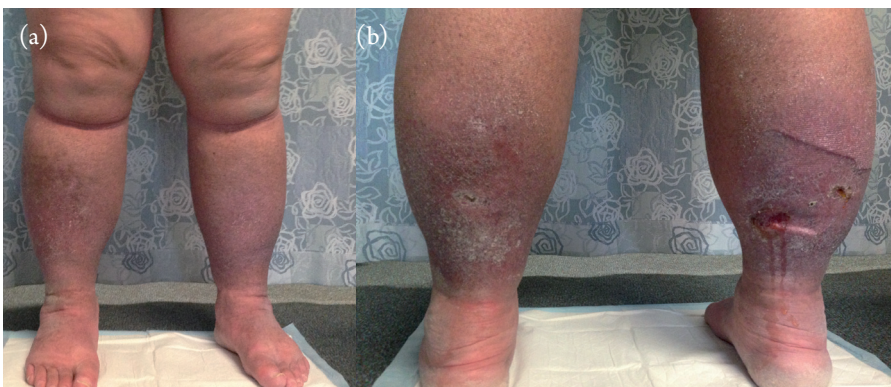


Figure 3. Patient X's legs at follow-up, (a) anterior and (b) posterior views.