

PALLIATIVE BANDAGING IN BREAST CANCER-RELATED ARM OEDEMA

Sue Crooks, Jane Locke, Julie Walker, Vaughan Keeley

Palliative bandaging is used in patients with arm oedema for whom conventional intensive treatment is not possible nor appropriate, e.g. because of their general condition or local disease. A variety of palliative bandaging techniques to suit different circumstances is described. Contraindications and cautions are discussed. Palliative bandaging should be carried out by healthcare professionals who have the appropriate training and skills and it is particularly important to be clear about the aims of management and ensure that the burdens of treatment do not outweigh the benefits.

Key words

Lymphoedema
Lymphorrhoea
Palliative bandaging
Arm oedema

This article aims to describe a practical approach to palliative bandaging in breast cancer-related arm oedema. As with many aspects of the treatment of chronic oedema, there is little evidence base for this technique and there is even variation in the use of the term 'palliative bandaging'. In this article, the authors plan to clarify what is meant by palliative bandaging and describe the methods used in their lymphoedema service in Derby.

Definition of palliative bandaging and aims of treatment

The term palliative is commonly used to describe a management approach that is intended to relieve symptoms,

when treatment aimed at curing the underlying condition is not possible. It is typically used in the context of patients with advanced cancer, where it describes the holistic care of progressive disease where the goals are to relieve symptoms and improve the patient's quality of life (National Institute for Health and Clinical Excellence [NICE], 2004).

However, in the management of chronic oedema the term 'palliative' could also be used to describe a modified approach to management in patients who are unable to tolerate a full course of intensive treatment, as the focus of treatment is also on relieving symptoms and improving quality of life rather than aiming to resolve the swelling completely. It may therefore apply to patients with chronic leg oedema who have significant comorbidity, e.g. chronic obstructive pulmonary disease. Indeed, it could even be argued that all physical treatments for chronic oedema are palliative in nature, as they do not cure the underlying condition.

Nevertheless, for most clinicians managing chronic oedema, palliative bandaging is an approach used in patients with advanced cancer where the aim is to relieve symptoms rather than to fully control the oedema. It commonly describes a bandaging method which is modified from the

standard full pressure (>45 mmHg) multi-layer lymphoedema bandage (MLLB). However, in the authors' experience, a variety of different methods of palliative bandaging are required to address specific problems in individual patients, so even in this group of patients the term itself covers a range of techniques.

For example, in patients with locally advanced breast cancer where there is recurrent disease in the axilla and tumour in the lymphatics of the skin of the chest wall and upper arm, the arm can become grossly swollen (Keeley, 2007). In this situation the skin is often very fragile with associated lymphorrhoea. An elastic compression garment is likely to cause damage to the skin and increase the patient's discomfort and therefore is not usually advisable. However, a light supportive bandage with minimal, if any, compression may be used.

For other patients, a palliative bandage using modified MLLB but with reduced pressure (15–25 mmHg) is appropriate (Lymphoedema Framework, 2006). These are likely to be patients who, because of comorbidities, cannot tolerate standard MLLB (>45 mmHg) but can tolerate more than a supportive bandage. In this situation, the aims of treatment may be different from those in the previous example (Table 1).

Sue Crooks is Clinical Specialist Lymphoedema and Physiotherapist; Jane Locke is Lymphoedema Sister and Therapist; Julie Walker is Clinical Nurse Specialist and Vaughan Keeley is Consultant in Palliative Medicine, Derby Hospitals NHS Foundation Trust, Nightingale Macmillan Unit, Derby

Table 1

Aims of palliative treatment with reduced pressure multi-layer lymphoedema bandaging (15–25mmHg)

- To reduce severe limb or digit swelling
- To relieve discomfort from a heavy, severely swollen limb by reducing limb volume
- To stop lymphorrhoea
- To reduce and control swelling in a paralysed, swollen limb with altered sensation as a result of a brachial plexopathy

Table 2

Contraindications and cautions in applying compression

- Arterial insufficiency
- Acute infection/cellulitis
- To stop lymphorrhoea
- Acute deep vein thrombosis
- Uncontrolled heart failure

For some patients, palliative bandaging may need to be a long-term treatment, whereas for others it may be temporary, e.g. until the skin condition has improved and lymphorrhoea has ceased. Then an alternative approach, for example, a light compression sleeve or shaped Tubigrip® (Mölnlycke Health Care) may be appropriate.

Finally, palliative bandaging may not necessarily be appropriate for all patients with metastatic cancer. In those who are relatively well and have a long prognosis, a more intensive approach to their arm oedema is indicated to reduce the swelling as much as possible, including full compression MLLB. It is important, therefore, to assess each patient individually and consider which type of palliative bandaging to use. As in all aspects of palliative care, the burden of treatment should not outweigh the

benefits. The focus is on the relief of symptoms and an improvement in the patient's quality of life.

Contraindications and cautions when applying palliative bandaging

The usual contraindications and cautions when applying compression need to be considered (Lymphoedema Framework, 2006) (Table 2). However, in palliative bandaging for arm oedema, these may need to be viewed differently. The benefits of symptom relief and improved quality of life may outweigh the potential risks and again need to be assessed for each individual patient. With caution, the use of reduced compression may, therefore, still be appropriate, e.g. to manage lymphorrhoea in a patient with a heavy, swollen, numb, paralysed arm and locally recurrent breast cancer. The effects should be reviewed on each change of bandage and modifications made accordingly.

Other symptomatic treatments

In situations where palliative bandaging is being planned, other treatment should also be considered. Comprehensive details of these are beyond the scope of this article, but examples are given in Table 3. Further information can be found in Keeley (2007).

Corticosteroids, e.g. dexamethasone, may be helpful in managing a number of symptoms when there is active local cancer such as axillary lymphadenopathy or skin nodules on the chest wall. Steroids are believed to reduce peritumour oedema and, thereby, relieve extrinsic compression of structures such as lymphatics, veins and nerves. They can, therefore, help reduce arm swelling and improve pain, including that of neuropathic origin. Neuropathic pain is commonly described by patients as 'burning' or 'shooting' in nature and, anatomically, its distribution follows a recognised neural pathway. It is usually associated with altered sensation or numbness of the skin and results from compression or damage to nerves.

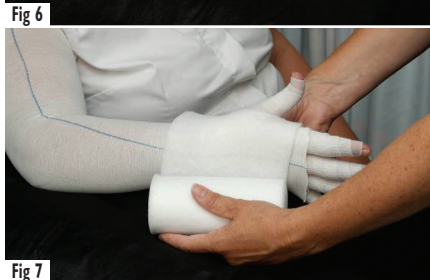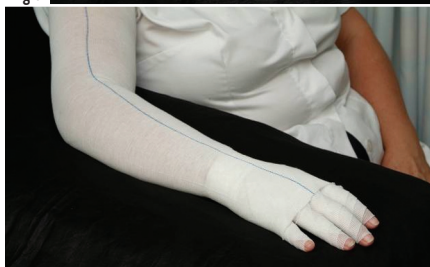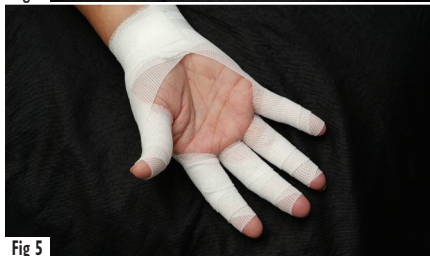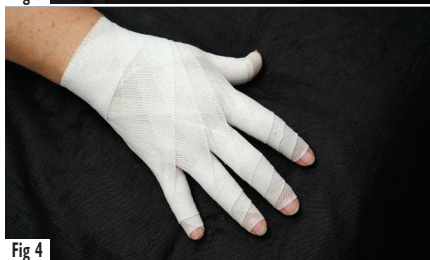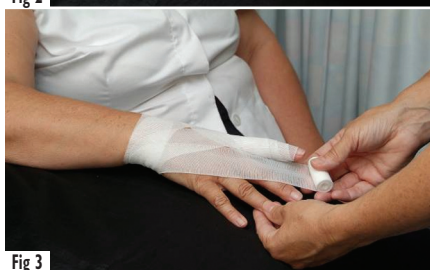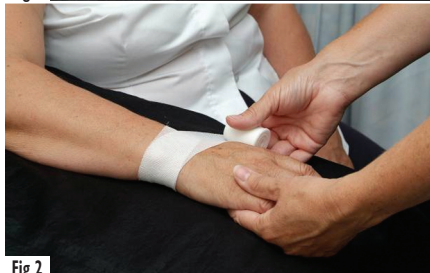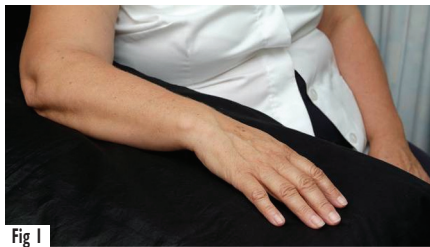Table 3

Other palliative care approaches to symptom management in patients with arm oedema

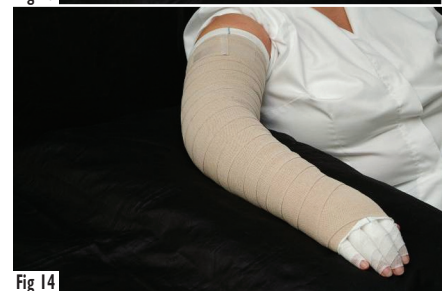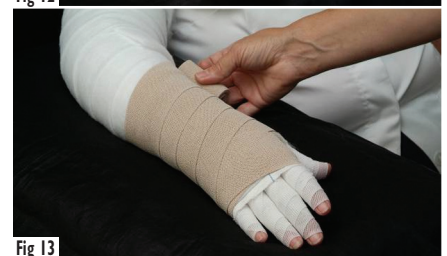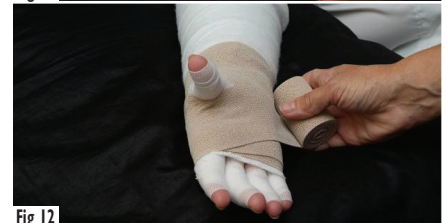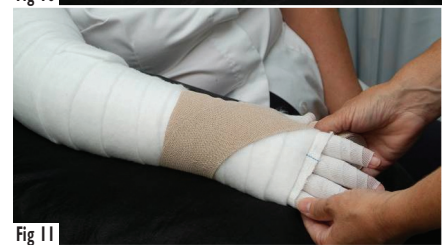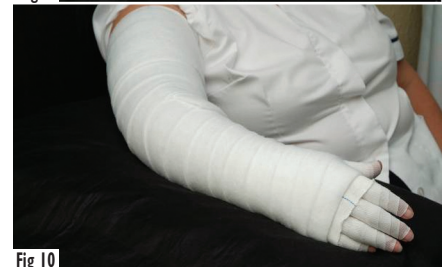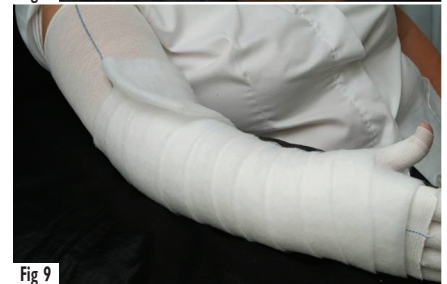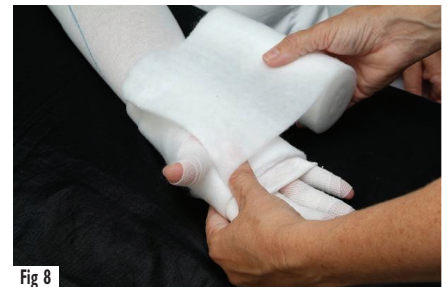| Symptom | Management |
|--------------------|--|
| Pain from swelling | Analgesics, using WHO analgesic ladder |
| Neuropathic pain | Amitriptyline, gabapentin, etc |
| Heaviness/swelling | Trial of corticosteroids, e.g. dexamethasone |
| Cellulitis | Antibiotics |
| Truncal swelling | Manual lymphatic drainage (MLD) Simple lymphatic drainage (SLD) |

How to apply a reduced pressure, palliative, multi-layer lymphoedema bandage

Before bandaging, nurses should cleanse the patient's skin using pH neutral soap, natural soap or a soap substitute. The skin should be thoroughly dried. The nurse should then apply an emollient (avoiding perfumed products) and dress any broken skin with a non-adherent dressing (Lymphoedema Framework, 2006). The following steps should then be taken:



- ▶▶ Position the patient comfortably, sitting or lying, with their arm supported on a pillow at their side (Figure 1)
- ▶▶ Bandage the fingers from the base of the nail, using a 4cm digit bandage. Anchor the bandage at the wrist (Figure 2), then ask the patient to splay their fingers. Come across the dorsum of the hand to the tip of the thumb (distal). Apply the bandage spirally with even overlap, firmly but without compression, to the root of the thumb (proximal). Take the bandage back across the dorsum of the hand, under the wrist and repeat to each finger (Figure 3), finishing at the wrist (Figure 4). Tape lightly in place
- ▶▶ Ask the patient to move his/her fingers and check for comfort (Figure 5)
- ▶▶ Apply a layer of cotton tubular bandage with a hole cut out for the thumb (Figure 6) (dressings can be secured under this.) Use a length slightly longer than the limb
- ▶▶ Apply a layer of soft synthetic wool padding, such as Profore® #1 (Smith & Nephew Healthcare) or Cellona® (Vernon Carus) of a size to suit the limb. The nature of the product allows it to conform to the limb shape. Make a hole for the thumb (Figure 7), then apply from the hand spiralling up the length of the limb with a 50% overlap from distal to proximal. Use extra layers in the cubital fossa, thumb web and palm of the hand, to protect vulnerable pressure points (Figures 8, 9). Aim to achieve an even conical shape (Figure 10)
- ▶▶ Turn over the cotton tubular bandage at the hand for neatness
- ▶▶ Ask the patient to splay their fingers again
- ▶▶ Using a 4cm or 6cm (depending on the patient's hand-size) short-stretch (inelastic) bandage, anchor the bandage loosely at the wrist (Figure 11). Then bandage the hand with two turns at the base of the fingers, with even tension. 'Figure of eight' the bandage to cover the palm and base of thumb (Figure 12). Check the whole of the hand has been covered



- ▶ Resting the patient's arm/hand on the pillow, spiral the bandage over the wrist and forearm (Figure 13). Use consistent overlap (50%)
- ▶ Using an appropriate size bandage (8–10cm), continue up the arm. Bandage the elbow in slight flexion
- ▶ Finish just below the top of the padding and secure with tape
- ▶ Turn over any excess tubular bandage to finish off (Figure 14)
- ▶ One layer of short-stretch (inelastic) bandage will be adequate to provide support and palliation
- ▶ The bandages should be removed and reapplied daily because the inelastic qualities prevent them conforming to the limb as the circumference reduces in size (Board and Harlow, 2002). At each change of bandage observe the patient's skin condition and look for any signs of pressure damage or rubbing at skin creases.

When the initial aim of stopping lymphorrhoea, improving skin condition and regaining limb shape has been achieved, a light compression sleeve (Class 1: <21 mmHg) can be fitted, provided the patient can tolerate it. An alternative choice would be an appropriately sized and shaped Tubigrip, although nurses should be aware that it has the potential to roll at the top of the limb. If this occurs, skin adhesive can be used to hold it in place. Daily monitoring is advised to observe for any limb-shape distortion, marks or indents to the skin or general deterioration of the limb. If any of the above occur, the authors' recommend restarting palliative bandaging.

Modifications for specific problems

Limb-shape distortion, especially of hand and fingers

As the oedema increases, further distortion of limb shape can occur, with frequent problem areas including the dorsum of the hand and the fingers, especially at the base. When the bases of the fingers are swollen and distorted they are vulnerable to damage if the bandage slips during movement. A 'handprint' cut out

of soft foam (Figure 15) can be incorporated into the bandage to protect the palmar aspect of the hand and fingers (Figures 16, 17).

If the dorsum of the hand is very large it can be difficult to achieve the correct directional pressure. A length of soft, dense, bevelled-edge foam or soft foam with finger holes cut out can be used (Figures 18, 19). Anchor this under the soft synthetic wool padding, with a slight 'pull' towards the axilla to achieve the directional pressure.

Reduced mobility of the arm and skin breakdown

In the later stages, advancing disease can result in increased oedema, further deterioration of the skin and loss of mobility and function. The skin becomes more fragile, leading to possible breakdown and ulceration. With brachial plexus involvement there may be varying degrees of altered sensation and, in some cases, complete paralysis.

In the authors' experience, when the patient has reduced limb function, either due to the weight of the limb, brachial plexopathy or purely due to the stage of illness, the use of a long-stretch (elastic) bandage, such as K-lite® (Urgo) can be beneficial. Apply this over the padded arm (as previously described) and use a single layer, spiralled, with slight stretch only. Due to the immobility of the limb, the patient will not be able to muscle pump. Therefore, by using a long-stretch bandage a constant low pressure (<15mmHg) can be obtained, even at rest. In the authors' clinical experience, this type of bandage should also be removed and reapplied daily in order that the integrity of the skin can be checked.

'Boxing glove' bandage

If the patient cannot tolerate finger bandages, due either to gross distortion, fragility of the skin or pain, the hand can be bandaged in a 'boxing glove' style. Use a ball of soft padding in the palm (Figure 20) and padding between the fingers if necessary, to support and protect (Figures 21, 22).

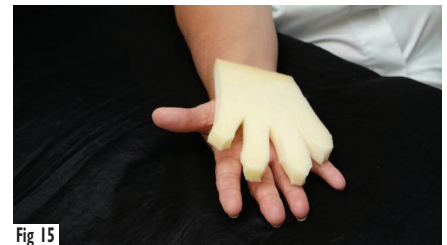

Fig 15

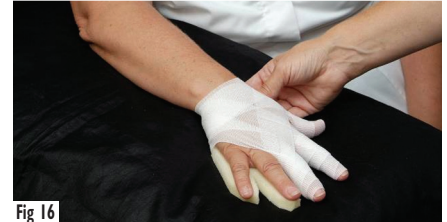

Fig 16

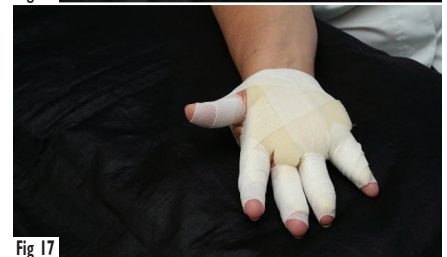

Fig 17



Fig 18

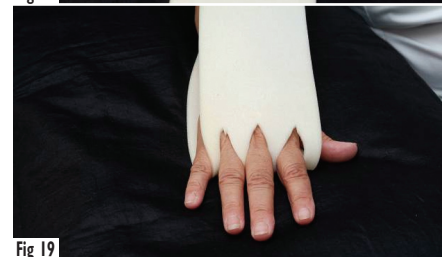

Fig 19

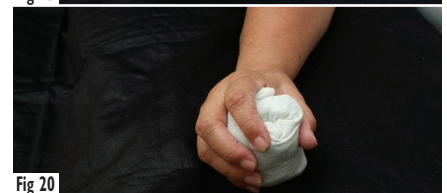


Fig 20

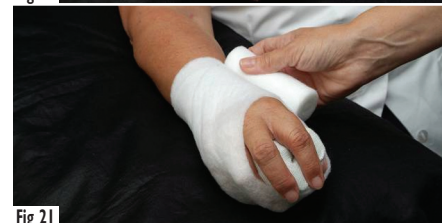

Fig 21

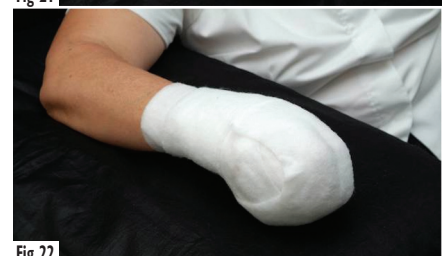

Fig 22

Supportive bandaging

In the authors' experience, many patients with advanced malignancy and severe oedema prefer to have the limb bandaged for aesthetic reasons but may not be able to tolerate even minimal pressure. In these cases, the aim of the bandage is for support only. Support can be defined as the retention and control of tissue without the application of compression (Thomas, 1990).

With this type of bandage, copious padding (e.g. Cellona) is applied to all areas of the limb followed by a light, long-stretch bandage (K-lite) applied using a spiral technique with 50% overlap and no stretch (thus no pressure).

The weight of the limb bears a direct correlation to the increased volume of oedema which, in turn, can cause associated pain in the wrist, elbow, shoulder and cervical spine. Severe oedema causes a reduction in the range of joint movement, especially noticeable in the fingers and hand, which impacts on the activities of daily living. In these cases, the use of a sling, such as the Lancaster Shoulder Brace, which redistributes the weight of the arm away from the shoulder and neck to across the back is recommended.

Lymphorrhoea

If lymphorrhoea is present, additional padding (e.g. Cellona or Profore #1) is added to the appropriate type of palliative bandage to absorb the leakage. Compression, if tolerated, helps to reduce lymphorrhoea, but in some situations the leakage may be extensive and the bandage may need to be changed several times per day.

Any compression applied to the arm can cause increased leakage from ulcerated areas or fungating lesions on the chest wall or in the axilla. This occurrence may affect the choice of bandaging method. In those patients who prefer to cope with a slightly more swollen arm and less discharge from the lesions, a supportive bandage may be applied.

However, in those where the weight of the arm and impaired function is the main concern, then a reduced pressure MLLB to reduce limb volume is appropriate. In this case, extra padding may need to be modified to accommodate the increased leakage.

Who should perform palliative bandaging?

In the palliative care setting, clinical judgement must be exercised to decide on the correct type of palliative/support bandage that will provide comfort and quality of life.

Palliative bandaging should always be adapted to the individual, considering such issues as the integrity of the skin, consistency of the tissue, and size and shape of the limb. As discussed above, the patient's general state of health and other contributory factors that may be present, such as peripheral neuropathy, diabetes and circulatory abnormalities, should be considered.

An incorrectly applied bandage can cause pain, skin damage and ulceration and may compromise the arterial circulation. It is therefore very important that palliative bandages are applied by a nurse who is appropriately trained and has a comprehensive knowledge of the concepts of bandaging in order to carry out the technique effectively and safely (Board and Harlow, 2002). This does not necessarily have to be a lymphoedema specialist.

As patients requiring palliative bandaging are often unwell and may need daily bandage changes, appropriately trained community staff should be accessible.

Conclusion

In the application of palliative bandages there are many variables to consider, such as skin integrity, pain, the aim of the bandaging and the patient's general condition. The timescale of disease progression can be relatively short or prolonged in different patients. Thus, in order to achieve the maximum comfort a whole range of palliative bandaging techniques should be available.

Key Points

- ▶▶ Several varieties of palliative bandaging are required to address specific problems experienced by patients.
- ▶▶ It is important to be clear about the aims of treatment.
- ▶▶ The benefits and risks of palliative bandaging should be assessed.
- ▶▶ Palliative bandaging should be carried out by healthcare professionals who have the appropriate training and skills.
- ▶▶ Other palliative care approaches to symptom management in patients with arm oedema and advanced breast cancer should also be considered.

It is extremely important to be clear about the aims of treatment and to select the appropriate bandaging method. The benefits and risks need to be considered and the patient enabled to make an informed decision about the method chosen. JL

References

- Board J, Harlow W (2002) Lymphoedema 3: The available treatments for lymphoedema. *Br J Nurs* 11(7): 438–50
- Keeley VL (2007) Lymphedema. In: Berger AM, Shuster JL, von Roem JH, eds. *Principles of Palliative Care and Supportive Oncology*. 3rd edn. Lippincott, Williams & Wilkins, Philadelphia, USA: 253–64
- Lymphoedema Framework (2006) *Best Practice for the Management of Lymphoedema*. International Consensus. MEP Ltd, London
- NICE (2004) *Improving Supportive and Palliative Care for Adults with Cancer*. NICE, Leeds
- Thomas S (1990) Bandages and bandaging: the science behind the art. *Care Sci Prac* 8(22): 50–60