

A NEW TREATMENT FOR SOFT TISSUE FIBROSIS IN THE BREAST

Karen Ashforth, Sonja Morgner, Lisa VanHoose

Abstract

Background: Soft tissue fibrosis is a common consequence of breast cancer treatment and chronic lymphoedema. It can compromise function and quality of life, but research regarding interventions is limited. **Aims:** To assess the efficacy of using JoViPitPak® (JoviPak Corporation) to influence soft tissue fibrosis change by looking at tissue density, perceived cosmesis and perceived breast pain. **Methods:** This case series examined four breast cancer patients with stage 2 lymphoedema, post lumpectomy surgery and radiation therapy. All patients were instructed in manual lymphatic drainage (MLD) and utilised elastic compression for breast oedema before receiving treatment for soft tissue fibrosis. Treatment consisted of using JoViPitPak®, a compression garment developed specifically for treatment of soft tissue fibrosis, which was worn upon the breast under elastic compression for two hours each day for three weeks. Pre- and post-treatment fibrosis was assessed with tissue tonometry, perception of cosmesis was assessed with a questionnaire, and breast pain was measured using an analogue pain scale. **Results:** Patients demonstrated decreased tissue density, increased perceived cosmesis and a decrease in perceived breast pain. **Conclusion:** The JoViPitPak® was efficacious in reducing the effects of soft tissue fibrosis. Additional randomised studies are warranted to further assess the efficacy of this treatment approach. **Declaration of interest:** None.

Key words

Lymphoedema
Fibrosis
Breast cancer
JoViPitPak®
Tonometry

Fibrosis is a well-documented and unfortunately common side-effect of breast cancer treatment (Archambeau et al, 1995; Johannson et al, 2000; Jothy Basu et al, 2008; Lawanda et al, 2009). Many cancer patients with lymphoedema have altered tissue composition and density from lymphostatic fibrosis, a result of chronic congestion of

interstitial fluid (Brorson et al, 2006; Földi and Földi, 2003). Surgery, chemotherapy, hormonal therapy, radiation therapy and cellulitis can also create detrimental tissue changes (Archambeau et al, 1995; Bentzen and Dische, 2000; Delanian and Lefaix, 2004; Goffman et al, 2004;

specialised manual lymphatic drainage (MLD) (Földi and Földi, 2003), low level laser therapy (LLLT) (Carati et al, 2003; Piller and Thelander, 1998), short-stretch bandaging over various types of solid foam (Földi and Földi, 2004; Stewart, 2004; Zuther, 2005), and truncal compression garments or short-stretch bandages over foam chip pads (Gergich and Bell, 2004).

Although soft tissue fibrosis is a common consequence of chronic lymphoedema and can compromise function and quality of life, little research has focused on effective treatment modalities.

Iyer and Jhingran, 2006; Johannson et al, 2000, Lawanda et al, 2009; Rönka et al, 2004). Although soft tissue fibrosis is a common consequence of chronic lymphoedema and can compromise function and quality of life, little research has focused on effective treatment modalities. Current modalities used to treat fibrosis include

Treatment and prevention of fibrosis is a priority for lymphoedema treatment at Dominican Santa Cruz Hospital's 'Lymphedema Management Program'. As part of the hospital's basic complete decongestive therapy (CDT) programme, the authors stress the need for decongestion and compression to manage oedema symptoms and prevent progression of lymphostatic fibrosis. Unfortunately, clients are seldom referred during the latent and stage 1 phases of lymphoedema. The authors have recognised a trend for many stage 2 and 3 lymphoedema patients with surgical, radiological or lymphostatic fibrosis to develop cellulitis, which spirals into increasingly harder and

Karen Ashforth is a Staff Occupational Therapist III and Clinic Director, Lymphedema Management Program, Dominican Santa Cruz Hospital, Santa Cruz, California, USA; Sonja Morgner is a Staff Physical Therapist, Private Community Practice, Santa Cruz, California, USA; Lisa VanHoose is a Research Assistant Professor, University of Kansas Medical Center, Kansas City, Kansas, USA

more congested tissues. The focus with these stage 2 and 3 lymphoedema patients is on ameliorating oedema and improving tissue quality by using anti-fibrotic techniques in conjunction with CDT. The authors' clinic currently uses low level laser; chip foam and cherry pit compression pads and garments, textured elastic compression garments, specialised manual techniques, such as myofascial release and instrument-aided soft tissue mobilisation, and pneumatic compression to ameliorate brawny hard swelling that does not recede with elevation.

Cherry pit compression pads were introduced on a trial and then adopted as standard care due to their success rate in quickly treating fibrosis. For years the clinic routinely used compression garments consisting of chipped foam quilted between two layers of fabric and had observed favourable results with both oedema and fibrosis. The effects on oedema of quilted foam garments have been seen to occur quickly — within days and weeks — but changes in fibrotic tissue took much longer — weeks or even months. A more aggressive treatment was sought and the cherry pit pads were chosen due to their harder texture, because it was observed that harder densities of chip foam were more effective than the softer ones at softening fibrotic tissue. The JoViPitPak® (JoviPack Corporation) consists of commercially cleaned and dried cherry pits quilted between two layers of fabric. They are made in standard and custom sizes, shapes and thicknesses, depending upon the body part treated. Like chip foam, cherry pits can be washed by hand or machine and air drying is recommended. Although none of the subjects in this study had adverse effects, in rare cases it has been observed that the use of cherry pits can cause bruising and discomfort if used under compression for an extended time over bony areas, such as the ribs.

This case series examined four breast cancer patients with stage 2 lymphoedema, after lumpectomy surgery and radiation therapy. Subjects received decongestive treatment

for lymphoedema in addition to the JoViPitPak, a new treatment modality for breast fibrosis developed by lymphoedema therapists Karen Ashforth and Sonja Morgner. It was then assessed whether the addition of this new modality would result in better outcomes, compared with decongestive treatment alone when treating soft tissue fibrosis.

Methods

All subjects received an initial assessment and were taught self-manual lymphatic drainage (MLD). Subjects performed self-MLD daily at home and wore daytime elastic compression for breast oedema for two weeks, at which time they were reassessed.

After two weeks, they received treatment for soft tissue fibrosis using a JoViPitPak, which was worn upon the breast under elastic compression for two hours per day for three weeks. The rationale for using the timescale of two hours per day was based upon prior clinical observation of effectiveness. For the purposes of this study, the JoviPitPaks used were round and 6 inches (15.2cm) in diameter and 1 inch (25mm) thick, with three quilted compartments containing loose cherry pits (Figure 1).

Description of subjects

Requirements for inclusion in this study were completion of radiation therapy and post lumpectomy surgery for breast cancer. The group of patients for the study was selected by consecutive referral with inclusion characteristics. All subjects were women aged between 39 and 55 years. Post-surgical status ranged from nine months to 12.5 years. All had completed radiation therapy from 3.5 weeks to 12 years before the start of the study, and some subjects were still undergoing chemotherapy. All subjects had extremity lymphoedema as well as in the breast, but none had been treated previously for lymphoedema symptoms. Half of all the subjects had metastatic as well as primary disease. All subjects had axillary lymph node dissection, making them more vulnerable to




Figure 1. JoViPitPak®, courtesy of JoViPak Corporation.

breast oedema and therefore increased incidence of breast tissue fibrosis (Lucci et al, 2007; Lawanda and Mondry, 2009; Rönkä et al, 2004). Written informed consent was obtained from all patients before they took part in the study. Ethics approval for the study was obtained from the Dominican Hospital institutional review board.

Assessments of fibrosis

In addition to an intake evaluation which included a review of the patient's medical history, subjective and functional complaints, circumferential arm measurements and tissue assessment, all subjects were evaluated with tonometry, a breast cosmesis questionnaire which was developed specifically for this study, and a visual analogue pain scale.

Three assessments were made:

- ▶▶ Initial: before any treatment;
- ▶▶ Interim: after two weeks of conservative therapy for proximal and extremity lymphoedema consisting of elastic compression and self-MLD, before introduction of JoViPitPak
- ▶▶ Final: after three weeks of treatment with JoViPitPak in addition to conservative therapy.

Tonometry

The instrument used was the Flinders Tissue Tonometer. This mechanical device consists of a manual tonometer with a 200g weight. The tonometer is always calibrated before use. The sites measured were the most palpably dense portion of the breast, and patients were positioned on their

Table 1

Effects of treatment on tissue density (measured by tonometry)

	Assessments			Effect of therapy (%)	
	Initial	Interim	Final	Conservative therapy change	JoViPitPak change
Subject 1	4.42	4.6	6.53	4.07%	41.96%
Subject 2	4.65	5.17	5.9	11.18%	14.12%
Subject 3	5.65	3.25	3.79	-42.48%	16.62%
Subject 4	5.82	5.91	6.95	1.55%	17.60%
Average				5.6%	22.58%

Subject 3 was excluded from averaging in conservative therapy change between assessments I and II

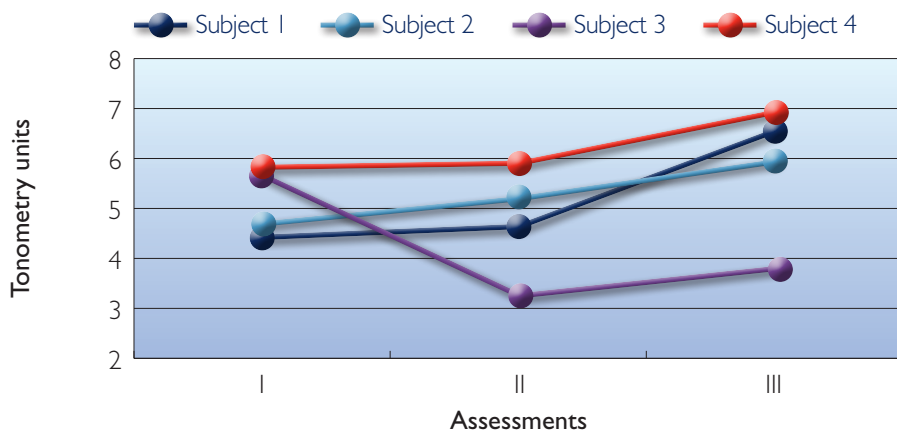


Figure 2. Tissue density.

side to allow the tonometer to be in a vertical position. Landmarks such as the nipple and surgical scars were used as reference points to allow for consistency in each measurement. Because the tonometer compresses tissues over time and with repeated use, a single reading was taken five seconds from the time the tonometer was placed. Since fibrotic tissue is more resistant to compression than normal tissue, and soft pitting oedema less resistant to compression than normal tissue, lower readings indicate harder tissue (Bagheri et al, 2005; Chen et al, 1988; Clodius et al, 1976).

Breast cosmesis questionnaire

Patients used an analog 0–10 scale to rate their perception of their affected breast compared with the non-affected breast in areas of:

- » Breast density
- » Skin density
- » Skin appearance
- » Swelling
- » Overall cosmetic appearance.

The highest combined possible score was 0, indicating the lowest level of perceived impairment of cosmesis (best cosmetic assessment), and the lowest combined possible score was 50, indicating the highest level of perceived impaired cosmesis. One subject declined to rate two categories (skin and cosmetic appearance); her scoring was based on a maximum highest possible score of 30.

Visual analogue pain scale

The horizontal version was used for this study (Tiplady et al, 1998). The scale is a straight 10cm line with one

end signifying no pain and the other end the worst pain imaginable. Patients were asked to rate their current level of breast pain as an increment of 0 to 10, and if they had variable pain to describe the range of pain on the scale.

Results

Subjects demonstrated significant improvements in one of the three domains (perception of cosmesis) following additional use of JoViPitPak. However, trends were observed in tissue density and pain, but significance was not achieved due to the small sample size.

Subjects demonstrated an average decrease of 5.60% in tissue density after conservative treatment, and a further average decrease of 24.56% in tissue density after the addition of JoViPitPak (Table 1, Figure 2). However, the variance in therapeutic responsiveness to the JoViPitPak may have caused the loss of significance between the two therapies, $t(2)=-1.86, p=0.20$. A trend towards a decrease in tissue density is observed based on the raw scores of subjects 1, 2 and 4.

Average perception of cosmesis improved by 10.00% after conservative treatment and a further average increase after the addition of a JoViPitPak of 47.86% (Table 2, Figure 3). A significant difference between the two therapies was observed based on the average change score, $t(3)=5.24, p\leq 0.01$.

Average changes in perceived breast pain were 50% after conservative treatment, with a further average reduction of 66.67% with the addition of JoViPitPak (Table 3, Figure 4). The authors did not observe significance between these two therapies, $t(1)=0.50, p=0.71$, which included the measurements of subjects 2 and 3.

Exclusions from averaging Tonometry

Tonometry measures surface tissue density, not tissue composition. Subject 3 was excluded from the average change between initial and interim measurements because her acutely

Table 2

Effects of treatment on perceived breast cosmesis

	Assessments			Effect of therapy (%)	
	Initial	Interim	Final	Conservative therapy change	JoViPitPak change
Subject 1	80.00%	80.00%	57.00%	0.00%	-28.75%
Subject 2	62.00%	42.00%	11.00%	-32.36%	-73.81%
Subject 3	84.00%	72.00%	44.00%	-14.29%	-38.89%
Subject 4	100.00%	93.00%	46.67%	6.67%	-50.00%
Average	81.5±15.61	71.75±21.64	39.67±19.92	-10.00±17.29	-47.86%±19.35

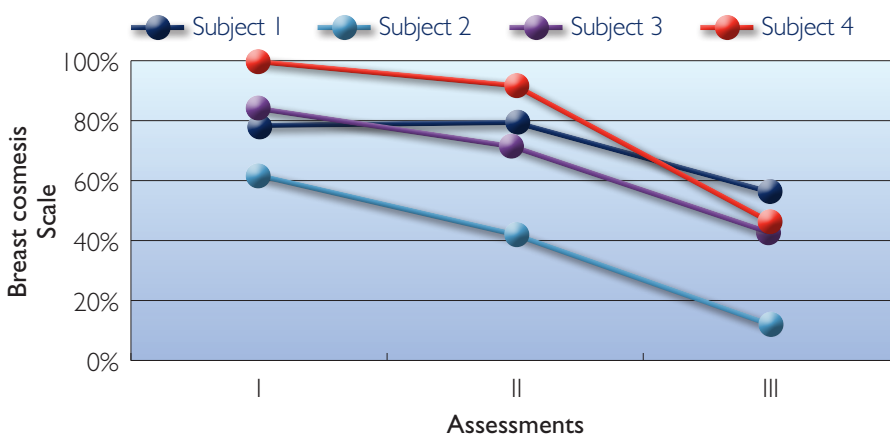


Figure 3. Perceived breast cosmesis.

high degree of swelling at the time of the initial assessment yielded a high initial tonometry reading. Following two weeks of conservative treatment, her subsequent readings were substantially lower because the layer of soft oedema was reduced, allowing more accurate measurement of the change in the denser fibrotic scar and radiated tissue.

Pain

Subjects 1 and 4 had no complaints of breast pain and were excluded from averaging.

Discussion

Statistical analysis

Descriptive statistics was used to characterise the subjects. Paired t-tests with a Bonferroni correction were used to determine differences between two time points corresponding to conservative and JoViPitPak therapy,

Patients demonstrated favourable results after short-term use of JoViPitPak for amelioration of soft tissue fibrosis effects.

(conservative = initial and interim; JoViPitPak = interim and final). The adjusted p-value for significance was 0.02 (0.05/3 hypotheses). The benefit of the therapies was based on the percent change of the outcome measures and the significant difference between the percent changes of the two therapies was noted as #. Tissue density analysis included three subjects, because subject 3 was excluded.

Limitations

This study was conducted with a small

sample size over a relatively short span of time. A larger cohort and a longer study period would have yielded more information. It would be useful to study the long-term ameliorative effects of this treatment and compare groups of subjects who continue to use the treatment versus those who stop. Studying those who have chronic lymphoedema and have previously been treated for fibrosis would be valuable, particularly subjects who have already experienced a period of decongestion and have established programmes to eliminate the incidence of oedema masking accurate measurement of tissue density, as in subject 3.

This study focused solely on breast fibrosis and did not examine the impact and interaction of oedema, fibrosis or the treatment thereof on other areas of the upper quadrant, such as the arm, axilla or torso. It might also be useful to examine the effects of this treatment on specific or mixed types of fibrosis in different areas of the body, as well as comparing the effectiveness among those who have histories of oedema and fibrosis for varying lengths of time.

Although a formal control group was not used, the subjects in this study acted as their own control group since they had received treatment before the introduction of JoViPitPak.

Future studies on breast fibrosis would benefit from imaging assessment tools which are more descriptive of depth and nature of fibrotic tissue, such as ultrasound or magnetic resonance imaging (MRI).

Conclusions

Patients demonstrated favourable results after short-term use of JoViPitPak for amelioration of soft tissue fibrosis effects. Due to the fact that early treatment of fibrosis has become standard of care at the primary author's clinic, it was considered unethical to withhold this new modality and so a control group was not feasible. Long-term effects are unknown. Follow-up studies are indicated to further assess the efficacy of this treatment approach. In particular,

Table 3

Effects of treatment on perceived breast pain

	Initial	Interim	Final	Conservative therapy change	JoViPitPak change
Subject 2	3.0	1.5	1.0	-50.00%	-33.33%
Subject 3	2.0	1.0	0.0	-50.00%	-100.00%
Average				-50.00%	-66.67%

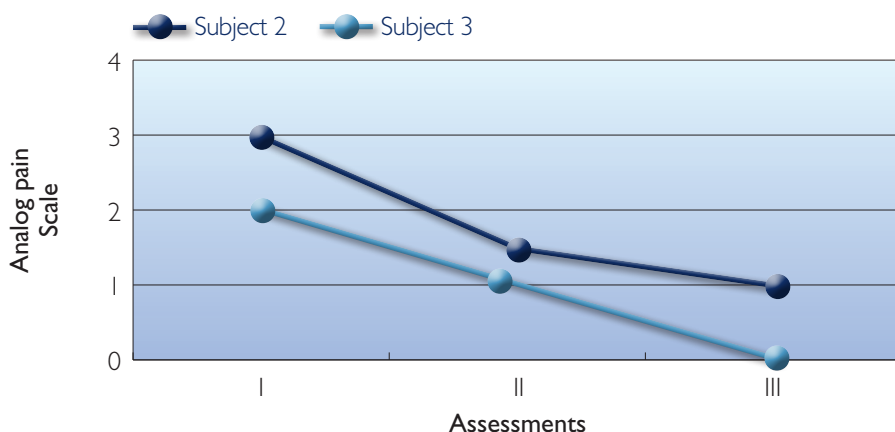


Figure 3. Perceived breast pain.

studies to determine frequency and duration of use. JL

References

Archambeau JO, Pezner R, Wasserman T (1995) Pathophysiology of irradiation skin and breast. *Int J Radiation Oncology Biol Phys* 31: 1171–85

Bagheri S, Ohlin K, Olsson G, Brorson H (2005) Tissue tonometry before and after liposuction of arm lymphedema following breast cancer. *Lymphatic Res Biol* 3: 66–80

Bentzen SM, Dische S (2000) Morbidity related to axillary irradiation in the treatment of breast cancer. *Acta Oncologica* 39: 337–47

Brorson H, Ohlin K, Olsson G, Langstrom G, Wiklund I, Svensson H (2006) Quality of life following liposuction and conservative treatment of arm lymphedema. *Lymphology* 39: 8–25

Carati CJ, Anderson SN, Gannon BJ, Piller NB (2003) Treatment of post-mastectomy lymphoedema with low level laser therapy: a double blind, placebo controlled trial. *Cancer* 98: 1114–22

Chen HC, McC. O'Brien B, Pribaz JJ, Roberts AHN (1988) The use of tonometry in the assessment of upper extremity

lymphoedema. *Br J Plast Surgery* 41: 399–402

Clodius L, Deak L, Piller NB (1976) The use of tissue tonometry as a diagnostic aide in extremity lymphoedema. *Lymphology* 9: 1–5

Delanian S, Lefaix JL (2004) The radiation-induced fibroatrophic process: therapeutic perspective via the antioxidant pathway. *Radiation Oncology* 73: 119–131

Földi M, Földi E (2003) Lymphostatic diseases. In: Foldi M, Foldi E, Kubik S, eds. *Textbook of Lymphology for Physicians and Lymphedema Therapists*. 1st edn. Urban & Fischer, Munich: 254, 511

Gergich N, Bell L (2004) Focus on breast and chest wall LE. *Lymphlink* 16: 22

Goffman TE, Laronga C, Wilson L, Elkins D (2004) Lymphedema in the arm and breast in irradiated breast cancer patients: risks of an era of dramatically changing breast cancer surgery. *Breast J* 10(5): 405–11

Iyer R, Jhingran A (2006) Radiation injury: imaging finding in the chest, abdomen and pelvis after therapeutic radiation. *Cancer Imaging* 6: S131–S139

Johansson S, Svensson H, Denekamp J (2000) Timescale of evolution of late radiation injury after postoperative

radiotherapy of breast cancer patients. *Int J Radiation Oncology Biol Phys* 48: 745–50

Jothy Basu KS, Bahl A, Subramani V, Sharma DN, Rath GK, Julka PK (2008) Normal tissue complication probability of fibrosis in radiotherapy of breast cancer: accelerated partial breast irradiation vs conventional external-beam radiotherapy. *J Cancer Res Ther* 4(3): 126–30

Lawanda BD, Mondry TE, Johnstone PAS (2009) Lymphedema: a primer on the identification and management of a chronic condition in oncologic treatment. *CA Cancer J Clin* 59: 8–24

Lucci A, McCall LM, Beitsch PD, et al (2007) Surgical complications associated with sentinel lymph node dissection (SLND) plus axillary lymph node dissection compared with SCND alone in the American college of surgeons oncology group trial Z0011. *J Clin Oncology* 25: 3657–63

Piller NB, Thelander A (1998) Treatment of chronic postmastectomy lymphoedema with low level laser therapy: A 2.5 year follow-up. *Lymphology* 31: 74–86

Rönkä RH, Pamilo MS, von Smitten KAJ, Leidenius MHK (2004) Breast lymphedema after breast conserving treatment. *Acta Oncologica* 43: 551–7

Stewart PJB (2004) Lymphlink Question Corner. *Lymphlink* 16: 10

Tiplady B, Jackson SHD, Maskrey NM, Swift CG (1998) Validity and sensitivity of visual analogue scales in young and older healthy subjects. *Age Aging* 27: 63–6

Zuther J (2005) The benefits of daily use of compression therapy for lymphedema. *Elymphnotes.org* 2

Key points

- ▶▶ Fibrosis is a common side-effect of breast cancer treatment.
- ▶▶ There are few documented clinical treatments for soft tissue fibrosis.
- ▶▶ The use of the JoViPitPak® compression garment improved pain, perceived cosmesis and tissue density in a trial of three weeks with four subjects with stage 2 lymphoedema.