

Impact of lymphovenous anastomosis on limb circumference in patients with lymphoedema tarda

Sunanda Hadiwattage, Lakshman Watawana, Sooriyaratthige Pradeep Manjula Peiris and Kuda Banda Galketiya

Key words

Limb circumference
Lymphoedema tarda
Lymphovenous anastomosis

Sunanda Hadiwattage is Senior Registrar in General Surgery with special interest in microvascular surgery; Lakshman Watawana is Senior Lecturer and Nuclear Medicine Physician; Sooriyaratthige Pradeep Manjula Peiris is Consultant Surgeon and Senior Lecturer; Kuda Banda Galketiya is Senior Consultant Surgeon, Head of the Department and Professor in Surgery; all at University surgical unit, Teaching Hospital, Peradeniya, Sri Lanka

Declaration of interest: None

Hereditary lymphoedema is a rare disorder affecting the lymphatic system. There are three forms of hereditary lymphoedema: congenital hereditary lymphoedema or Milroy's disease; lymphoedema praecox or Meige disease; and lymphoedema tarda (National Organization for Rare Disorders [NORD], 2015). Lymphoedema tarda manifests after the age of 35, most often affects the legs, and is the result of local failure of the lymphatic system to drain lymph away from the limbs (NORD, 2015). In the early stages, blocked lymphatics become distended with pooled lymph. Over time, chronic lymphoedema develops, which is often associated with significant psychosocial and physical morbidity (Fu et al, 2013; Greene, 2015). Complications, such as acute and chronic infection, cause an additional burden (Greene, 2015).

Abstract

Lymphoedema tarda is thought to result from congenitally deficient lymphatic reserve. Incompetent lymphatic valves lead to local failure of the lymphatic system and reduce the ability of the remaining lymphatics to drain lymph, leading to late-onset chronic lymphoedema. In this study, eight patients with lower-limb lymphoedema with obstructed lymphatics diagnosed by lymphoscintigraphy underwent lymphovenous anastomosis. Participants' initial limb circumferences were measured at the end of a normal working day and at monthly clinics thereafter for a mean follow-up of 18.25 months. There was a 13.3% reduction in mean limb circumference, with six patients (75%) experiencing a significant reduction in circumference. The creation of lymphovenous anastomosis in lymphoedema tarda had a positive outcome in this small study, suggesting that further studies are warranted.

Several imaging tests can be used to evaluate lymphoedema, including ultrasound, magnetic resonance imaging and lymphoscintigraphy. In lymphoscintigraphy, a radiolabelled substance is injected and the time taken to reach the regional lymph nodes measured to identify blockages in the lymphatic system.

Treatment should aim to reduce swelling and prevent infection, and includes compression bandaging or garments, manual lymph drainage, exercise and skin care (NORD, 2015). Various surgical techniques can be used to treat patients, including surgically joining small lymphatic vessels to nearby small veins (microsurgical anastomosis). The aim of this surgery is to reduce swelling by rechannelling lymph flow into the venous system. The authors decided to determine whether their lymphoedema tarda patients would benefit from lymphovenous anastomosis surgery.

Methods

Patients with clinically-diagnosed lymphoedema tarda who had dilated lymphatics on their lymphoscintigrams were offered lymphovenous anastomosis to surgically restore the flow of lymph fluid back to their venous systems. Informed written consent was obtained for the surgery and for publication of the anonymised clinical data.

Eight patients agreed to participate. Six participants had stage II lymphoedema and two had stage III lymphoedema (Patients 3 and 5). The participants were female, aged 34 to 41 years, wore a pressure stocking and were taking prophylactic oral penicillin 500 mg daily. Prior to surgery, the presence of venous disease of the lower limb was excluded with a Duplex scan. All of the patients who agreed to undergo the procedure tested negative for *Filaria* antibodies.

Table 1. Average percentage reduction in lower limb circumference following surgery.

Level at which the circumference was measured	Percentage reduction
10 cm above the mid point of the patella	9.7
Mid point of the patella	8.7
10 cm distal to the mid point of the patella	10.2
Mid leg level	9.4
10 cm proximal to the medial malleolus	13.7
Medial malleolus	13.4
10 cm distal to the medial malleolus	6.0

The surgery

Lymphovenous anastomosis was performed at Teaching Hospital Peradeniya in Sri Lanka. The incision site was determined by the position of the dilated lymphatics identified in the lymphoscintigram. Patients were started on intravenous ciprofloxacin 400 mg (12 hourly) 24 hours before surgery and continued for 24 hours after surgery. Two days post surgery, each patient was discharged with 3 days of oral ciprofloxacin (50mg, 12 hourly) and aspirin 75 mg to be taken every day for the rest of their life. On the completion of oral ciprofloxacin, patients were prescribed oral penicillin 500 mg daily, again, to be taken for the rest of their life.

Prior to surgery, the paths of the affected veins and lymphatics were marked out. A transverse incision was made 10 cm distal to the knee joint and extending across the long and short saphenous veins in the six patients with dilated lymphatics in the lateral and medial lymphatic drainage systems. In patient 3 and patient 5, who had an isolated medial lymphatic system obstruction, a transverse incision was made 10 cm proximal to the knee joint that extended along the path of the long saphenous vein.

All dissections were performed under a surgical binocular microscope with adjustable magnification (5–30 times) and X, Y and Z axis control to adjust the focus. Following the incision, methylene blue dye was injected subcutaneously, 10 cm distal to the incision site. The tissue was dissected down to the deep fascia with gentle retraction. Colour-enhanced long, slender, tubular structures were identified as the lymphatics and marked with green rubber tape passed under the structure and held in place with small forceps. Arteries were identified by their pulsation and veins by their comparatively thinner walls. The veins

were marked with blue rubber tape held in place with small forceps. Patients were given intravenous unfractionated heparin 80 mg/kg 5 minutes before the veins were divided for anastomosis. A fluid sample from the proximal end of the divided lymphatics was placed on a glass slide, air dried and examined intraoperatively under a laboratory microscope. A red blood cell count of less than 20 per high power field was considered confirmatory of the divided tubular stricture being a lymphatic vessel. End-to-end lymphovenous anastomoses were performed using 10/0 polypropylene sutures made with a 3.8 mm needle with a microcutting tip. In each patient, an average of five lymphatics were successfully anastomosed to veins (range: four to six).

A 20–30 mmHg pressure bandage was applied to the limb distal to the surgery site. This dressing was kept *in situ* for 4 days. Following the removal of the dressing, patients were advised to perform normal day-to-day activities and to massage the affected limb twice daily with olive oil. Patients were also advised to wear a 20–30 mmHg pressure stocking, similar to the ones they were wearing prior to surgery, extending from the toes to above-knee level, except while asleep. This was prescribed for life.

Follow-up

Patients were followed up on a monthly basis. At each clinic visit, circumferential measurements were made at the following points:

- 10 cm above the middle of the patella
- Middle of the patella
- 10 cm below the middle of the patella
- Mid-leg level
- 10 cm above the ankle medial malleolus
- Medial malleolus level
- 10 cm below to the ankle medial malleolus.

All measurements were made by the

same person. The data were tabulated and analysed using Microsoft Excel spreadsheet software.

Results

Patients were followed up for a mean of 18.25 months (range: 16–21 months). The average reductions in lower-limb circumference following surgery are given in Table 1. All eight patients indicated that the pain and tension they had felt in their lower limb, usually towards the end of the day, had resolved after surgery.

Six out of eight patients showed a clinically significant reduction in limb circumference. The reduction in circumference for these patients was 16% (range: 11.1–21.4%), and was greatest 10 cm above the ankle. Patients 3 and 4 had no significant reduction in limb circumference. Figure 1 shows the patients’ medial malleolus level ankle circumference on the morning of surgery and monthly thereafter. The X axis represents the postoperative period of Patient 1.

Two of the six patients (patient 1 and patient 6) had a significant reduction of ankle circumference 10 cm distal to the ankle. However, their feet remained swollen with only a 2.1%–2.3% reduction in foot circumference.

Reductions in circumference were mostly noted 2 months or more after surgery. Discolouration of the skin due to the methylene blue dye had completely disappeared by 2 months post surgery.

Discussion

Lymphovenous anastomosis is a challenging microvascular surgery due to the technical difficulty of dealing with microscopic structures, as well as characterising and localising the obstructed, dilated lymphatics. Proper guidance by the nuclear medicine department and preoperative discussions leading to tailor-made operative planning is mandatory to maximise the chance of success. In this study, all of the lymphovenous anastomoses were performed in an end-to-end manner.

Lymphovenous anastomosis has been reported to reduce stage I idiopathic lymphoedema by 33–41% and stage II lymphoedema by 0–14% (Olszewski, 2013). Głowiczki et al (1988) suggested that lymphovenous anastomosis has a poor outcome in primary lymphoedema compared to secondary lymphoedema. Despite this, Campisi et al (2001) reported

positive results from long-term follow-up of 446 patients who had undergone lymphovenous anastomosis. At a mean follow-up of 7 years, there was an average reduction in excess limb volume of 69% and 85% of patients were able to discontinue the use of conservative treatment measures. There was also an 87% reduction in cellulitis, a reduction in peripheral oedema and increased limb softness in most patients (Campisi et al, 2001). A study by Maegawa et al (2012) with a shorter follow-up showed a cumulative patency rate of 75% at 12 months and 36% 24 months after surgery, as shown on lymphoscintigraphy. In this study, side-to-end lymphovenous anastomosis was used, which is a different technique to the other studies, which used end-to end anastomosis (Gloviczki et al, 1988; Campisi et al, 2001; Olszewski, 2013) and may have an impact on outcomes.

Most of the published articles describe limb volume reduction, while this study measured reduction in circumference. All eight patients were satisfied by the outcome of surgery, since they no longer felt tension and pain in the affected lower limb following prolonged standing. Objectively, the gradual reduction in limb circumference seen in six patients confirmed that the newly-created shunts were draining the pooled lymph.

The trauma due to surgery was minimal and the recovery was rapid in our participants. No infective complications were encountered. Patients were concerned about the skin discolouration due to injection of the dye distal to the surgical site, but this had completely disappeared 2 months after surgery.

Conclusion

Patients with lymphoedema tarda that shows lymphatic obstruction on lymphoscintigraphy can benefit from

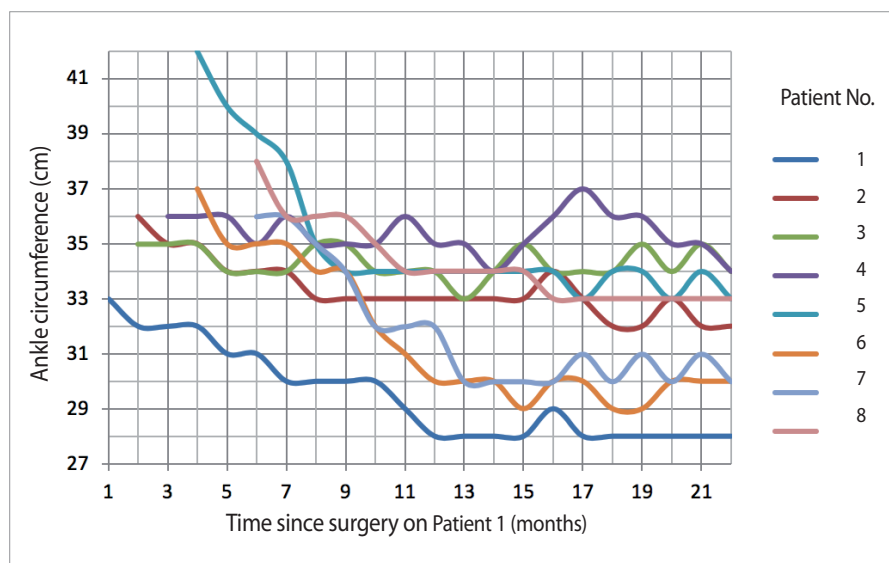


Figure 1. Patients' ankle circumference over time following lymphovenous anastomosis.

the surgical creation of lymphovenous anastomoses. Offering this surgery to patients with stage II and III lymphoedema tarda is justified, since it appeared to reverse progression of the disease in 75% of our patients. Further follow up and larger studies are needed to assess the outcomes from this study.

References

- Campisi C, Boccardo F, Zilli A et al (2001) Long-term results after lymphatic-venous anastomoses for the treatment of obstructive lymphedema. *Microsurgery* 21(4): 135-9
- Fu MR, Rinder SH, Hu SH et al (2013) Psychosocial impact of lymphedema: a systematic review of literature from 2004-2011. *Psychooncology* 22(7): 1466-84
- Gloviczki P, Fisher J, Hollier LH et al (1988) Microsurgical lymphovenous anastomosis for treatment of lymphedema: a critical review. *J Vasc Surg* 7(5): 647-52
- Greene AK (2015) Epidemiology and Morbidity of Lymphedema. In: Greene A, Slavin S, Brorson H (eds.) *Lymphedema: Presentation, Diagnosis and Treatment*. Springer, Switzerland
- Maegawa J, Yabuki Y, Tomoeda H et al (2012) Outcomes of lymphaticovenous side-to-end anastomosis in peripheral lymphedema. *J Vasc Surg* 55(3): 753-60
- National Organization for Rare Disorders (2015) Hereditary lymphedema. <https://rarediseases.org/rare-diseases/hereditary-lymphedema/> (accessed 21 January 2019)
- Olszewski WL (2013) Lymphovenous microsurgical shunts in treatment of lymphedema of lower limbs: a 45-year experience of one surgeon/one center. *Eur J Vasc Endovasc Surg* 45(3): 282-90

This article first appeared in our sister publication, *Wound International*, in the February 2019 issue. Citation: Hadiwattage S, Watawana L, Peiris SPM, Galketiya KB (2019) Impact of lymphovenous anastomosis on limb circumference in patients with lymphoedema tarda. *Wounds International* 10(1): 25-7