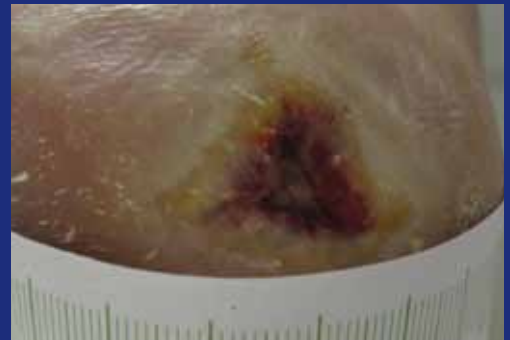
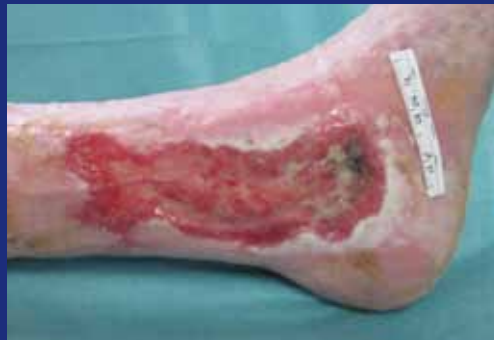
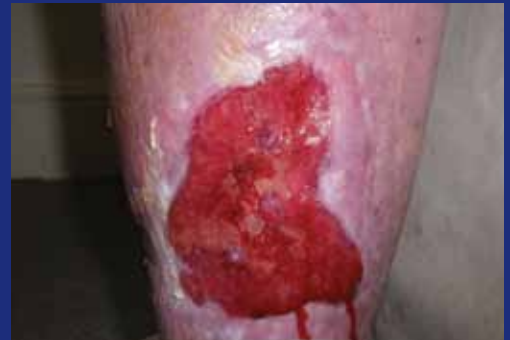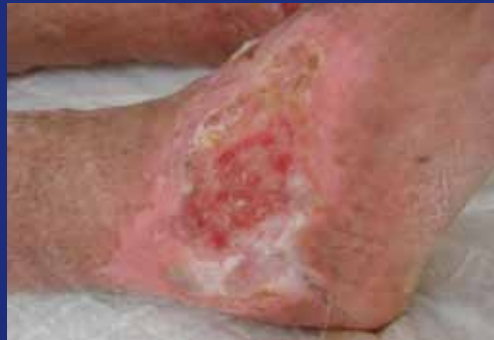INTERNATIONAL  
**CASE STUDIES**

# USING ACTISORB<sup>®</sup>: CASE STUDIES

CASE STUDIES SERIES 2012



This document has been jointly developed by Wounds International and Systagenix with financial support from Systagenix

For further information about Systagenix please visit: [www.systagenix.com](http://www.systagenix.com)



**Published by:**

Wounds International  
Enterprise House  
1-2 Hatfields  
London SE1 9PG, UK  
Tel: + 44 (0)20 7627 1510  
Fax: +44 (0)20 7627 1570  
[info@woundsinternational.com](mailto:info@woundsinternational.com)  
[www.woundsinternational.com](http://www.woundsinternational.com)



The case reports presented in this document are the work of the authors and do not necessarily reflect the opinions of Systagenix.

**How to cite this document:**

International case series: *Using ACTISORB®: Case Studies*.  
London: Wounds International, 2012.

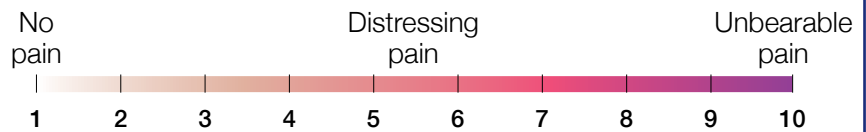**ABOUT THIS DOCUMENT**

This document contains a series of case reports describing the use of ACTISORB® (Systagenix) in patients with a range of wound types. All patients were treated for a minimum of 2-4 weeks and the decision to continue with ACTISORB® was based on continual assessment. A formal assessment was performed weekly, although in some cases dressing changes were carried out more frequently.

All patients were assessed for:

- clinical signs of infection/critical colonisation with or without odour
- signs of improvement, including odour reduction, granulation extent and reduction in wound size.

A pain assessment was carried out at the initial examination using a visual analogue scale (VAS) where 1 = no pain and 10 = unbearable pain.



Photographs were taken weekly in the majority of cases to document wound progression. Relevant additional wound treatments, eg compression therapy, antibiotic therapy, analgesia, etc, were reported.

The clinicians undertaking the study were also asked to rate the dressing (from highly satisfied to dissatisfied) and to comment on the ease of use.

The weekly assessment outcomes are cited for each case where:

- ↓ = reduction
- ↑ = increase
- = no change.

# ACTISORB®: case studies

Silver-containing antimicrobial dressings have been available for many years. ACTISORB® comprises an activated charcoal layer impregnated with silver designed to reduce infection and wound odour in patients with critically colonised or infected wounds. This document contains several case studies that describe how ACTISORB® has benefited patients with a range of wound types.

## What is ACTISORB®?

ACTISORB® is a sterile primary dressing comprising an activated charcoal cloth, impregnated with silver within a spun bonded nylon sleeve. It may be used in the treatment of most types of chronic wounds, but is particularly recommended for the management of malodorous, infected wounds (Box 1).

## How does ACTISORB® work?

When applied to a wound, the active charcoal layer absorbs bacteria and locally released toxins as well as volatile amines and fatty acids responsible for wound odour<sup>1</sup>.

The silver in ACTISORB® has been shown not to cause any detrimental effect to cell growth, while providing antimicrobial effect<sup>2</sup>. However, an in vitro study found that the bacteria and endotoxins absorbed by the activated charcoal are destroyed by the silver within the dressing, preventing them from returning to the wound<sup>3</sup>. Laboratory testing has indicated that the dressing is effective against many common wound pathogens, including meticillin-resistant *Staphylococcus aureus* (MRSA)<sup>4,5</sup>.

The perforated outer nylon sleeve of the dressing allows exudate to flow freely through to a secondary dressing, while facilitating dressing removal by minimising adherence to the wound.

## Evidence for ACTISORB®

ACTISORB® has been evaluated in a number of laboratory and clinical studies and has been shown to have:

- good antimicrobial activity
- good bacterial endotoxin binding for odour control
- good dressing tolerability
- suitability for a wide range of wounds<sup>1,3,5-8</sup>.

The performance of ACTISORB® was also evaluated in two separate randomised controlled trials in patients with chronic venous leg ulcers and pressure ulcers<sup>1</sup>. The study showed that there were differences at week 1 in both studies, with a greater reduction in wound area in the treatment group compared with the control dressing. There was also good dressing tolerability with fewer dressing-related adverse events in the ACTISORB® groups<sup>1</sup>.

Evidence from non-controlled studies, large population surveys and case studies also support the clinical benefit of using ACTISORB® in various clinical situations<sup>9,10</sup>.

### BOX 1: INDICATIONS FOR ACTISORB®

For the management of *fungating carcinomas, ulcerative, traumatic and surgical wounds* where bacterial contamination, infection or odour occurs

### BOX 2: PRECAUTIONS AND CONTRAINDICATIONS TO THE USE OF ACTISORB®

- Do not use on patients with a known sensitivity to nylon
- Use with care as a primary dressing on wounds that have a tendency to dry out ([www.dressings.org/Dressings/actisorb-silver.html](http://www.dressings.org/Dressings/actisorb-silver.html))

**Tips on using ACTISORB®**

- Prior to application, prepare the wound bed according to local policies
- DO NOT cut the dressing, otherwise particles of activated carbon may get into the wound and cause discoloration
- Where absorption is required, cover the dressing with an appropriate secondary dressing, dependent on the level of exudate and condition of surrounding skin
- The dressing can remain in situ for up to seven days, dependent on the level of exudate. The secondary absorbent dressing should be changed when its absorbent capacity has been reached
- Consider using a tacky contact layer (eg ADAPTIC TOUCH®) to help positioning of the dressing, as well as provide a non-adherent layer if required
- Consider using ACTISORB® as a 'step down' from a more aggressive silver-releasing therapy where appropriate

**ABOUT ACTISORB®**

- For further information about ACTISORB® please go to: <http://www.systagenix.com/our-products/lets-protect/actisorb-dressings-48>

**INTERNATIONAL CONSENSUS APPROPRIATE USE OF SILVER DRESSINGS IN WOUNDS**

- To download a copy of the consensus document please go to: <http://www.woundsinternational.com>

**Appropriate use of silver dressings**

A recent consensus on the appropriate use of silver dressings described the main roles of silver dressings, such as ACTISORB®, in the management of wounds to be the reduction of bioburden and to act as an antimicrobial barrier<sup>11</sup>.

Whenever ACTISORB® is used to control odour in wounds with increased bioburden or to prevent infection, the rationale should be fully documented in the patient's health records and a schedule for review should be specified.

*Reducing bioburden*

The consensus document recommends that silver dressings be used initially for a two week 'challenge' period. At the end of the two weeks, the wound, the patient and the management approach should be re-evaluated<sup>11</sup>.

If after two weeks the wound has:

- improved, but there are continuing signs of infection, it may be clinically justifiable to continue use of silver dressings with regular review
- improved and there are no longer signs or symptoms of infection, the silver dressing should be discontinued
- not improved, the silver dressing should be discontinued and the patient reviewed, and a dressing containing a different antimicrobial agent initiated, with or without systemic antibiotics<sup>10</sup>.

*Prophylactic use*

Silver dressings, such as ACTISORB®, may be used as an antimicrobial barrier in wounds at high risk of infection or re-infection. They may also be used to prevent entry of bacteria at medical device entry/exit sites, such as around percutaneous gastrostomy tubes (see *the consensus document for further information*<sup>11</sup>).

**References**

1. Kerihuel JC. Effect of activated charcoal dressings on healing outcomes in chronic wounds. *J Wound Care* 2010; 19(5): 208-215.
2. Nisbet L, et al. The beneficial effects of a non-releasing silver containing wound dressings on fibroblast proliferation. Poster presented at Wounds UK, 2011
3. Verdu Soriano J, Rueda Lopez J et al. Effects of an activated charcoal silver dressing on chronic wounds with no clinical signs of infection. *J Wound Care* 2004; 13: 10, 419-23.
4. Furr JR, Russell AD, Turner TD, Andrews A. Antibacterial activity of Actisorb Plus, Actisorb and silver nitrate. *J Hosp Infect* 1994; 27: 201-8.
5. Jackson L. Use of a charcoal dressing with silver on an MRSA infected wound. *Br J Community Nurs* 2001; 6(12) Suppl 2: 19-26.
6. Stadler, R., Wallenfang, K. Survey of 12444 patients with chronic wounds treated with charcoal dressing (Actisorb). *Aktuelle Dermatologie* 2002, 28(10): 351-54.
7. Nisbet L, Greenhalgh D, Cullen B et al. The benefits of charcoal cloth with silver on odour control and bacterial endotoxin binding. Systagenix data on file, 2011.
8. Nisbet L, Turton K, Cullen B, Foster S. The beneficial effects of a non-releasing silver containing wound dressings on fibroblast proliferation. Systagenix data on file, 2011.
9. Kerihuel JC, Dujardin-Detrez S. Actisorb Plus 25, a review of its clinical experience based on more than 12,000 various wounds. *JPC* 2003; 8(39): 3-7.
10. White RJ. A charcoal dressing with silver in wound infection: clinical evidence. *Br J Community Nurs* 2001; 6: 12 (Suppl): 4-11.
11. International consensus. *Appropriate use of silver dressings in wounds*. An expert working group consensus. London: Wounds International, 2012.

# Case 1

## Background

Mr N was a 52-year-old man who had multiple non-healing chronic wounds due to venous insufficiency. The patient was a smoker.

The patient presented to the clinic with a venous leg ulcer, which had recurred at a previously healed site on the right leg. The wound had been present for five years. Advanced wound dressings and inelastic 2-layer compression bandaging had been used to treat the wound.

## Treatment

The ulcer measured 8.6cm x 3.5cm on presentation and was critically colonised with odour, which had been a problem for the past month. The patient reported a pain score of 6 on a VAS of 1-10. It was decided to treat the wound with ACTISORB® dressing to control the odour and bacterial burden.

**Week 1:** After a week of treatment, there was no change in the appearance or size of the wound, although the odour had reduced. Granulation levels were between 0-25% and the exudate level was high. There was no erythema but there was fibrin present in the wound bed.

The clinician assessing the wound was satisfied with the dressing and reported that it was very easy to use. It was decided to continue using ACTISORB® together with 2-layer inelastic compression.

**Week 2:** The wound showed signs of improvement with 50-75% granulation tissue and exudate levels had reduced. The periwound skin also seemed improved. The wound size remained static at 8.6cm x 3.4cm. It was decided to continue with the treatment regimen.

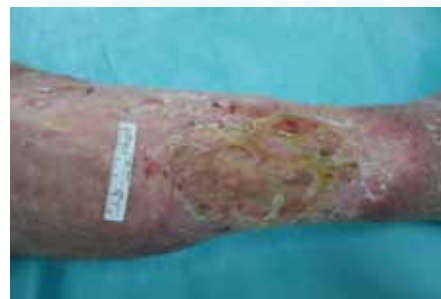**Week 3:** Signs of infection were further reduced. Granulation was good at 50-75% coverage. Odour was reduced and the wound had decreased in size to 7.4cm x 3.5cm. It was decided to continue with ACTISORB® and 2-layer compression. The wound was also cleansed with a saline solution.

**Week 4:** There was good granulation at 25-50% and there were no signs of infection. Odour was reduced. There was no change in size from week 3 and the wound remained static at 7.4cm x 3.5cm. It was decided to continue with the treatment regimen.

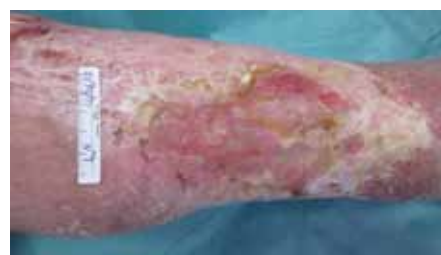## Outcome

ACTISORB® was found to be easy to use, with clinicians reporting a high level of satisfaction overall. A reduction in exudate indicated that the wound bed bioburden had diminished. Granulation tissue had increased and there was a reduction in wound size. Most importantly, from the patient's perspective, the wound odour was reduced.

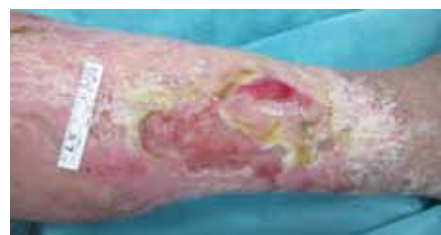*By: Professor Marco Romanelli, Consultant Dermatologist, University of Pisa, Italy*



Baseline



Week 1



Week 4

Figures 1-3: The size of the ulcer reduced over the four-week case study period. A decrease in odour and exudate was observed.

Assessment	Week 1	Week 2	Week 3	Week 4
Signs and symptoms of infection	n/a	—	↓	↓
Malodour	↓	↓	↓	↓
Wound size	—	—	↓	—

# Case 2

## Background

Mr B was a 64-year-old man with insulin-dependent type 2 diabetes, diabetic retinopathy, arterial hypertension, hypercholesterolaemia and a history of ulceration. He was on various medications to control his blood pressure and diabetes.

## Treatment

The patient presented to the clinic with a diabetic foot ulcer that had appeared spontaneously. It was 0.8 cm<sup>2</sup> prior to debridement of the wound and was located on the head of the fourth metatarsal of the left foot. It had been present for 15 months, was foul smelling and showed signs of critical colonisation, but it was not causing the patient any pain. It was decided to treat the wound with ACTISORB® to control the wound odour and manage the bacterial bioburden. Felt padding was used to relieve pressure and he was receiving oral antibiotics based on microbiology results.

**Week 1:** After one week the wound was still foul smelling and although the wound had not greatly reduced in size the signs of infection were reduced. There was serous exudate and bleeding at the top of the wound with granulation at the base (50-75%). The edges of the wound were macerated. The wound now measured 0.7cm<sup>2</sup>. The nurse was satisfied with the dressing and the regimen was continued for a further week. The 15mm felt padding and oral antibiotics were also continued.

**Week 2:** The wound showed a further reduction in the signs of infection. The base of the wound was granulated (50-75%) but there was copious amounts of serosanguinous exudate. The wound edges were fibrotic and macerated. There had been no significant change to the size of the wound (0.7cm<sup>2</sup>). The nurse was satisfied with the treatment and the regimen was continued.

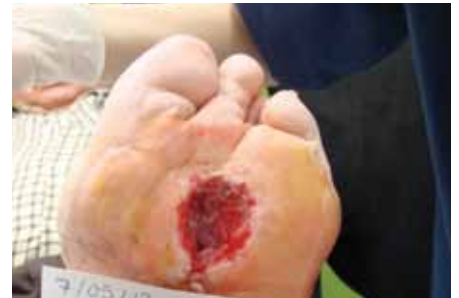**Week 3:** There was a slight increase in wound size (0.8cm<sup>2</sup>). The base of the wound was granulated (50-75%) and the edges continued to be fibrotic and macerated. There was a lot of serosanguineous exudate. The wound was foul smelling and the wound appeared critically colonised. It was decided to continue the regimen with the addition of 20mm felt padding and shoes with heels at the back. Oral antibiotics were also continued.

**Week 4:** The wound was foul smelling, the base was granulated and there was copious amounts of serous exudate. There was a reduction in the maceration of the edges of the wound and the wound now measured 0.7cm<sup>2</sup>.

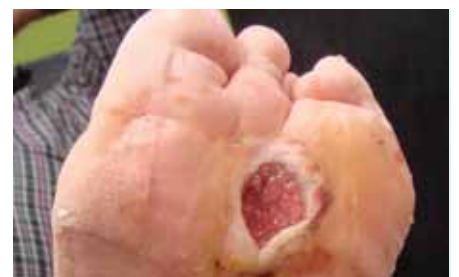## Outcome

In patients with chronic wounds, many factors impact on wound healing. Mr B had a number of co-morbidities and the wound bed characteristics made this a difficult to heal ulcer. It was decided to continue with the treatment regimen as there were no adverse effects and there was overall satisfaction with the dressing.

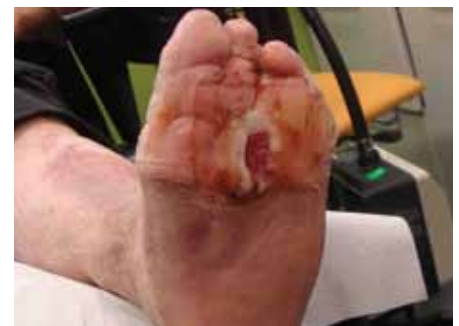*By: Esther García Morales, Podiatrist, Diabetic Foot Unit, University Clinic of Podiatry, The Complutense University of Madrid, Madrid, Spain*



Baseline



Week 2



Week 4

Figures 1-3: Over the course of the four-week study period, the wound size fluctuated by 0.1 cm and was considered to have remained static. There was copious exudate and odour remained unchanged.

Assessment	Week 1	Week 2	Week 3	Week 4
Signs and symptoms of infection	↓	↓	—	—
Malodour	—	—	—	—
Wound size	—	—	—	—

## Case 3

### Background

Mr V was a 56-year-old man with a post surgical wound on the third toe space of his left foot following amputation of the toe in April 2012. He was an insulin dependent diabetic and gave a history of referral to primary care services as an emergency due to worsening of a neuropathic lesion on the toe. His peripheral circulation was assessed and results were satisfactory. He had undergone amputation of the fourth toe in December 2011, which healed without complication.

### Treatment

The wound in the third toe space of the left foot measured 2cm x 3cm with a depth of 2cm. The wound bed had approximately 50% granulation and 50% sloughy tissue. The wound was malodorous and appeared to be infected. He was receiving daily oral antibiotic therapy (ciprofloxacin) as the infection was thought to have been due to osteomyelitis. The wound had previously been treated with flomazine and gauze swabs. The dressing regimen was changed to ACTISORB® as a primary dressing with TIELLE® XTRA as a secondary dressing. Pain assessment indicated a score of 6.5 on a 1-10 VAS, indicating there was severe pain.

**Week 1:** Mr V returned to the clinic for review during the first week of treatment. There was a reduction in the symptoms of infection. The wound size was 2cm x 4cm x 1cm. Odour was still present, but had reduced. The tissue at the wound base was friable and pale and there were moderate levels of haemoserous exudate. There was also slight maceration of the periwound skin. Wound swabbing produced a negative culture, but antibiotic therapy was continued due to suspected residual osteomyelitis.

**Week 2:** The wound had continued to improve and odour was not present. Exudate levels had decreased and the wound bed comprised 50-75% granulation tissue. The wound measured 2cm x 3cm x 1cm and the periwound skin was less macerated. Sloughy tissue had reduced, revealing that the wound extended to bone. Antibiotic therapy was continued. The dressing regimen was changed to PROMOGRAN PRISMA® because of its proven efficacy over moist wound healing environments in randomised clinical trials, and ease of application. The wound was also thought to be at risk of infection despite negative wound swabs.

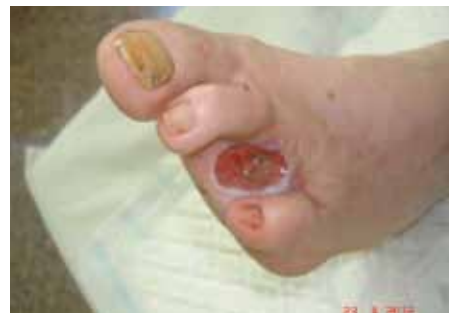**Week 3:** At this visit, bone was still visible but there was an increase in granulation tissue (50-75%). There was no odour and the wound measured 2cm x 2cm x 1cm. There was a slight increase in exudate levels and some evidence of maceration of the periwound skin. Treatment with PROMOGRAN PRISMA® was continued.

**Week 4:** On the final visit, although the depth of the wound remained unchanged, although it had decreased considerably in size (1cm x 1cm x 1cm). The wound base had more than 75% granulation tissue. Due to exposed bone and suspected residual osteomyelitis, it was decided to change the topical treatment to Collatamp G, a local antibiotic that delivers gentamicin directly to target tissue.

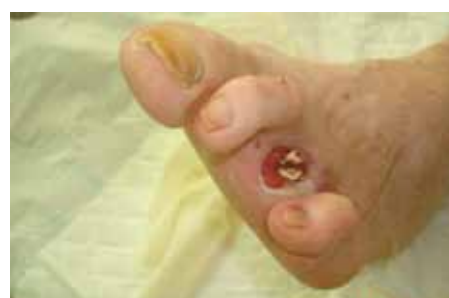### Outcome

Both ACTISORB® and PROMOGRAN PRISMA® were found to be easy to use with clinicians reporting a high level of satisfaction with both dressings. In this complex wound, odour was reduced by week 1 and eliminated by week 2. Importantly the improvement in the wound bed may have allowed better penetration of topical treatment for osteomyelitis.

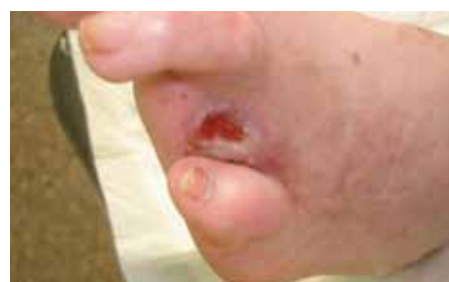By: Carmen Alba Moratilla, Nurse Consultant, Hospital Clinico de Valencia, Spain



Week 1



Week 2



Week 4

Figures 1-3: The wound reduced in size over the study period. There was an increase in granulation tissue, the malodour was eliminated and the symptoms of infection reduced.

Assessment	Week 1	Week 2	Week 3	Week 4
Signs and symptoms of infection	↓	↓	↓	None
Malodour	↓	None	None	None
Wound size	—	↓	↓	↓

# Case 4

## Background

Mrs S was a 53-year-old woman who had a history of chronic obstructive pulmonary disease. She was a heavy smoker and had hypertension and venous insufficiency. In April of 2012 she presented at clinic with a venous leg ulcer, which she had sustained following minor trauma at home. The ulcer had been present for 12 years. Over this period of time the wound had been treated with many different advanced wound dressings and compression therapy.

## Treatment

The wound was located on the right lower leg and measured 52.3cm<sup>2</sup>. On clinical examination the wound appeared to be colonised with odour present. The wound base was composed of granulation tissue with a fine layer of fibrin/slough. There was some maceration to the surrounding skin of the lower part of the wound. The odour had been present for 14 days and Mrs S reported high levels of pain with a score of 7 on a VAS of 1-10. The wound was dressed with ACTISORB®. An inelastic multilayer compression bandage system was applied from toe to knee.

**Week 1:** The wound was reassessed 10 days later. Although the wound had not decreased in size, there was improvement in the wound bed and exudate levels had decreased. Wound odour had also started to reduce. The wound bed was composed of 50-75% granulation tissue. Topical treatment with ACTISORB® was continued with an inelastic multilayer compression bandage system applied toe to knee.

**Week 2:** On examination, the wound bed was stable and there was a reduction in the wound size (45cm<sup>2</sup>). Odour had also reduced and the wound bed was composed of 50-75% granulation tissue.

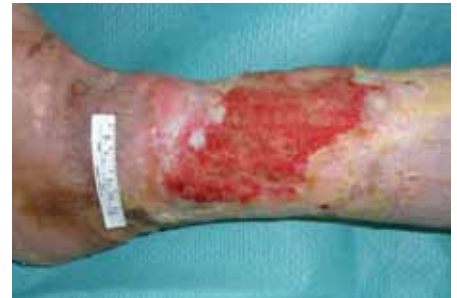**Week 3:** The wound had continued to improve with evidence of good granulation tissue and no signs of infection. The wound had again reduced in size (41 cm<sup>2</sup>) and odour was minimal. Treatment with ACTISORB® was continued with an inelastic multilayer compression bandage system applied toe to knee.

**Week 4:** On the final visit, the wound bed had continued to improve, odour was reduced and there were positive signs of healing. The wound had decreased in size and measured 39 cm<sup>2</sup>. The periwound skin had improved significantly with no evidence of maceration.

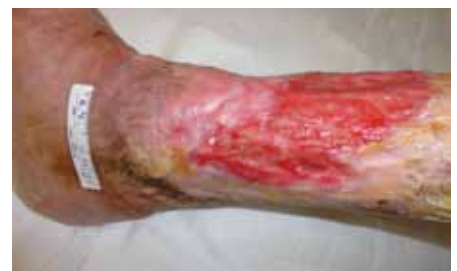## Outcome

During the course of treatment, the clinical staff rated the dressing as satisfactory or highly satisfactory in terms of ease of use. Chronic wounds that have been present for many years present great challenges to clinical staff. In the case of Mrs S good wound care, along with appropriate compression, lead to great improvement in the wound. Additionally, when healing occurs, wound odour usually reduces; this is of great importance to patients and can significantly improve their quality of life.

*By: Professor Marco Romanelli, Consultant Dermatologist, University of Pisa, Italy*



Baseline



Week 3

Figures 1-2: Odour and wound size reduced consistently over the four-week study period.

Assessment	Week 1	Weeks 2	Week 3	Week 4
Signs and symptoms of infection	↓	—	↓	↓
Malodour	↓	↓	↓	↓
Wound size	—	↓	↓	↓



# Case 5

## Background

Mr G was a 48-year-old man with a history of chronic venous disease and recurrent cellulitis. His occupation in an industrial setting necessitated long periods of standing and this along with his high body mass index (BMI) may have contributed to the development of a chronic venous leg ulcer on his right lower leg in the posterior gaiter region.

The ulcer had been present for 12 months, despite various treatments including Eclypse™ (Advancis Medical), Acticoat Flex 7™ (Smith and Nephew) and Aquacel Ag™ (ConvaTec). All dressings had been used in combination with Coban 2™ (3M) compression bandaging. In addition to local management, Mr G had been prescribed several courses of antibiotics and was on a maintenance dose when first seen in the wound healing clinic in late April.

## Treatment

On examination the ulcer was assessed as critically colonised although not overtly infected. There was a 3-week history of malodour and exudate levels were moderate. The ulcer bed indicated patchy granulation and the wound margins were macerated. Mr G reported a fairly low level of pain at 2 on a VAS of 1-10. ACTISORB® was applied to manage the wound bioburden and reduce the odour. The dressing was secured with toe to knee compression bandaging (Coban™ 2, 3M).

**Week 1:** On reassessment, there was an overall improvement with fewer signs of infection, less slough and reduced wound odour. Granulation tissue was evident across 50-75% of the wound bed. The wound measured approximately 7cm x 10cm in length. ACTISORB® was continued for a further week.

**Week 2:** The ulcer showed further signs of improvement with odour continuing to diminish, although some bleeding to the upper aspect of the ulcer was noted on dressing removal. The wound margins were much healthier with maceration mostly cleared. The overall wound size remained static. Treatment was continued.

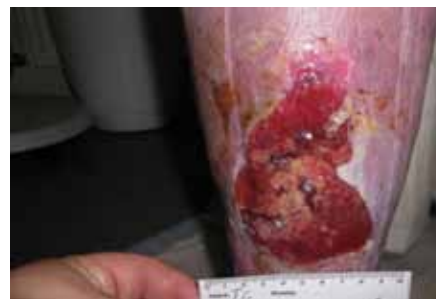**Week 3:** After the third week of treatment with ACTISORB® dressing the ulcer size remained unchanged at approximately 7cm x 10cm. However, the appearance of the wound bed was much improved with an overall pinkish, moist granular tissue in evidence across 100% of the wound surface. Again a small amount of fresh bleeding was noted although the dressing was atraumatic on removal. The malodour had cleared and there were no signs of infection.

**Week 4:** The wound bed remained healthy in appearance, the ulcer margins were intact with signs of epithelialisation and there were no overt signs of infection. However, some bleeding was still noted at dressing change.

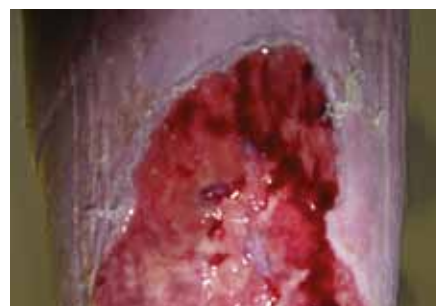
## Outcome

Overall, the dressing when used in conjunction with light compression appeared to have cleaned the wound bed of an excess bioburden and dissipated the associated symptoms of infection. Notably, the malodour had disappeared and the exudate had reduced, both important factors from the patient's perspective. The clinical staff found the dressing easy to apply and it was atraumatic on removal, although some bleeding was apparent, the reason for which was not clear.

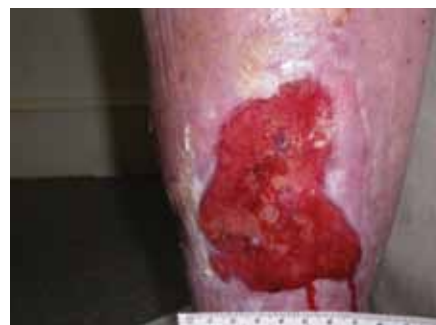By: *Richie Skinner, Tissue Viability Podiatrist, Eastbourne Wound Healing Centre, Eastbourne, Sussex*



Baseline



Week 2



Week 3

Figures 1-3: The wound did not reduce in size over the four weeks, but signs of infection and malodour were eliminated. The wound margins improved but some bleeding occurred at dressing changes.

Assessment	Week 1	Weeks 2	Week 3	Week 4
Signs and symptoms of infection	↓	↓	—	Gone
Malodour	↓	↓	↓	Gone
Wound reduction	↓	—	—	—

# Case 6

## Background

Mrs B was a 78-year old woman who had varicose veins that had been operated on three times. An echocardiogram a month previously had shown that both saphenous veins were incompetent and perforating. Her ankle brachial index was 1.1 in the right leg and 1 in the left leg.

In April 2012, she presented with two venous leg ulcers, one on each leg — one for approximately 48 years and the other for six years. She had been seen by many different specialists and was now resigned to having 'an ulcer for life'. The wounds were measured using planimetry and the right leg wound was 26.75cm<sup>2</sup> and the left was 5.25cm<sup>2</sup>. Both malleolar areas were covered by the wound and this was affecting flexion.

## Treatment

The wounds were thought to be infected, although cultures taken were negative and the patient was on a maintenance dose of antibiotics. The wounds had been foul smelling for the past 48 hours. The patient was not in severe pain but reported mild irritation. It was decided to treat the wounds with ACTISORB® to manage the odour and signs of infection.

**Week 1:** Follow-up was not possible.

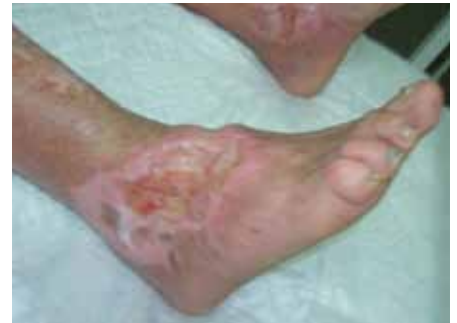**Week 2:** After a week of treatment there was an improvement in the wound. There was increased granulation tissue in the wound bed (0–25%) and a reduction in the exudate level. The foul smell had reduced and the wound had decreased in size. The clinician was very satisfied with the use of the dressing although it was reported that folding the dressings to fit the size of the wound was unsatisfactory. It was decided to continue the regimen but the clinician was concerned about the lack of antibiotic coverage (the patient was no longer taking antibiotics) and reduced therapeutic compression. The patient was advised to walk for an hour in the morning and evening to improve calf muscle function.

**Week 3:** On examination, there was a further reduction in the signs of infection. There was no erythema, although there were signs of periwound maceration due to exudate. The ulcers had decreased in size and the swelling in both legs had decreased. The right leg wound now measured 6cm<sup>2</sup> and the left leg was 1cm<sup>2</sup>. The smell had reduced and granulation tissue had increased to 25– 50% of the wound.

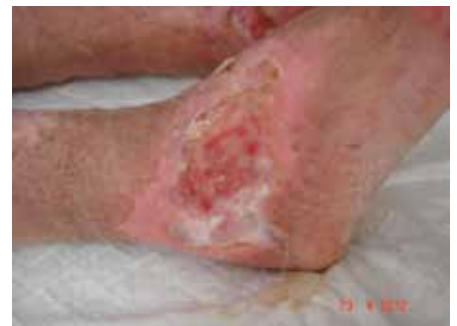## Outcome

With the signs of infection reduced and a reduction in the foul smell, it was decided to switch the patient to PROMOGRAN PRISMA® to help promote granulation in the base of the wound, while maintaining bacterial control. The patient continued to apply inelastic compression bandages and had increased her walks, helping to improve the circulation in her legs.

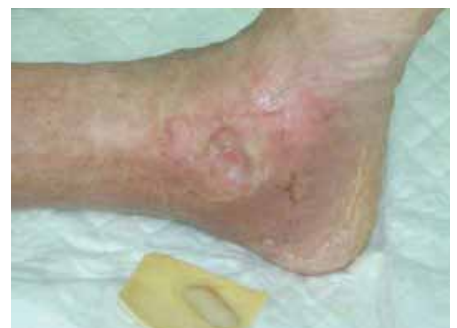*By: Carmen Alba Moratilla, Nurse Consultant, Hospital Clinico de Valencia, Spain*



Baseline



Week 1



Week 2

Figures 1-3: Over the two weeks before the treatment was discontinued the wounds improved: odour and infection were reduced, the wounds shrank and swelling in both legs subsided.

Assessment	Week 1	Week 2	Week 3	Week 4
Signs and symptoms of infection		↓	↓	
Malodour		↓	↓	
Wound size		↓	↓	

# Case 7

## Background

Mrs E was a 75-year-old woman who had a history of chronic venous ulceration due to venous insufficiency. She found it difficult to be concordant with compression therapy and had had variable success with wound healing.

In April 2012 she presented at clinic with a venous leg ulcer, which had occurred after a minor trauma. The ulcer had been present since 2006. Over this period of time it had been treated with a range of advanced wound dressings. The patient had recently had a skin graft applied to the wound with poor results.

## Treatment

The wound was located on the left lower leg and measured 61cm<sup>2</sup>. On examination the wound was malodorous. The wound base was composed of 50-75% thick sloughy tissue. There was a large area of maceration to the periwound skin at the lower edge of the wound extending to the foot. Mrs E reported high levels of pain with a score of 8 on a VAS of 1-10. The wound was dressed with ACTISORB®, which was selected for its absorbency and because the wound was in an inflammatory state.

**Week 1:** Although the wound had not decreased in size, there was a good response to treatment with a reduction in exudate levels and improvement in granulation tissue (50-75% granulation). Wound odour had also decreased. Topical treatment with ACTISORB® was applied for a further week and Mrs E agreed to have to have a 2-layer inelastic compression bandage system applied toe to knee.

**Week 2:** On examination in the clinic, the wound had increased in size (69.5cm<sup>2</sup>) with an increase in sloughy tissue, higher levels of exudate and maceration to the surrounding skin. It was decided to continue with the current treatment regimen due to satisfaction with the dressing and to closely observe the wound.

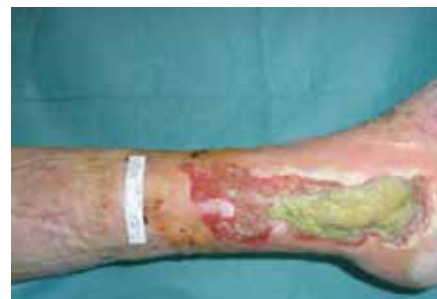**Week 3:** On return to the clinic, Mrs E's wound was showing signs of improvement; the edges of the wound were healthy, exudate levels had reduced and the wound bed had moderate signs of improvement (25-50% granulation tissue). The wound had also decreased in size (63cm<sup>2</sup>) and odour was minimal. Treatment with ACTISORB® was continued with a 2 layer inelastic compression bandage system applied toe to knee.

**Week 4:** The wound bed continued to improve, the wound edges were epithelialising, odour was minimal and the wound had decreased in size (61cm<sup>2</sup>).

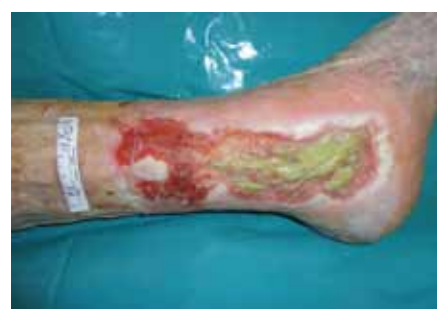## Outcome

During the course of treatment, the clinical staff rated the dressing as satisfactory or highly satisfactory in terms of ease of use. Despite the initial increase in wound size, it was decided to continue with the treatment regime and wound improvement was established.

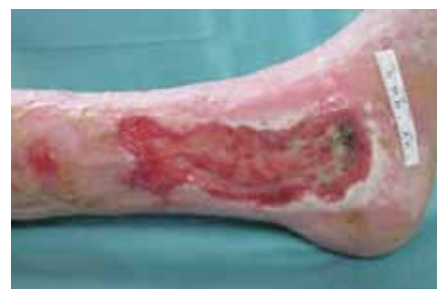*By: Professor Marco Romanelli, Consultant Dermatologist, University of Pisa, Italy*



Baseline



Week 2



Week 4

Figures 1-3: Over the study period, the wound showed signs of improvement and decreased in size.

Assessment	Week 1	Week 2	Week 3	Week 4
Signs and symptoms of infection	—	—	↓	n/a
Malodour	↓	↓	↓	↓
Wound size	—	↑	—	↓

## Case 8

### Background

Mr G was a 42-year-old man who had insulin-dependent type 2 diabetes and neuropathy. He presented with two infected diabetic foot ulcers with heel fissures on the left foot.

### Treatment

On clinical examination one wound measured 15mm x 20mm and the other was 15mm x 20mm x 4mm. The ulcers had been present for five weeks and had been treated with Allevyn™ (Smith & Nephew) and a softcast heel. The patient had been taking antibiotics (co-amoxiclav) for four weeks to treat infection of the left heel. It was thought that the ulcers had been infected and malodorous for the past week. The patient was in some pain, rating it as 4 on a VAS of 1-10. It was decided to treat the wound with ACTISORB® to manage the odour and bacterial burden.

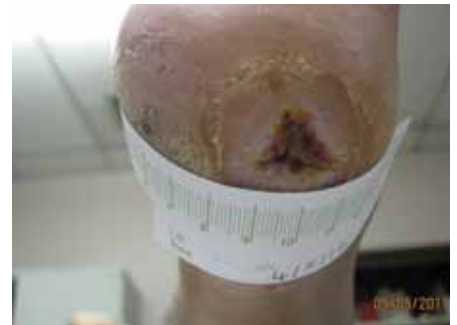**Week 1:** After one week of treatment the signs of infection had reduced. There was less erythema, less exudate and much less odour. There was 25-50% granulation tissue. The wounds had not reduced in size, but the clinician was highly satisfied with the progress and it was decided to continue with the dressing regimen as well as the softcast heel.

**Week 2:** After two weeks the signs of infection had again reduced. There was some maceration, but this may have been because the patient had left the dressing off. The malodour had been completely eliminated and there were signs of healing. Granulation tissue was 25-50% and the wounds had reduced in size. One wound was now 5mm x 4mm (wound 1) and the second was 15mm x 14mm x 4mm (wound 2). The patient had completed the course of antibiotics and the signs of infection had been eliminated. It was therefore decided to switch to PROMOGRAN PRISMA® for wound 2. The smaller wound had healed by the following week.

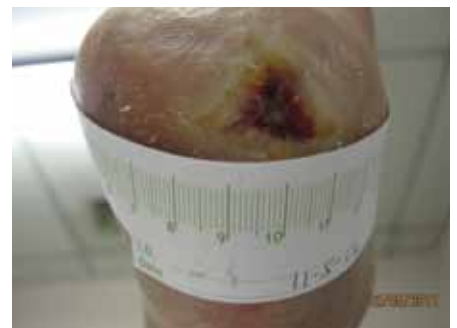
### Outcome

ACTISORB® was found to be easy to use with a high level of satisfaction reported overall. A reduction in erythema, exudate and odour at week 1 indicated that the wound bioburden had diminished. There was complete elimination of the odour at week 2 and both wounds had reduced in size. Treatment was switched to PROMOGRAN PRISMA®.

*By: Paul Chadwick, Principal Podiatrist, Salford Royal (NHS) Foundation, Salford, UK*



Week 1



Week 2

Figures 1-3: Signs of infection and malodour decreased over the two-week period in which Actisorb® was used. Infection was eliminated by week 2.

Assessment	Week 1	Week 2	Week 3	Week 4
Signs and symptoms of infection	↓	↓		
Malodour	↓	Gone		
Wound size	—	↓		





A Wounds International publication  
[www.woundsinternational.com](http://www.woundsinternational.com)