

## Ten top tips: improving outcomes from flap reconstruction



Author:  
Joyce Black, Steven Black

**P**ressure ulcers are estimated to be present in more than one-third of patients with spinal cord injury (McKinley et al, 1999). Flap reconstruction of a pressure injury is aimed at improvement of patient hygiene and appearance, prevention or resolution of osteomyelitis and sepsis, reduction of fluid and protein loss through the wound, and prevention of future malignancy (Marjolin ulcer). In general, stage 3 and 4 pressure injuries tend to require flap reconstruction. The rate of recurrence after flap surgery over past 50 years has ranged between 3% and 82%, with no trend toward improvement. Wound dehiscence is the most common surgical complication following flap reconstruction, with recurrence rates as high as 80% in some series. In a retrospective chart review of 276 patients with flaps, the predictors for pressure ulcer recurrence on the ischium were low body weight and active smoking. Wound infection was seen in patients with diabetes and osteomyelitis (Bamba et al, 2017). This paper is focused on how to improve outcomes in patients with pressure injury/ulcer who require reconstruction with a flap.

**1 Optimise the patient's medical status prior to surgery:** Obtain a clear assessment of the patient's nutritional status. Use a calorie count if needed as an individual's recollection of dietary intake may not be accurate. Albumin and prealbumin are not predictive of nutritional status because they are lower when inflammation is present. Supplement protein intake prior to surgery if needed. Goals of nutritional support should include adequate protein intake and the establishment of a positive nitrogen balance, with 1.0-2.0 g/kg/day being recommended for patients with pressure injuries (National Pressure Ulcer Advisory Panel [NPUAP], 2014).

Work with the patient to stop smoking and/or using other nicotine products as tobacco and cigarettes contain carbon monoxide and nicotinic acid. These products are potent vasoconstrictors that increase blood viscosity. Do not substitute nicotine patches for smoking; nicotine is the same in these patches.

Consider undiagnosed obstructive airway disease (sleep apnea). If the patient is obese or

has a wide neck, consider having the patient evaluated for sleep apnea before surgery. Lengthy anaesthetics and immobility can impair clearance of secretions and suppress respiratory drive.

Control spasticity with medications such as diazepam, baclofen, or dantrolene sodium. Patients with spasticity refractory to medication may be candidates for neurosurgical ablation.

Control blood glucose levels below 200 mg/dl. The patient may need to use injectable insulin during periods of stress, which often occur with surgery.

Evaluate for the presence of urinary tract infection. Obtain a urinalysis before any surgery and culture the urine if suspicious for infection.

If faecal contamination has been a problem for the patient while the wound was open, diverting colostomy may need to be considered. If needed, this operation precedes any flap reconstruction.

**2 Rule out osteomyelitis:** Clinical signs of osteomyelitis can be nonspecific and difficult to recognise. They include an open wound with exposed bone, persistent sinus tract, or tissue necrosis overlying bone. Other symptoms can include chronic pain, malaise and sometimes fever. Positive microbial culture from bone biopsy and histopathology consistent with necrosis are the preferred diagnostic criteria for osteomyelitis. Magnetic resonance imaging (MRI) provides better information for early detection of osteomyelitis than other imaging modalities. MRI can detect osteomyelitis within 3 to 5 days of disease onset (Pineda, 2009). Plain radiography usually does not show abnormalities caused by osteomyelitis until about 2 weeks after the initial infection, when nearly 50% of the bone mineral content has been lost.

**3 Be certain the patient is aware of the postoperative restrictions on activity and that he/she is willing to adhere to the postoperative plan of care:** Before the patient is a candidate for flap surgery, the patient must understand all of the postoperative requirements and restrictions, and be willing to cooperate during the recovery. If the patient is unwilling or unable, the patient

**Authors:**

*Joyce Black is Professor in the College of Nursing with the University of Nebraska Medical Center in Omaha Nebraska. She has been active with the National Pressure Ulcer Advisory Panel; Steven Black is Plastic Surgeon and Medical Director of the Center for Wound Healing with Nebraska Medicine in Omaha, Nebraska*

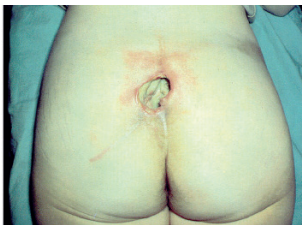

Figure 1. Stage 4 pressure ulcer on the sacrum.

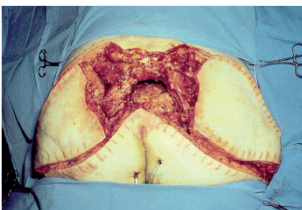


Figure 2. Elevation of flaps following excision of the ulcer.

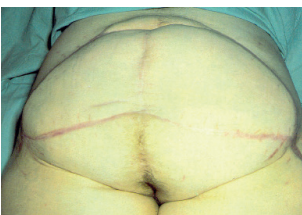

Figure 3. Healed surgical wound.

is not a candidate for the flap procedure. Flap reconstruction requires that the patient remains in bed until the flap is healed and can tolerate pressure (see details below). The patient must be taught to avoid or modify the activity that caused the pressure ulcer in the first place — frequently this involves a lifestyle change the patient must be willing to make or the ulcer will recur. There are a finite number of flaps, so it is important that each flap be used with caution.

**4 Plan how the patient will be managed during surgery:** The position of the patient during surgery depends on the location of the ulcer and the planned reconstruction. Many pressure ulcers occur in the gluteal region and require prone positioning during surgery. The anterior surfaces of the body should be well padded during the operation; additional dressings may be needed to add protection. Most anesthesiologists choose to use general endotracheal anesthesia, particularly if the patient is prone, but ulcer closure may be performed under regional or local anesthesia if necessary. Significant blood loss is possible; accordingly, two units of type-specific packed red blood cells should be available during the operation. Arrangements should be made to have a pressure-reducing mattress available in the operating room and for the postoperative period to reduce the risk of immediate recurrence or dehiscence.

**5 Plan the technique to be used to close the ulcer:** Surgical options are discussed and planned prior to surgery. The patient is informed of the plan and the potential complications in order to provide consent for surgery. Very few pressure injuries can or should be closed primarily after debridement, given the unacceptably high complication rates. The goals of surgical reconstruction are to eliminate dead space in the wound, enhance perfusion, decrease tension on the closure, and provide a new source of padding over the bony prominence. Usually, large flaps in the pelvic area are designed so they can be re-rotated if complications or recurrence arise. Flaps must be designed so as not to impair options for other flaps in the future due to the high recurrence rates (Chiu et al, 2017). Well-vascularised tissue should be placed in the wound, usually a musculocutaneous or fasciocutaneous flap is transposed or rotated on a pedicle containing its own blood supply. Myocutaneous (musculocutaneous) flaps are

usually the best choice for patients with spinal cord injuries (SCIs) and for those in whom a loss of that muscle function does not contribute to a comorbidity. Myocutaneous flaps can help heal osteomyelitis and limit the damage caused by shearing, friction, and pressure because they provide vascularised muscle, subcutaneous fat and skin. Closure of the wound may also be done with a free flap with microvascular anastomosis. Free flaps are muscle-type flaps in which the vein and artery are disconnected at the donor site and subsequently reconnected to the vessels at the recipient site with the aid of a microscope. This is the most complex method of wound closure and would usually be considered only after all other options for reconstruction have been exhausted.

**6 Excise the ulcer and debride surrounding tissue:** With adequate anaesthesia, the ulcer is fully excised, including the bursa, surrounding scar tissue, and any heterotopic calcification [Figure 1]. Underlying bone must be adequately debrided to ensure that there is no retained osteomyelitis. Additional debridement is aided by pulsed lavage to reduce bacterial burden. Once the wound has been appropriately debrided, it is closed using the planned method [Figures 2 and 3]. In terms of the ultimate success or failure of pressure injury reconstruction, the work conducted in the operating room is only the first step. Once a pressure injury has been successfully closed, appropriate postoperative care must be initiated to encourage wound healing and to reduce the risk of complications, such as recurrence.

**7 Eliminate shear and tension on the flap:** Good communication between the surgeon and the nurses providing postoperative care is essential for successful outcomes. From the time of transfer from the operating table directly to the high immersion speciality bed, care must be exercised to prevent shearing and tension across the flap repair. A frequent cause of flap dehiscence or failure is someone sending the patient for a procedure (e.g. X-ray, CT scan, MRI) in the early postoperative period. All effort must be undertaken either to get all tests pre-operatively or to avoid them for several weeks postoperatively. All tests involving movement of the patient should be approved by the flap surgeon in advance. Various surgeons have their regimens for each flap. In addition, when the head of the bed must be elevated due to pulmonary problems,

dress the surgical site with layered foam dressings to reduce shear (Han et al, 2017). The general considerations are extremely limited pressure and tension on the flap if any for the first 6 weeks followed by progressive sitting. It is increasingly common to use negative pressure therapy for 1–3 weeks over the intact flap closure area to splint the area to avoid shearing forces on the flap and incisions (Schmedes et al, 2012).

**8 Monitor the flap for signs of arterial and venous insufficiency setting:** Monitoring circulation of flaps postoperatively is critical to success. Changes in perfusion need to be recognised quickly to correct any treatable problems. If there is arterial insufficiency, the flap would usually look pale and lack capillary refill. Muscle flaps can be particularly difficult to judge — colour change with loss of a beefy red appearance is most common. If venous clot is the cause of flap failure, the flap generally becomes congested and bluish in color. Capillary refill is brisk. Implanted and external assessment devices are available to aid in early recognition of flap demise (Lohman et al, 2013). Sometimes, poking a flap with an 18-gauge needle (away from the pedicle site) can help judge flap circulation. If there is no bleeding, the problem is inflow. If there is rapid exit of dark red blood, venous congestion is likely the problem. Communicate with the surgeon on this problems, additional surgery or negative pressure may be required (Yu et al, 2017).

**9 Inspect the skin daily, removing all devices:** Patients with pressure injury are at high risk for developing another ulcer. Therefore, during the postoperative recovery period, intense efforts are undertaken to prevent other pressure injuries in areas away from the flap in these immobilised patients. Skin care must be performed daily. This involves careful inspection of all skin surfaces to identify areas of impending breakdown before the breakdown occurs. An often overlooked detail is to remove compression stockings at least daily to inspect the heels. Skin should be washed with soap and water and completely dried. Moisture should not be allowed to accumulate on the skin or in clothing or bedding, nor should the skin be allowed to become overly dry and scaly. Skin moisturisers are useful to maintain the appropriate level of moisture at the skin surface.

**10 Use progressive sitting to reduce shearing and ischemia in the flap:** At 2-6 weeks after surgery, the patient can begin very limited sitting, initially for only 10 minutes per day. After these sitting periods, the flap should be evaluated for discoloration and wound edge separation. Over the course of a few weeks, the sitting periods are increased in 10-minute increments until they reach 2 hours. Paraplegic patients are taught to lift themselves to relieve pressure for 10 seconds every 10 minutes.

In patients with ischial tuberosity pressure injuries, sitting may be resumed 6 weeks after a healed wound is achieved. Sitting may be gradually reintroduced over several weeks. This is a reasonable protocol for sitting on wheelchair cushion once allowed:

- First Day: Begin sitting 10 minutes three times per day. These periods of time may not be added together to form 30 minutes once a day
- Second Day: If there is no redness of the incision or flap, sitting can increase to 20 minutes three times per day
- Third Day: If there is not redness of the incision or flap, the patient may increase sitting to 30 minutes three times per day
- Fourth Day: If there is no redness of the incision or flap, the patient may increase sitting to 45 minutes three times per day
- Fifth Day: If there is no redness of the incision or flap, the patient may keep advancing the amount of sitting time until they reach 2 hours three times per day. Do not advance beyond 2 hours at a time.

Because of the extremely high pressures generated over the ischial tuberosities during sitting, wheelchair patients should lift themselves out of their seat or rock back in the chair every 15 minutes. Paraplegic patients must continue to receive upper body strengthening therapy during their period of immobility to maintain their ability to lift their body off the flap frequently when they do start sitting again.

After successful wound closure, ambulatory patients should be out of bed with assistance as soon as possible. More strenuous physical activity should be delayed for approximately 6 weeks. These recommendations regarding the resumption of activity vary according to the clinical situation and are implemented at the discretion of the treating physician.

Patients often benefit from transfer to a subacute or rehabilitation facility after wound

closure. This allows them to receive ongoing education, observation and rehabilitative therapies before returning to their usual place of residence. Rehabilitation efforts should include re-education on the need for a proper wheelchair cushion and offloading techniques.

### Conclusion

Reconstruction of pressure ulcers with flaps is a major commitment on the part of the healthcare team and the patient. In order to improve outcomes, the staff must understand how to avoid shear and pressure on the flaps and the patient must be agreeable to the progressive sitting programme.

WINT

### References

- Bamba R, Madden J, Hoffman A et al (2017) Flap reconstruction for pressure ulcers: An outcomes analysis. *Plas Reconstr Surg Glob Open* 5(1): e1187
- Chiu YJ, Liao WC, Wang TH et al (2017) A retrospective study: Multivariate logistic regression analysis of the outcomes after pressure sores reconstruction with fasciocutaneous, myocutaneous, and perforator flaps. *J Plast Reconstr Aesthet Surg* 70(8): 1038–43
- Han HH, Ko JG, Rhie JW (2017) Factors for postoperative complications following pressure ulcer operation: stepwise multiple logistic regression analysis. *Int Wound J* doi: 10.1111/iwj.12754. [Epub ahead of print]
- Lohman RF, Langevin CJ, Bozkurt M et al (2013) A prospective analysis of free flap monitoring techniques: physical examination, external Doppler, implantable Doppler, and tissue oximetry. *J Reconstr Microsurg* 29(1): 51–6
- McKinley WC, Jackson AB, Cardenas DD, DeVivo MJ (1999) Long-term medical complications after traumatic spinal cord injury: a regional model systems analysis. *Arch Phys Med Rehabil* 80(11): 1402–10
- National Pressure Ulcer Advisory Panel, European Pressure Ulcer Advisory Panel and Pan Pacific Pressure Injury Alliance (2014) *Prevention and Treatment of Pressure Ulcers: Clinical Practice Guideline*. Emily Haesler (Ed). Cambridge Media: Osborne Park, Western Australia
- Pineda C, Espinosa R, Pena A (2009) Radiographic imaging in osteomyelitis: the role of plain radiography, computed tomography, ultrasonography, magnetic resonance imaging, and scintigraphy. *Semin Plast Surg* 23(2): 80–9
- Schmedes GW, Banks CA, Malin BT et al (2012) Massive flap donor sites and the role of negative pressure wound therapy. *Otolaryngol Head Neck Surg* 147(6): 1049–53
- Yu P, Yu N, Yang X et al (2017) Clinical Efficacy and Safety of Negative-Pressure Wound Therapy on Flaps: A Systematic Review. *J Reconstr Microsurg* 33(5): 358–66