

Use of ALLEVYN[◇] LIFE Non-Bordered foam dressing to manage a heavily exudating venous leg ulcer



Author:
Dr Leanne Atkin

A 62-year-old man presented with a left lower leg venous ulcer on the shin. The ulcer had high exudate levels, which was resulting in strike-through of dressings and there was some evidence of surrounding skin maceration. Investigations revealed an ankle brachial pressure index (ABPI) of 1.4. ALLEVYN[◇] LIFE Non-Bordered foam dressing (Smith & Nephew) was selected to manage and absorb high-levels of exudate and minimise the risk of trauma to the fragile surrounding skin. Multi-layer compression therapy was also used. After 3 weeks, the ulcer had reduced in size and there was a visible improvement in viable skin [Figures 2–5]. The patient found the dressing comfortable with excellent conformability to the lower leg and minimal pain on dressing removal.

Non-healing wounds often produce high levels of exudate, which can impact on patients' quality of life and environment. If these high levels of exudate are not managed appropriately, leakage in the periwound area may occur, increasing the risk of maceration and excoriation to the surrounding skin. This is especially important when the periwound area is already fragile. In these cases, a gentle dressing with high absorbency may be considered.

ALLEVYN[◇] LIFE Non-Bordered foam dressing (Smith & Nephew) is a soft silicone, low-adhesive foam dressing with a 5-layer design that promotes effective exudate management, even when exudate is viscous [Figure 1]. It has high-fluid handling capabilities, absorbing vertically and under pressure. Exudate is locked away from the skin after it has spread through the dressing (Smith & Nephew, 2017).

The dressing is designed to be used under secondary retention, such as tape tubular bandage or compression bandaging. It is available in different shapes and can be cut to the size required.

Case report

A 62-year-old gentleman presented with non-healing ulceration to left shin. The patient reported that 8 weeks prior to presenting, he dropped a spanner while working in his workshop onto his left shin, which initially

resulted in bruising and a small break in the skin. Over the next 2 weeks, the area of open skin increased in size and he attended his local nursing practice who dressed his wound and liaised with community nursing teams to perform a leg ulcer assessment, including ankle brachial pressure index (ABPI). The community nursing assessment concluded signs of venous disease, but the ABPI was elevated at 1.4, indicating arterial wall calcification resulting in unreliable screening for arterial disease. As such, the case was referred to the local vascular clinic to ensure the patient did not have any significant arterial disease and was safe for compression therapy. The patient reported no specific pain and there were no signs of clinical infection. There was evidence of mild oedema to the limb with signs of haemosiderin staining and visible varicosities.

Wound assessment

The wound bed was covered with 95% superficial slough and there were high volumes of exudate, which was resulting in strike-through of dressings and some evidence of surrounding maceration [Figure 2]. ABPI was confirmed at 1.4, but there was a good triphasic Doppler signal with palpable foot pulses, confirming no presence of significant arterial disease and that the patient was suitable for treatment with compression bandaging.

Dr Leanne Atkin is Lecturer Practitioner, Division of Podiatry and Clinical Sciences, The University of Huddersfield, Huddersfield, United Kingdom

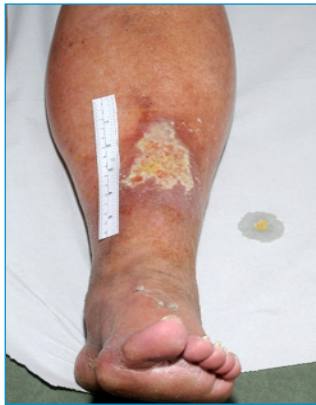

Figure 2. Initial assessment (Baseline).

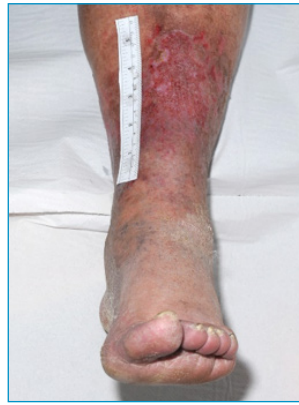

Figure 3. Week 1 review.

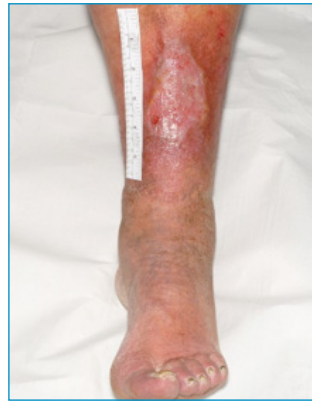

Figure 4. Week 2 review.

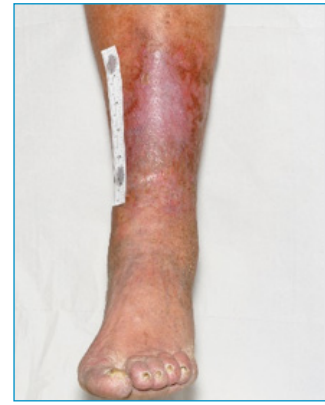

Figure 5. Week 3 review.




Figure 1. 5-layer design of ALLEVYN[®] LIFE Non-Bordered foam dressing (Smith & Nephew, 2017):

1. Opaque pink top film
2. Polyethylene net to provide structure and integrity to the dressing
3. An absorbent, lateral wicking fleece layer that locks-in fluid
4. 2 mm layer of ALLEVYN[®] polyurethane foam
5. Perforated silicone wound contact layer, suitable for fragile skin.

Rationale for planned intervention

ALLEVYN[®] LIFE Non-Bordered foam dressing was applied to the wound bed, to ensure exudate control and provide a degree of padding over the ulcer due to its location directly over the shin. A multi-layer compression bandage system (Profore[®] [Smith & Nephew]) was commenced over the dressing.

First review

ALLEVYN[®] LIFE Non-Bordered foam dressing and bandage system remained in place for a period of 7 days. On first review, it was evident that the wound was showing signs of improvement. The sloughy tissue had completely resolved, there was no further evidence of maceration indicating adequate exudate control [Figure 3]. Additionally, the patient reported the dressing was comfortable and that there had been no problems with strike through. The dressing was easy to remove with no evidence of trauma or adherence to wound bed on removal. The ALLEVYN[®] LIFE Non-Bordered foam dressing was reapplied with compression bandaging as before, and a renewal was planned for 7 days later.

Week 2 review

After a further week, the improvements continued. The wound was starting to reduce in size and there was clear evidence of islands of epithelisation [Figure 4]. Exudate levels had reduced and there was no signs of increased bacterial burden or infection. ALLEVYN[®] LIFE Non-Bordered foam dressing and compression was continued with a renewal planned in 7 days' time.

Week 3 review

On removal of the dressing it was found that the wound had completed healed and was

now covered with 100% epithelial tissue [Figure 5]. The patient was delighted with the speedy outcomes in terms of healing. The newly healed area was obviously fragile and to allow tensile strength of the tissue to improve compression therapy was continued for a further 2 weeks at which point the patient was transferred into a class 2 compression stocking to treat underlying venous hypertension and prevent recurrence.

Conclusion

This case study demonstrates the versatility of ALLEVYN[®] LIFE Non-Bordered foam dressing and how it can be used on wounds throughout the healing spectrum with properties that allow effective management of moderate to high exudate (locks in fluid). It provides protection of the wound bed and ensures atraumatic dressing renewal. Additionally, this case study highlights the importance of compression therapy in wounds where venous hypertension is delaying wound healing (Wounds International, 2013).

WINT

Declaration

This case report has been supported by an unrestricted educational grant by Smith & Nephew.

References

- Smith & Nephew (2017) *Allevyn[®] Life Non-Bordered Foam Dressing Detail Aid*. Smith & Nephew. Data on File.
- Wounds International (2013) *Principles of Compression in Venous Disease: a Practitioner's Guide to Treatment and Prevention of Venous Leg Ulcers*. Available at: <http://www.woundsinternational.com/best-practices/view/principles-of-compression-in-venous-disease-a-practitioners-guide-to-treatment-and-prevention-of-venous-leg-ulcers> (accessed 5.12.2017)