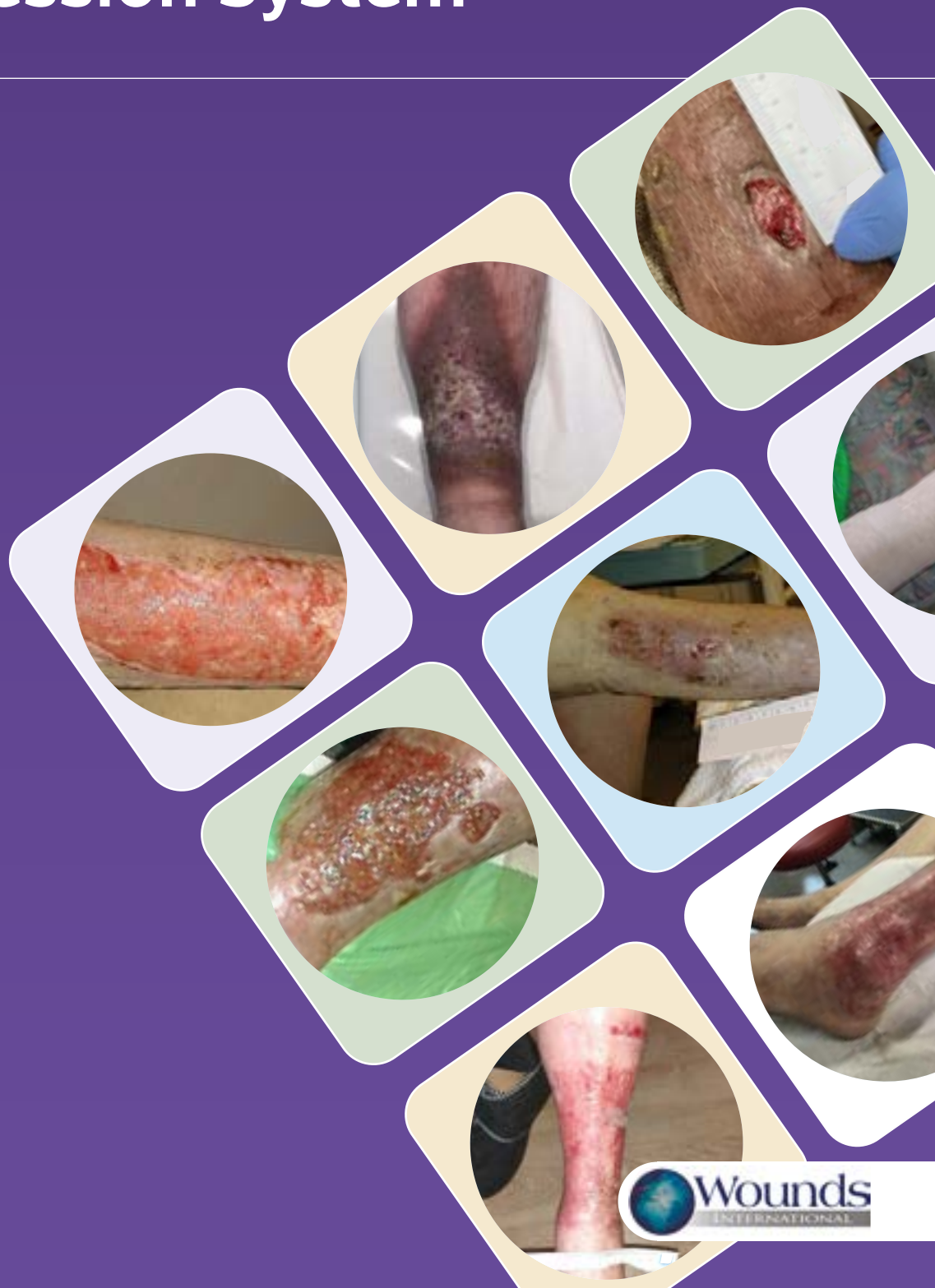

INTERNATIONAL **CASE STUDIES**

3M™ Kerramax Care™ Super-Absorbent Dressing and 3M™ Coban™ 2 Two-Layer Compression System

CASE STUDY SERIES 2022



Published by

Wounds International
A division of Omniamed Communications Ltd
108 Cannon Street
London EC4N 6EU, UK
Tel: +44 (0)20 3735 8244
Email: info@omniamed.com
www.woundsinternational.com



© Wounds International, 2022

Suggested citation

Wounds International (2022) *3M™ Kerramax Care™ Super-Absorbent Dressing and 3M™ Coban™ 2 Two-Layer Compression System case series supplement*. Wounds International, London, UK

Free download available from:
www.woundsinternational.com

All rights reserved ©2022. No reproduction, copy or transmission of this publication may be made without written permission.

No paragraph of this publication may be reproduced, copied or transmitted save with written permission or in accordance with the provisions of the Copyright, Designs and Patents Act 1988 or under the terms of any license permitting limited copying issued by the Copyright Licensing Agency, 90 Tottenham Court Road, London, W1P 0LP.

Supported by an educational grant from 3M.



The views expressed in this publication are those of the authors and do not necessarily reflect those of 3M.

CONTRIBUTORS

Maria Hughes, Independent Tissue Viability Consultant, Queens Nurse, North Wales

Helen Strapp, Registered Advanced Nurse Practitioner, Tallaght University Hospital, Dublin, Ireland

Dr Alita Jaspar, Nursing Specialist, MeanderGroep, Landgraaf, The Netherlands

Dr Bram Balduyck, Thoracic and Vascular Surgeon, AZ Rivierenland, Campus Bornem, Belgium

INTRODUCTION

Venous leg ulcers (VLUs; also known as varicose or stasis ulcers) pose significant challenges to patients and healthcare systems: they are the most common type of leg ulcer, costly to manage, recurring, and may persist for months or years (Harding et al, 2015). This can significantly impact patient quality of life, leading to depression, anxiety and social isolation. Other issues associated with VLUs that can negatively impact on quality of life include the following:

- Pain
- Leaking exudate
- Odour
- Restricted mobility
- Sleep disturbance

VLUs are due to increased pressure within the veins of the lower limb caused by chronic venous insufficiency (CVI). This most commonly occurs because of damage to the valves in leg veins, as in varicose veins, or as a result of venous thrombosis (Harding et al, 2015). Compression therapy is considered the gold-standard treatment for lower limb ulcers, which are a growing concern — with approximately 1.5% of the adult population in the UK affected by active leg and foot ulceration (National Wound Care Strategy Programme [NWCSP], 2020). The NWCSP (2020) lower limb stream has stated that compression therapy is a vital consideration in all lower limb wounds unless specific red flags are present, and that all those presenting with a lower limb wound should receive compression therapy as soon as possible.

The two main principles underpinning how compression therapy works to alleviate CVI (Wounds International, 2013; Vowden et al, 2020):

- Creation of an enclosed system that allows internal pressures to be evenly distributed in the leg
- Variation of interface pressures according to limb shape and tension of bandage applied, which will be influenced by the bandage.

Compression treatments usually consist of compression hosiery, hosiery kits, bandaging and wraps; however, selection of appropriate compression modes and materials will depend on the results of the individual assessment. Findings from a holistic patient assessment should include elements such as limb shape and size, presence of edema, size of the ulcer and patient capability and willingness to engage in their own care.

Other factors to consider for successful compression therapy are the etiology of the underlying disease and the patient's ability to tolerate and use compression effectively as part of their daily routine. Taking into account patient comfort and exudate management are also important factors to be aware of.

3M™ KERRAMAX CARE™ SUPER-ABSORBENT DRESSING AND 3M™ COBAN™ 2 TWO-LAYER COMPRESSION SYSTEM

Combination of the Kerramax Care Dressing and Coban 2 Compression System is designed to help clinicians and patients with the management of VLUs. The Kerramax Care Dressing is a super-absorbent dressing that absorbs and retains high amounts of wound exudate. The super-absorbent core also absorbs and retains bacteria (Thomas and Westgate, 2016) and matrix metalloproteinases, creating an optimal environment for wound healing.

The unique wicking layer evenly distributes fluid both horizontally and vertically throughout the dressing, utilizing the full absorption capacity whilst preventing bulking (Cotton, 2015; Rose, 2015). The Kerramax Care Dressing can be used as either a primary or secondary dressing under all forms of compression, folded or shaped to assist with patient comfort, and it is available in a wide range of sizes that can easily be wrapped around the underneath bandaging (Cotton, 2015).

The Coban 2 Layer Compression System is a two-layer compression bandage system that is designed to deliver therapeutic compression required for treating patients with VLUs. The Coban 2 Compression System is easy to apply and suitable for a wide range of patients (Vowden et al, 2011).

CASE STUDY EVALUATIONS

In this supplement, eight cases are presented evaluating the clinical performance of the Kerramax Care Dressing and Coban 2 Compression System on various patients with VLUs being treated in different care settings. The cases are representative of a clinician's everyday use of the Kerramax Care Dressing and Coban 2 Compression System.

The patient and wound condition were regularly monitored for clinical signs of improvement, such as reduction in wound size; improvement in wound bed tissue composition and improvement of the surrounding skin; level and consistency of exudate; pain; signs of infection; impact of the wound on patient quality of life and patient satisfaction with treatment.

Dressing and compression application (e.g. rationale for use, intended outcome, ease of application) and performance (e.g. evidence of strikethrough or leakage, wear time, exudate retention) were observed and any relevant additional treatment, referral and advice were also reported.

As with any case study, the results and outcomes should not be interpreted as a guarantee or warranty of similar results. Individual results may vary depending on the patient's circumstances and condition.

REFERENCES

- Cotton S (2015) *The management of a chronic leg ulcer using KERRAMAX CARE™ Super-Absorbent Dressing under compression*. Poster presented at Wounds UK; November 2015; Harrogate, UK
- Harding K, Dowsett C, Fias L et al (2015) *Simplifying venous leg ulcer management. Consensus recommendations*. Wounds International, London. Available at: www.woundsinternational.com
- National Wound Care Strategy Programme (2020) *Lower Limb. Recommendations for Clinical Care*. Available at: <https://www.ahsnetwork.com/app/uploads/2020/11/Lower-Limb-Recommendations-20Nov20.pdf> (accessed 17.03.2021)
- Rose R (2015) *A large clinical evaluation assessing the tolerance & effectiveness of super-absorbent dressing, Kerramax Care™*. Poster presented at Wounds UK; November 2015; Harrogate, UK
- Thomas H, Westgate SJ (2016) *An in vitro comparison of MRSA and P. aeruginosa sequestration by five super-absorbent wound dressings*. Poster presented at EWMA; 11-13 May 2016; Bremen, Germany
- Vowden K, Vowden P, Partsch H, Treadwell T (2011) *3M™ Coban™ 2 Compression Made Easy*. Wounds International 2(1)
- Vowden P, Kerr A, Mosti G (2020) *Demystifying mild, moderate and high compression systems - when and how to introduce "lighter" compression*. Wounds International, London. Available at: www.woundsinternational.com
- Wounds International (2013) *Principles of Compression in Venous Disease: a Practitioner's Guide to Treatment and Prevention of Venous Leg Ulcers*. Available at: www.woundsinternational.com

CASE 1: Traumatic leg wound in a reluctant patient

Maria Hughes, Independent Tissue Viability Consultant, Queens Nurse, North Wales

An 88-year-old woman sustained extensive trauma to the lateral aspect of her right leg. A large hematoma developed (Figure 1) and the patient was initially transferred to hospital.

The patient had concerns about pain and the prospect of a right lower extremity amputation. Analgesia was reviewed and appropriate levels were determined. A full leg ulcer assessment was performed including an ankle brachial pressure index (ABPI) to ascertain the vascular status of the limb. The patient's ABPI value was 0.85.

Upon completion of the full leg ulcer assessment, conservative sharp debridement was performed as it was felt important to evacuate a hematoma of this size and reduce the risk of leaving dead space and the possibility of abscess formation. As the patient was initially apprehensive of any intervention, developing trust with her was integral to her wound management.

The combination of conservative and blunt debridement helped to remove a substantial amount of hemolysis (Figure 2). Figure 3 shows the wound post debridement.

3M™ Kerramax Care™ Super-Absorbent Dressing was applied to the lower extremity trauma wound as a primary dressing, which enabled exudate to be sealed within the dressing to mitigate the risk of skin maceration. The leg was bandaged using the 3M™ Coban™ 2 Two-Layer Compression System.

Following 6 weeks of treatment, the patient transitioned to a non-adherent product under the Coban 2 Layer Compression System. Dry skin was an ongoing issue, but this was effectively managed with emollients. Figure 4 shows the wound completely re-epithelialized.

Final comments

The patient found the Coban 2 Compression System comfortable to wear and conformable to her leg. She was pleased at being able to wear her usual footwear as she was opposed to the idea of wearing a surgical boot.

The recommended long-term management plan would be to wear compression hosiery; however, this patient declined. Emollients are still regularly applied and, as of the last visit, her skin remains intact.

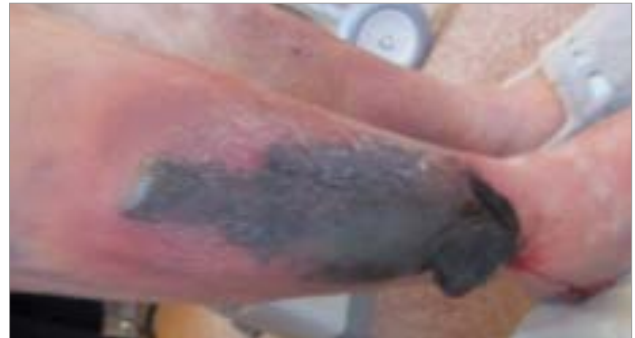

Figure 1. Initial presentation

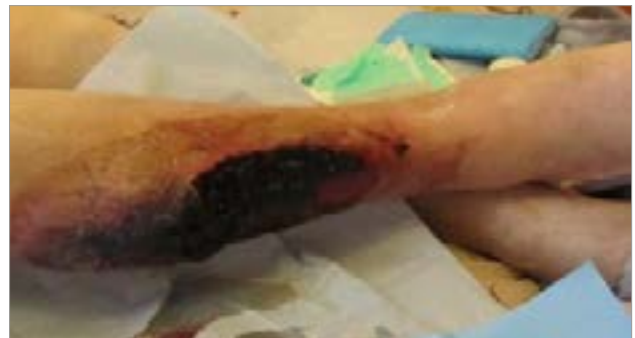

Figure 2. Lower extremity following hematoma removal

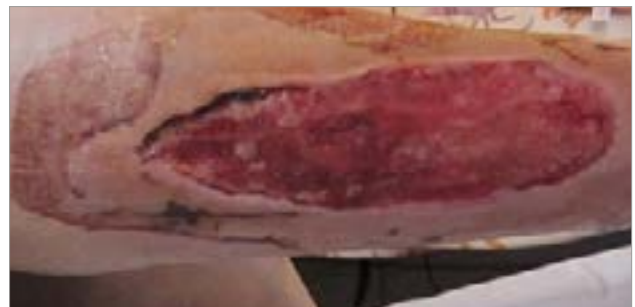

Figure 3. Post debridement (+40 days)

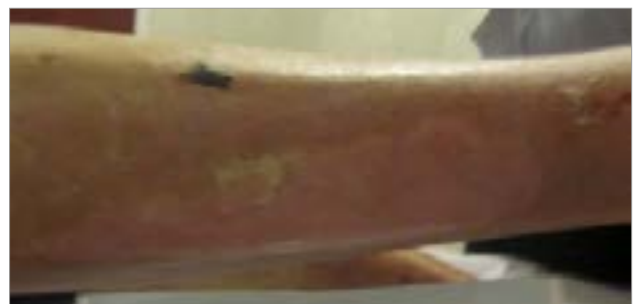

Figure 4. Wound completely re-epithelialized (+10 weeks)

CASE 2: Venous leg ulcer on the left medial malleolus

Helen Strapp, Registered Advanced Nurse Practitioner, Tallaght University Hospital, Dublin, Ireland

A 38-year-old man with a history of venous ulceration presented to the wound management clinic with a venous leg ulcer on his left medial malleolus. The wound bed comprised 70% granulation tissue and 30% slough (Figure 1) and measured 1cm (length) x 1cm (width) x 0.2cm (depth). There were signs of atrophy blanche on the surrounding skin and moderate levels of thin exudate were present. Palpable pedal pulses were noted and, therefore, an ankle brachial pressure index (ABPI) did not need to be obtained.

The patient was not aware of when or how the wound had occurred but rated wound pain at 7 out of 10 on a visual analogue scale (VAS; 1 = no pain, 10 = unbearable pain); the pain was so severe it affected his sleep. He was on the following medication as per local pain management policy: codeine phosphate hemihydrate 30mg/paracetamol 500mg (2 tablets, every 6 hours).

The intended outcome was for complete wound healing. The wound was cleansed with normal saline and 3M™ Kerramax Care™ Super-Absorbent Dressing (10x10cm) was applied to protect the wound and absorb exudate. Ease of application was rated "excellent". 3M™ Coban™ 2 Two-Layer Compression System was applied with the aim to provide effective compression, which has been shown to reduce pain. The Coban 2 Compression System was selected as the patient had a history of painful ulceration to the ankle.

The compression system was easy to apply, and the patient was given an information leaflet on the effects of compression and its mode of action. It was discussed with the patient the importance of not removing the compression bandages before the planned dressing change (scheduled for 7 days' time). The clinician also talked about the benefits of weight reduction with the patient.

Review 1 (+9 days):

The Kerramax Care Dressing retained wound exudate, stayed in place, and there was no strikethrough or leakage through the dressing or on to the bandaging. Although the wound size and level of edema remained the same (Figure 2), the patient had been satisfied with treatment and found the dressing comfortable to wear. Pain at dressing change was rated at 7 out of 10. The clinician rated wear time of the Kerramax Care Dressing under compression with the Coban 2 Compression System as "very good".

The patient commented that the Coban 2 Compression System felt tight, especially in the hot summer weather. The clinician explained that compression is an important tool to manage

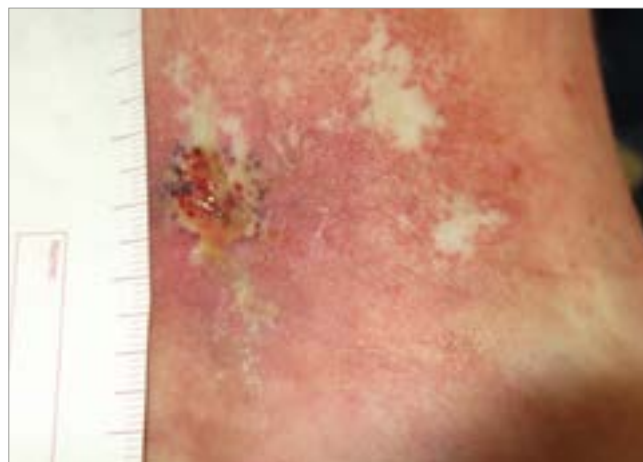


Figure 1. Initial presentation

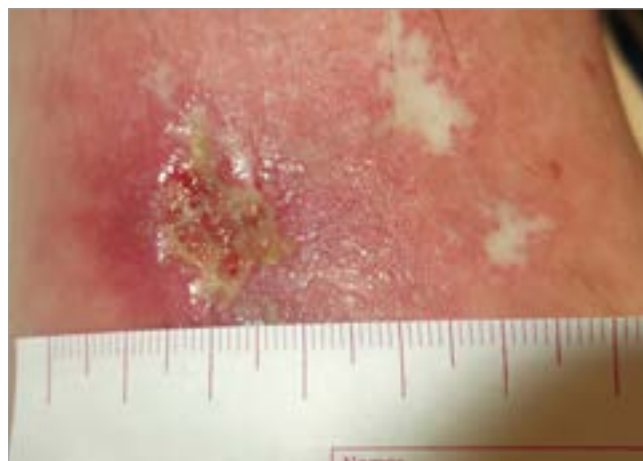


Figure 2. Review 1 (+9 days)

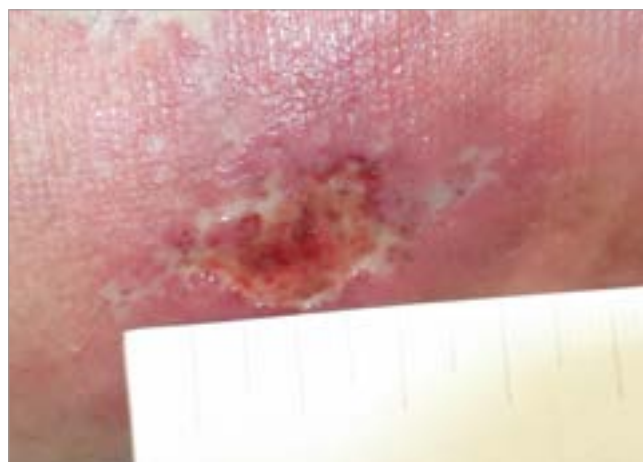

Figure 3. Review 2 (+15 days)

VLU and should in the long-term reduce leg pain. The wound was cleansed with saline, and 3M™ Cavilon™ No Sting Barrier Film was applied to protect the surrounding skin from maceration.

3M™ Adaptic™ Touch Non-Adhering Silicone Dressing was placed under the Kerramax Care Dressing to prevent the dressing from adhering to the wound bed, and to minimize pain at dressing change. The Coban 2 Compression System was applied to provide effective compression, which has been shown to manage VLU and reduce pain. The patient was encouraged to continue to mobilize and keep moving.

Review 2 (+15 days):

After 15 days, the wound had improved slightly (Figure 3), and exudate levels had reduced. The wound bed comprised 80% granulation tissue and 20% slough. The treatment regimen was continued as before with the aims to protect the wound and surrounding skin, reverse hypertension and promote wound healing. An emollient was applied to the surrounding skin to keep the leg moisturized and dressing change was planned for 6 days' time.

Review 3 (+21 days):

After 3 weeks of using the Kerramax Care Dressing and Coban 2 Compression System, the wound bed composition had continued to improve and now comprised 90% granulation tissue and 10% slough (Figure 4).

The patient understood the importance of the compression, but still found it tight. The patient was able to mobilize well, but there was some discomfort during the night. Pain relief was reduced to paracetamol 500mg; the patient was happy to continue with the treatment plan.

Review 4 (+27 days):

For this patient, the wound was slow to heal, but both the clinician and patient were satisfied with treatment, especially in terms of comfort and ease of application. The wound was less sloughy than at initial presentation (Figure 5), and the decision was made to continue with the treatment regimen to promote healing.

Final comments

The Kerramax Care Dressing and Coban 2 Compression System in combination was rated "good". The dressing was soft and absorbent of exudate, and the compression bandage was easy to apply. As the bandage consists of two layers and was not bulky, the patient was able to continue wearing his own shoes during treatment.

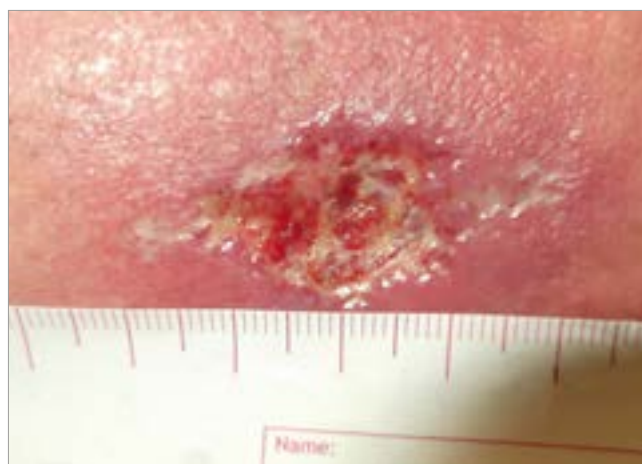


Figure 4. Review 3 (+21 days)

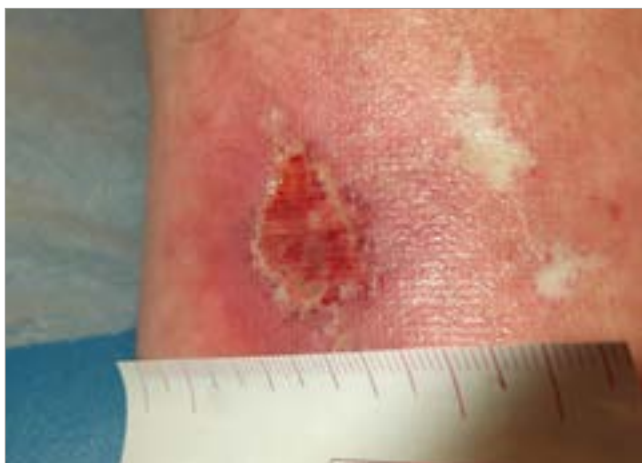


Figure 5. Review 4 (+27 days)

CASE 3: Two venous leg ulcers on the lower left leg

Dr Alita Jaspar, Nursing Specialist, MeanderGroep, Landgraaf, The Netherlands

A 75-year-old man presented with two venous leg ulcers, that had been present for 3 months, on the lateral aspect of his lower left leg. The patient had stage 1 edema, was obese and had a history of diabetes, heart disease and venous insufficiency. An ankle brachial pressure index (ABPI) had been performed by the GP and compression therapy previously applied using short-stretch bandages.

The first wound measured 2.5cm (length) x 2cm (width) x 0.6cm (depth), and the wound bed comprised 60% slough and 40% granulation tissue (Figure 1). The second wound measured 7cm (length) x 2cm (width) with superficial depth and the wound bed comprised 80% granulation tissue, 15% epithelializing and 5% slough (Figure 2). There were signs of atrophy blanche and hemosiderin staining on the fragile surrounding skin, which was dry and flaky. A moderate level of exudate was present. There were no signs of infection, and the patient had no wound pain.

The wounds were cleansed with polyhexamethylene biguanide (PHMB) solution and the surrounding skin hydrated with a cetomacrogol cream. 3M™ Kerramax Care™ Super-Absorbent Dressing was selected to absorb and manage exudate levels with the aim to reduce the frequency of dressing changes. Ease of application was rated "excellent", and no secondary dressing was required.

Compression was applied with the 3M™ Coban™ 2 Two-Layer Compression System was applied to provide effective compression therapy, which has shown to manage edema. The patient was advised to stay mobile and to notify the nurse if pain symptoms should occur. A dressing change was planned for 3 days' time.

Review 1 (+7 days):

At the first dressing review, both ulcers had improved. The first wound had slightly less depth and measured 2.5cm (length) x 2cm (width) x 0.5cm (depth), with the wound bed showing increased granulation tissue (Figure 3). The second wound, a superficial skin lesion, had decreased in size to 1cm (length) x 0.4cm (width) and almost closed (Figure 4). The condition of the surrounding skin remained the same and there were moderate levels of thin exudate. The level of edema had reduced. The patient had remained active during treatment and the wound did not affect his ability to conduct activities of daily living.

The Kerramax Care Dressing stayed in place during wear time under compression, retained exudate and no strikethrough or leakage was noted. The patient was highly satisfied with treatment

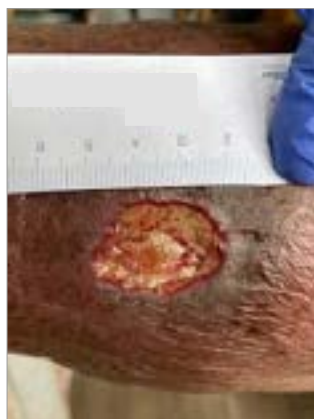

Figure 1. Initial presentation (first wound)

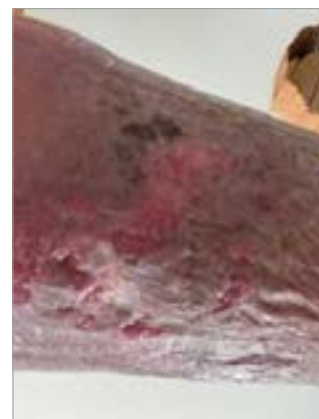

Figure 2. Initial presentation (second wound)

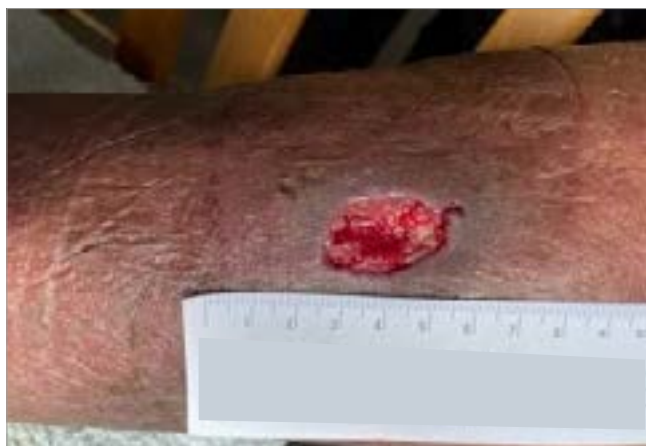

Figure 3. Review 1 (+7 days; first wound)

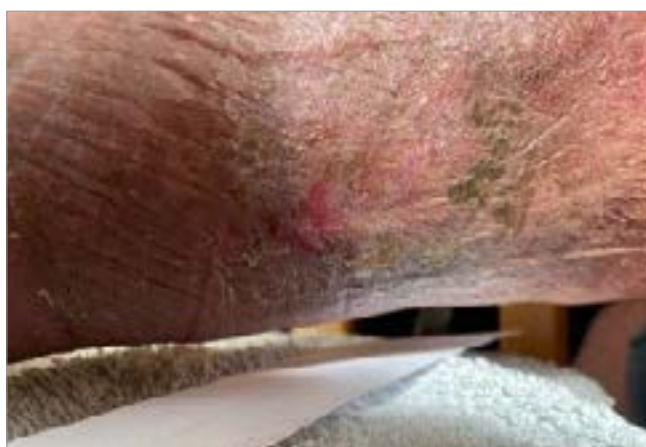

Figure 4. Review 1 (+7 days; second wound)

and found wearing the Kerramax Care Dressing and Coban 2 Compression System very comfortable. The bandage was not bulky, stayed in place and did not fall off compared to the two-layer system that had been used previously. The new treatment regimen allowed the patient to move more freely and to wear his own shoes and, as a result, treatment was re-applied as before.

Review 2 (+14 days):

At the second dressing review, 7 days later, the first wound showed healthy granulation tissue (Figure 5) and the second wound had now fully closed and healed. The level of edema and condition of the surrounding skin had improved with only some hemosiderin staining visible. The wound was cleansed with PHMB, and treatment continued with the Kerramax Care Dressing and Coban 2 Compression System to manage exudate and to provide effective compression.

Review 3 (+21 days):

At the third dressing review, the wound had decreased in size to 2.4cm (length) x 1.5cm (width) x 0.2cm (depth) and comprised 90% granulation tissue and 10% epithelializing (Figure 6). Hyperkeratosis was present at the location of the second healed wound, with minimal edema present. The surrounding skin was dry and there were low levels of thin exudate. The clinician and patient were both highly satisfied with treatment as fewer dressing changes were required. As a result, the treatment regimen was re-applied as before.

Review 4 (+28 days):

At the final review, the wound had decreased further in size to 1.5cm (length) x 1cm (width) x 0.1cm (depth), with a healthy wound bed showing granulation and epithelialization tissue (Figure 7). The clinician and patient remained highly satisfied with treatment, and the patient continued to rate the comfort of the Kerramax Care Dressing and Coban 2 Compression System as "excellent".

Final comments

Over the 4-week period, one wound had completely healed, and the other had progressed well with minimal dressing changes required. The Kerramax Care Dressing and Coban 2 Compression System were very easy to apply and remained *in situ* during wear time.

The patient found treatment very comfortable. He was able to wear his own shoes and was not concerned about the bandage moving or the fixation plasters falling off. This helped to increase tolerance to treatment and for the patient to continue with daily activities.

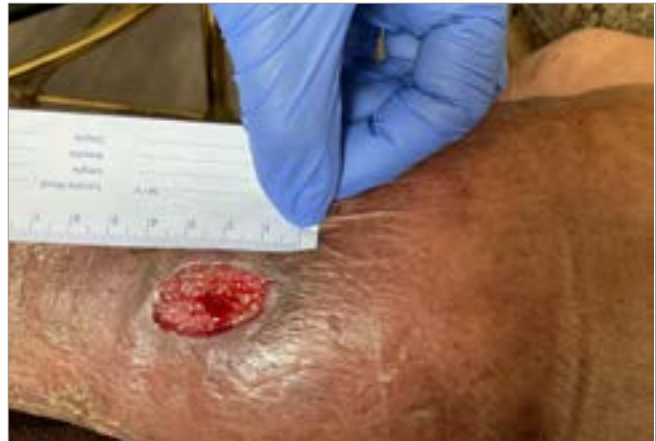

Figure 5. Review 2 (+14 days)

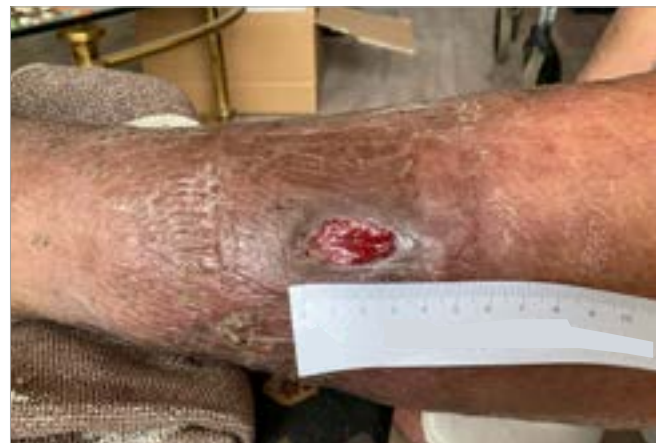

Figure 6. Review 3 (+21 days)

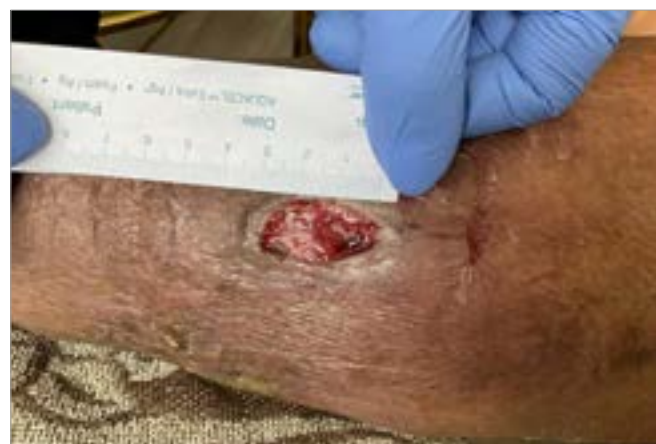

Figure 7. Review 4 (+28 days)

CASE 4: Traumatic leg wound with venous disease

Maria Hughes, Independent Tissue Viability Consultant, Queens Nurse, North Wales

An 86-year-old woman presented to the clinic for management of a trauma injury measuring over 20cm in length to the lateral right leg following a fall. Previous medical history included anemia and hypertension. Previous treatment included various dressings, which did aid healing but did not address the underlying disease.

A full assessment of the leg and ulcer indicated clear evidence of venous disease with hemosiderin staining and underlying edema (**Figure 1**). The ulcer required exudate management and the limb required edema reduction. The wound was cleansed and emollients were applied to improve the surrounding skin. 3M™ Kerramax Care™ Super-Absorbent Dressing was applied to manage the exudate and the 3M™ Coban™ 2 Two-Layer Compression System to manage edema.

After 2 weeks, the exudate and edema were sufficiently reduced; the dressing regimen was changed to a non-adherent dressing. The Coban 2 Layer Compression System was continued. The wound was almost healed at 12 weeks (**Figure 2**). At that point the compression system was discontinued, and a 2-layer hosiery kit was implemented with a foam dressing. The wound progressed to complete healing after 15 weeks.

Final comments

The patient reported that combination of the Kerramax Care Dressing and Coban 2 Compression System was very comfortable; the low profile allowed her to continue wearing her usual footwear.

The compression system did not slip during wear and was easy to remove at the weekly check-up visits. The recommended long-term management plan would be to wear compression hosiery; however, this patient declined. She did agree to continue to moisturize her skin with emollients to reduce the risk of skin breakdown.

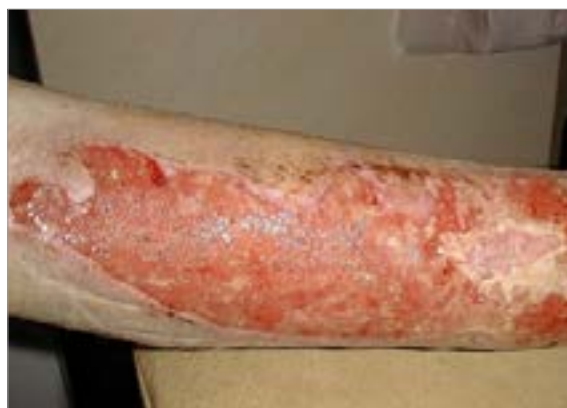

Figure 1. Initial presentation

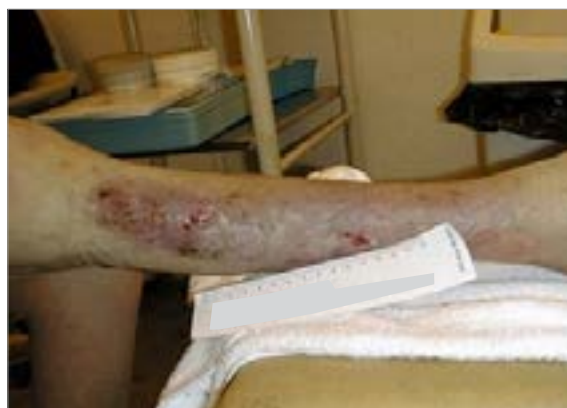

Figure 2. +12 weeks of treatment

CASE 5: Traumatic leg wound with venous disease and significant pain

Maria Hughes, Independent Tissue Viability Consultant, Queens Nurse, North Wales

A 72-year-old man sustained trauma to the lateral aspect of his left leg (**Figure 1**). Community nurses applied conventional dressings; however, pain was a major complication for this patient. The patient was able to fully verbalize but found it difficult to express their wound pain due to early-onset dementia. Therefore, the Abbey Pain Scale was employed to register the severity of discomfort; a total pain score of 6-7 was calculated.

For this reason, there was a misconception among the community nurses that the “patient would not tolerate compression” and a full leg ulcer assessment was not pursued. However, if pain is effectively managed and trust is gained, then patients can successfully tolerate compression bandaging. Prior to implementation of an intervention to address the leg injury, suitable analgesia was prescribed and administered to manage the pain and gain the patient’s trust.

A one-week interval between visits allowed for the analgesia to take effect. Upon return to the residential home, the patient agreed to a leg ulcer assessment as pain was effectively managed. The patient demonstrated evidence of venous disease with ankle flare and hemosiderin staining. As the exudate was irritating the patient’s skin, the selection of an appropriate advanced wound dressing product was crucial.

After the full leg ulcer assessment, 3M™ Kerramax Care™ Super-Absorbent Dressing was applied to the lower extremity trauma wound and the leg was bandaged using the 3M™ Coban™ 2 Two-Layer Compression System (**Figure 2**). The Kerramax Care Dressing absorbed and sealed in exudate to mitigate the stinging effect. The Coban 2 Compression System remained in place without slipping to provide this patient the ability to remove his trousers over the bandage.

Final comments

Combination of the Kerramax Care Dressing and Coban 2 Compression System was effective at managing exudate. The patient found the combination comfortable to wear.

Wearing a pair of socks to conceal the compression bandage also provided him with a sense of normality while on outings with his family.

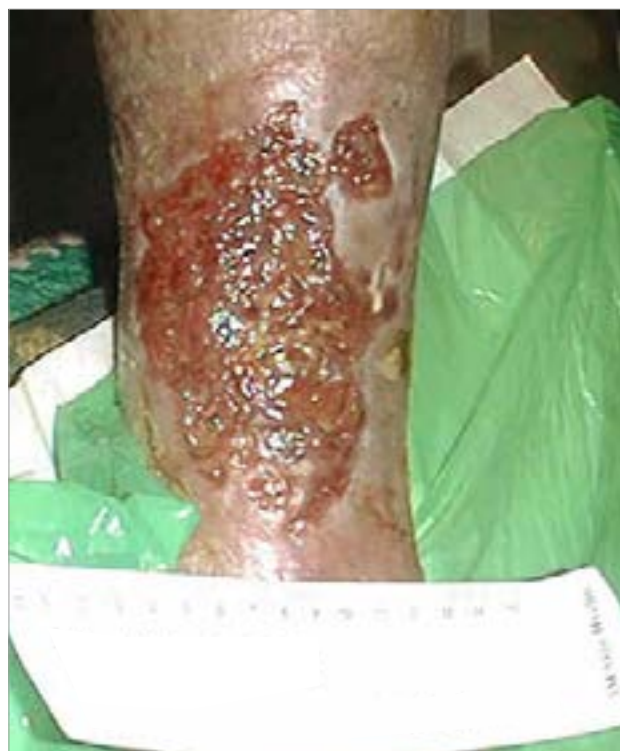

Figure 1. Initial presentation

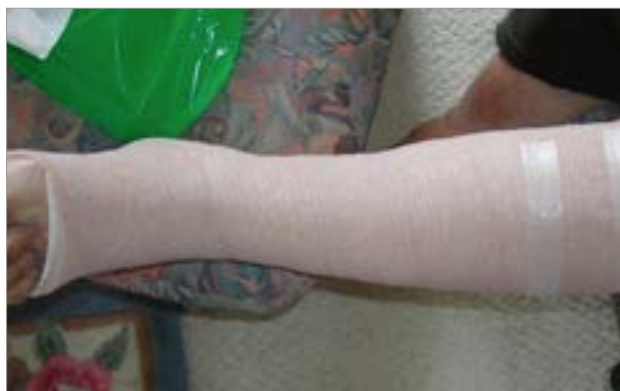

Figure 2. Lower extremity with KerraMax Care Dressing under the Coban 2 Compression System

CASE 6: Venous leg ulcer on the pretibial aspect of the right and left leg

Dr Bram Balduyck, Thoracic and Vascular Surgeon, AZ Rlvierenland, Campus Bornem, Belgium

A 57-year-old man with stage 2 edema presented to the outpatient clinic with a venous leg ulcer on the pretibial aspect of his right and left leg. Both wounds had been present for 12 days and had been caused by repeated scratching of the itchy skin. An ankle brachial pressure index (ABPI) of 0.85 (right leg) and 1.0 (left leg) had recently been obtained, and a duplex ultrasound performed on the right leg. Treatment previously included a dressing containing 10% povidone iodine and compression stockings; however, the patient struggled to follow the care plan and had difficulty performing self-care.

Both wounds comprised 40% granulation tissue, 30% slough, 20% necrotic tissue and 10% epithelialization (Figure 1 and 2). The wound on the right leg measured 0.8cm (length) x 0.5cm (width) x 0.2cm (depth). The surrounding skin was inflamed/red and macerated; there were signs of erythema, discoloration and hemosiderin staining. The wound on the left leg measured 0.6cm (length) x 0.4cm (width) x 0.1cm (depth). Erythema and hemosiderin staining were visible on the surrounding skin. The patient had varicose veins on both legs.

Exudate levels were described as heavy for both wounds; strikethrough and leakage were noted. The patient rated wound pain at 4 out of 10 on a visual analogue scale (VAS; 1 = no pain, 10 = unbearable pain) for the right leg and 5 out of 10 for the left leg but was not taking pain medication. There was a continuous odor from both limbs, which had a negative impact on the patient's quality of life.

The intended outcome was to manage exudate levels and promote wound healing. The wounds were debrided and 3M™ Kerramax Care™ Super-Absorbent Dressings (5x5cm) were applied to absorb and retain the high levels of exudate. Ease of application was rated "good", and no secondary dressings were required. 3M™ Coban™ 2 Two-Layer Compression System was applied to provide effective compression therapy, which has been shown to reduce pain and manage edema. Ease of application was rated "excellent". The patient was advised to elevate his limbs when possible. Dressing changes were planned for 3 days' time.

Review 1 (+4 days):

Dressing performance of the Kerramax Care Dressing was rated "excellent" at week 1. The dressing had retained exudate and there was no strikethrough or leakage on the dressing or bandaging. The clinician commented that the level of edema had improved on both legs, and the patient rated pain on removal of the Kerramax Care Dressing at 1 out of 10. The patient was satisfied with treatment — the bandage was not bulky, stayed in place and allowed better mobility. The wounds

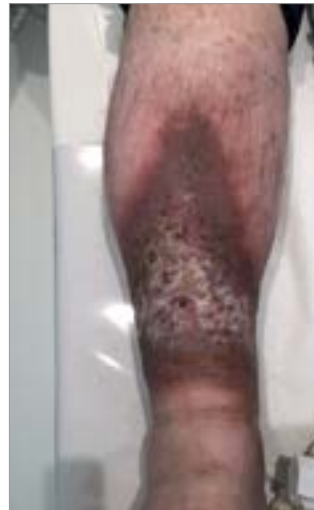

Figure 1. Initial presentation (right leg)

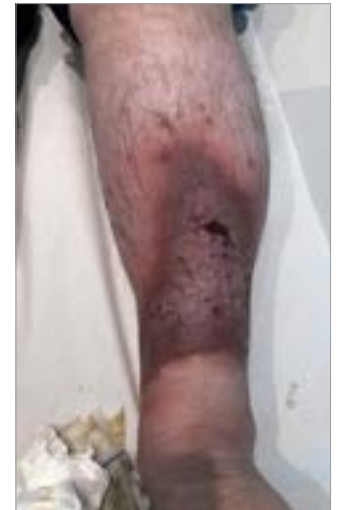

Figure 2. Initial presentation (left leg)

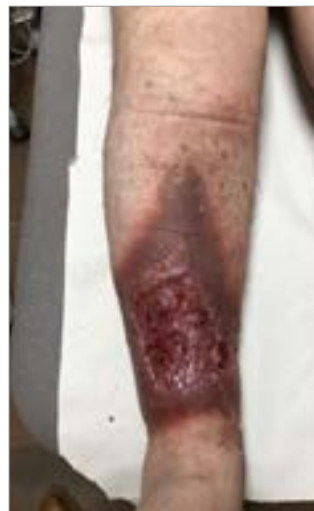

Figure 3. Review 1 (+4 days; right leg)

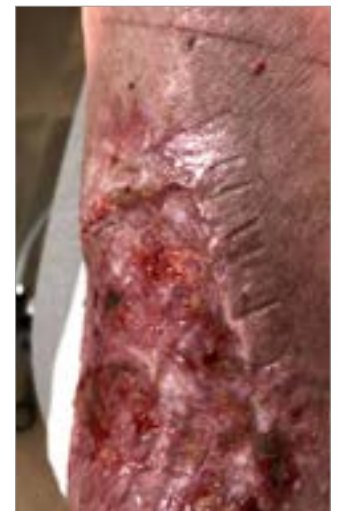

Figure 4. Review 1 (+4 days; left leg)

were less odorous and exudate levels had reduced, which had a positive effect on the patient's quality of life.

Both wounds had reduced in size at this first dressing review: the wound on the right leg (Figure 3) measured 0.7cm (length) x 0.4cm (width) x 0.15cm (depth) and the wound on the left leg (Figure 4) measured 0.5cm (length) x 0.3cm (width) x 0.1cm (depth). Less necrosis was noted, the condition of the surrounding skin remained the same and there were moderate levels of thin exudate for both wounds. The patient rated wound pain at 3 out of 10. Treatment continued with the Kerramax Care Dressing and Coban 2 Compression System to manage exudate levels and provide compression to manage edema and VLU.

Review 2 (+7 days):

At the second dressing review, 3 days later, the level of edema had continued to improve, and dressing performance and wear time of the Kerramax Care Dressing was rated "excellent". The wounds had reduced further in size (Figure 5 and 6) and there was less necrosis and erythema. Low levels of thin exudate were present and varicose veins were still visible on the surrounding skin, with some hemosiderin staining on the left leg. The treatment regimen continued as before. The intended outcome was to manage exudate and edema and promote wound healing.

Review 3 (+14 days):

The patient was extremely satisfied with treatment and rated comfort of the Kerramax Care Dressing and Coban 2 Compression System as "excellent". The wound on the left leg remained the same size (Figure 7) but the wound on the right leg (Figure 8) had reduced to 0.6cm (length) x 0.2cm (width) x 0.15cm (depth). The condition of the surrounding skin had improved, and less erythema was noted. The treatment regimen continued because levels of pain (2 out of 10) and exudate (odor) had reduced, and wound healing had progressed.

Review 4 (+35 days):

Both wounds had progressed well at the end of the 4-week period and the patient's mobility and ability to conduct activities of daily living had improved. The decision was made to continue treatment with the aims of managing exudate and treating the varicose veins on the surrounding skin.

Final comments

Treatment continued with the Kerramax Care Dressing and Coban 2 Compression System to manage exudate levels, improve wound odor, and provide compression to manage edema and VLU. It was found comfortable and stayed in place.

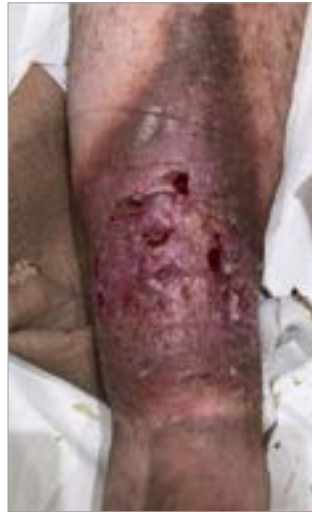

Figure 5. Review 2 (+7 days; right leg)

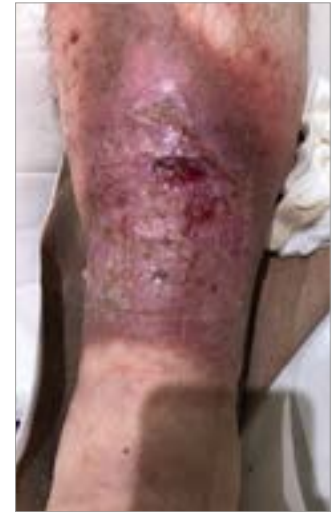

Figure 6. Review 2 (+7 days; left leg)

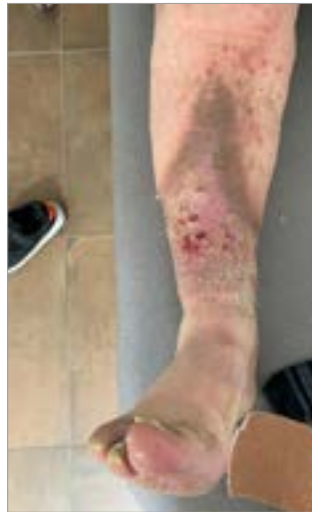

Figure 7. Review 3 (+14 days; right leg)

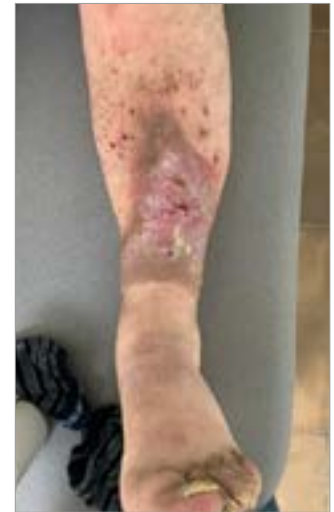

Figure 8. Review 3 (+14 days; left leg)

CASE 7: Venous ulcer on the left lower leg

Dr Alita Jaspar, Nursing Specialist, MeanderGroep, Landgraaf, The Netherlands

An 89-year-old woman had a history of stage 1 edema, deep venous thrombosis, diabetes and cognitive impairment and lived in a long-term care facility. The patient presented with a venous leg ulcer of 10 months' duration on her left lower leg (Figure 1a-c) measuring 10cm (length) x 7cm (width) x 0.2cm (depth).

The wound had developed due to repeated scratching. Compression therapy was being used prior to the evaluation — arterial disease was excluded by the surgeon. There were several superficial skin injuries at the wound site and a high level of exudate was present. The wound bed comprised 50% granulation tissue and 50% slough, with the condition of the surrounding skin inflamed/red and macerated. The patient rated wound pain at 8 out of 10 on a visual analogue scale (VAS; 1 = no pain, 10 = unbearable pain) and was taking 1g of paracetamol four times a day as per local pain management policy.

Prior to this case study, a primary wound dressing containing iodine was applied along with a secondary absorbent dressing and covered with a two-layer compression system. However, the patient would remove the compression system and the long-term care nurse would remove the bandages when the patient experienced wound pain.

As part of this evaluation, the wound was cleansed with tap water and a barrier cream was applied to the surrounding skin. 3M™ Kerramax Care™ Super-Absorbent Dressing was applied to absorb the high levels of exudate, prevent leakage and to reduce dressing change frequency, along with the 3M™ Coban™ 2 Two-Layer Compression System. The nurses at the long-term care facility were advised (if appropriate) not to remove the compression bandages and to increase pain medication if the patient experienced wound pain. Dressing change was planned for the following day.

Review 1 (+1 days):

A day later, several wound lesions had closed, and the condition of the wound had improved. The wound had decreased in size to 7cm (length) x 4cm (width) with no depth and the wound bed comprised 100% granulation tissue. Maceration had improved to the surrounding skin and there was a moderate level of thin, serous exudate.

Performance of the Kerramax Care Dressing was rated "excellent" by the nurse specialist; the dressing had stayed in place, retained exudate and there was no strikethrough or leakage. The level of edema had improved, and the dressing did not cause the patient

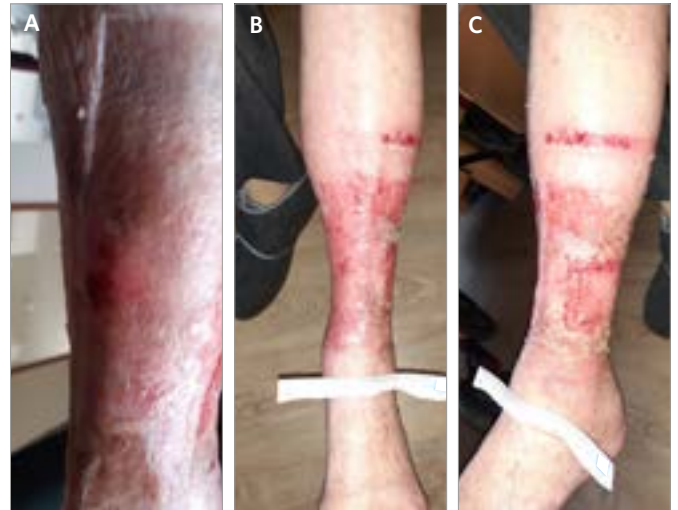


Figure 1. Initial presentation

pain on removal. The patient found the Kerramax Care Dressing and Coban 2 Compression System comfortable to wear and was satisfied with treatment as there was no more leakage and, therefore, fewer dressing changes were required. As a result, the patient expressed a calmer attitude towards treatment and there was less tendency to scratch. The treatment regimen was re-applied as before.

Review 2 (+6 days):

At the second review, the patient continued to experience no pain on dressing removal. There were now two wounded areas visible; the lateral wound had closed with only a few superficial injuries and the medial wound had decreased in size to 4cm (length) x 1cm (width) with no depth.

The condition of the surrounding skin had improved, and the level of edema and exudate had reduced. The treatment regimen was re-applied as before to reduce the likelihood of leakage and maceration of the skin, and to reduce edema and frequency of dressing changes. A steroid cream was applied to the skin to manage inflammation.

Review 3 (+13 days):

After 7 days, the medial wound bed still comprised 100% granulation tissue, several superficial injuries had closed, and the condition of the surrounding skin had improved (Figure 2a-c). The treatment regimen continued because wound healing had progressed.

Review 4 (+16 days):

The medial wound had almost closed, and the surrounding skin was healthy. The clinician and patient were both satisfied with how treatment had progressed; ease of application was still rated "excellent".

Final comments

Treatment with the Kerramax Care Dressing and Coban 2 Compression System made a significant difference to the patient, and the venous leg ulcer of 10 months' duration had improved within 3 days.

The Kerramax Care Dressing had a high absorption capacity, and the Coban 2 Compression System provided comfort and remained *in situ* during wear time. The combination of both helped to reduce the frequency of dressing changes from twice a day to twice a week and had a positive effect on the patient's quality of life.

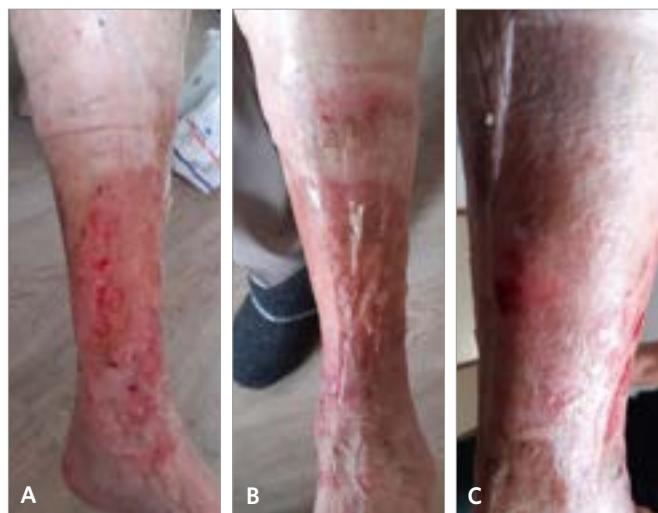

Figure 2. Review 3 (+13 days)

CASE 8: Venous leg ulcer on the lateral aspect of the left leg

Dr Bram Balduyck, Thoracic and Vascular Surgeon, AZ Rlvierenland, Campus Bornem, Belgium

An 80-year-old woman with a history of lymphedema, arterial hypertension and stage 1 edema presented to the outpatient clinic with a venous leg ulcer (Figure 1), resulting from trauma. An ankle brachial pressure index (ABPI) of 1.0 had recently been obtained, and a duplex ultrasound was performed. The wound had been present for 2 months, measured 1.2cm (length) x 1cm (width) x 0.1cm (depth) and comprised 90% slough and 10% granulation tissue.

Erythema was prominent and the surrounding skin was inflamed/red and macerated. There were heavy levels of thin exudate and strikethrough with the current dressing, and leakage through clothes and onto bed linen was observed. There were no signs of infection, and the patient had no wound pain.

The intended outcome was to manage exudate levels and edema. 3M™ Kerramax Care™ Super-Absorbent Dressing (10x10cm) was applied to absorb exudate and the 3M™ Coban™ 2 Layer Compression System for compression to manage edema. Ease of application was rated “excellent” for both the Kerramax Care Dressing and Coban 2 Compression System.

Review 1 (+7 days):

Dressing performance of the Kerramax Care Dressing was rated as “excellent”, and no strikethrough or leakage was visible on the dressing or bandage. The Kerramax Care Dressing stayed in place, retained exudate and the patient found the dressing comfortable to wear under compression with the Coban 2 Compression System.

The patient commented that the bandage was bulky for small, elegant shoes but allowed better movement and mobility and was not hot to wear. There was less erythema and edema had improved, but the surrounding skin remained inflamed and there were heavy levels of thin exudate.

Review 2 (+14 days):

The wound had reduced slightly in length and width after 14 days of treatment and the level of edema had improved. The wound bed composition comprised 60% slough and 40% granulation tissue, and there were moderate levels of thin exudate.

The patient rated pain at just below 1 out of 10 on a visual analogue scale (VAS; 1 = no pain, 10 = unbearable pain) but found treatment very comfortable, and their ability to conduct activities of daily living improved. Treatment continued with Kerramax Care

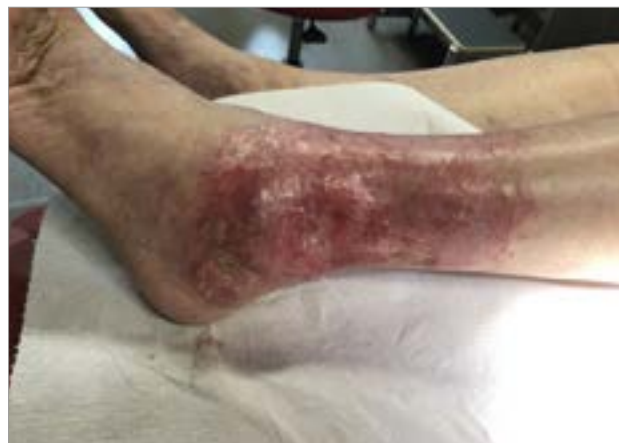

Figure 1. Initial presentation

and Coban 2 Compression System to manage exudate levels and provide compression to manage edema. Ease of application was rated “excellent”.

Review 3 (+25 days):

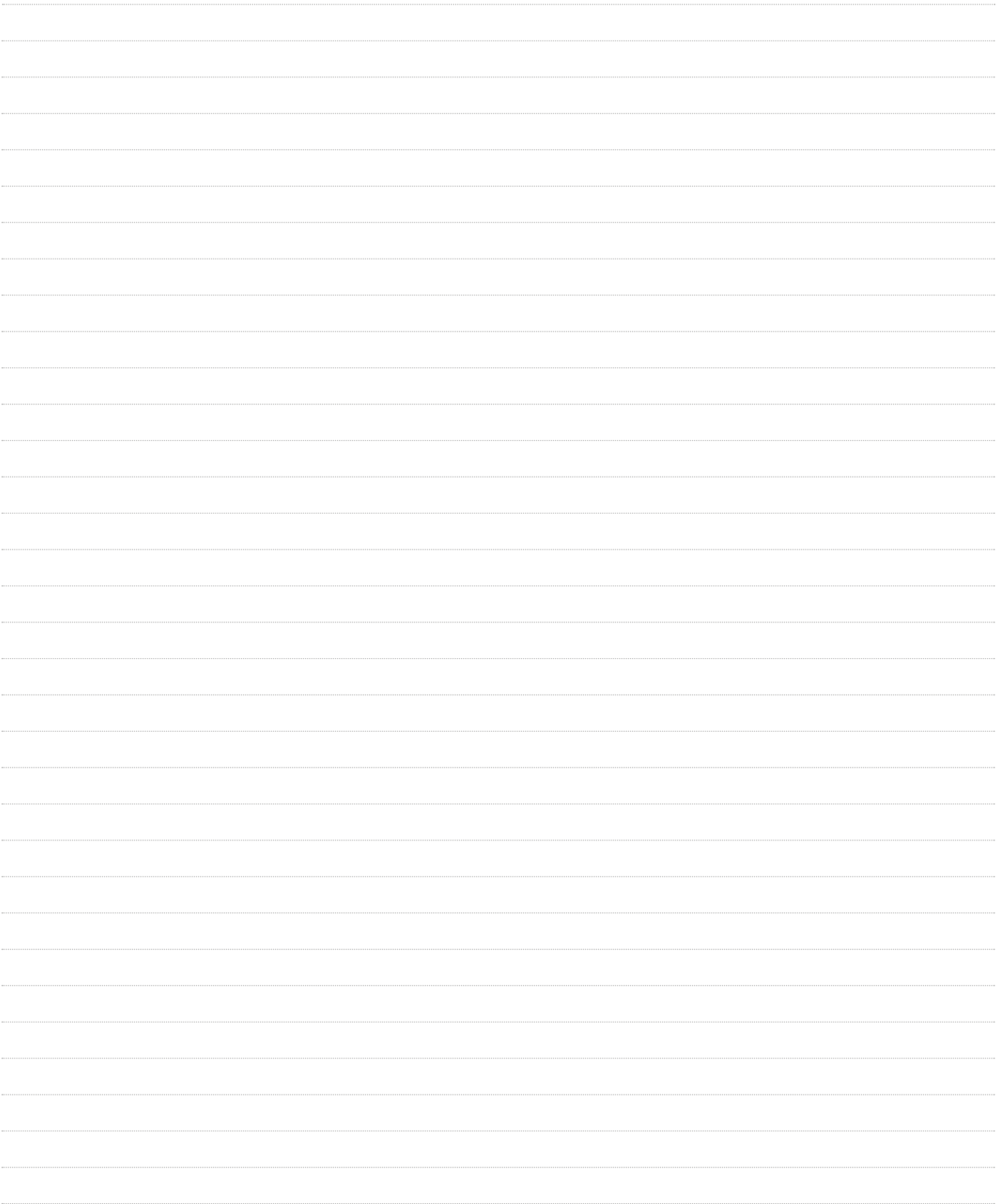The Kerramax Care Dressing continued to stay in place and wear time under compression was rated as “very good”. The level of edema continued to improve, and the patient commented that quality of life was better compared to at the start of treatment. She commented that sometimes she would remove the bandage between treatment as she found it bulky.

The wound had reduced in size, measuring 0.8cm (length) x 0.4cm (width) x 0.1cm (depth) and comprised 80% granulation tissue and 20% slough. There were low levels of thin exudate. Towards the end of the evaluation period, the patient no longer felt able to tolerate compression, and the decision was made to continue with the Kerramax Care Dressing alone.

Final comments

Treatment with the Kerramax Care Dressing and Coban 2 Compression System was described by the clinician as the ‘perfect treatment for this patient’, despite the decision by the patient to discontinue.

The clinician was pleased that compression had been tolerated for 3 weeks and that the wound had made good progress during this time (i.e. inflammation of the surrounding skin, levels of exudate and pain had reduced).





A Wounds International publication
www.woundsinternational.com