

An unexpected infection in a venous leg ulcer: a case report

Authors:

Miguel Veríssimo, Diogo Guimarães, Diogo Casal, Sara Carvalho, Miguel Matias, Raquel Barbosa and Joaquim Bexiga

Providencia rettgeri is a Gram-negative bacillus that is most usually seen in urinary tract infections. Skin and soft tissue infections with *P rettgeri* are rare and there few case reports described in the literature. A 43-year-old woman presented to the emergency department with a leg ulcer of 3 months duration. Microbiological results isolated *P rettgeri* and *Pseudomonas aeruginosa*. She underwent surgical debridement and split-thickness skin grafting alongside IV antibiotic therapy and dressing care, with complete resolution of the wound 3 months after admission. The differential diagnosis of leg ulcers is wide and must include infection and venous insufficiency. Although venous ulcers are common, typically they are not responsible for rapid evolving ulcers that destroy tissues below the muscular fascia. In this case report, the authors hypothesise that *P rettgeri* had a major role in the severity of the ulcer in an otherwise healthy woman. A greater understanding of how *P rettgeri* affects wound pathophysiology is needed in order to distinguish between colonisation versus infection and discriminate bacterial synergy, as well as having better treatment guidelines.

P*rovidencia rettgeri* is a Gram-negative bacillus that belongs to the Enterobacteriaceae family. It is commonly considered as a commensal microorganism which colonises the human gastrointestinal tract and is ubiquitous in soils, water and animal reservoirs (Washington et al, 2015; Huff and Blome-Eberwein, 2022).

There are currently five species in the genus *Providencia*: *P rettgeri*, *P stuartii*, *P alcalifaciens*, *P rustigianii* and *P heimbachae*. *P stuartii* is the most prevalent and has been associated with post-burn wound infections (Huff and Blome-Eberwein, 2022).

P rettgeri, as an opportunistic pathogen, is most usually seen in urinary tract infections (UTI; Huff and Blome-Eberwein, 2022). It was first isolated in 1904 by Rettger in a fowl cholera-like epidemic in chickens, and the first documented case of *P rettgeri* in humans was published in 1951 by Goldfarb and De Bakey, who reported an empyema-associated infection (Goldfarb and De Bakey, 1951; O'Hara et al, 2000; Washington et al, 2015). It is rarely associated with human disease, although has gained recognition in the past few years as an emerging

pathogen in urinary tract and catheter-related, bloodstream, respiratory, traveller's diarrhoea and seldom, skin and soft tissue infections (Yoh et al, 2005; Washington et al, 2015; Huff and Blome-Eberwein, 2022). Infrequently, it has also been associated with ocular infections and "Purple Bag Syndrome", in which urine becomes purple as consequence of enzymatic bacterial degradation (Al-Jubouri and Vardhan, 2001; Koreishi et al, 2006).

P rettgeri produces biofilm, being usually resistant to commonly used antibiotics like aminoglycosides, such as gentamicin and tobramycin, although it has some susceptibility to amikacin (O'Hara et al, 2000; Sapkota et al, 2021). There are also some studies that refer natural innate resistance to β -lactams due to the expression of β -lactamases, including third-generation cephalosporins (Huff and Blome-Eberwein, 2022).

There are increasing reports of multidrug resistance, including carbapenemases and extended spectrum. beta-lactamase-producing strains in epidemiological studies, although antibiotic-resistant strains were described as early as 1971 (O'Hara et al, 2000; Rosenberger et

Miguel Veríssimo is Resident. Diogo Guimarães is Resident. Diogo Casal is Attending Physician. Sara Carvalho is Attending Physician. Miguel Matias is Resident. Raquel Barbosa is Resident. Joaquim Bexiga is Attending Physician. All at Plastic Surgery Department, Centro Hospitalar Universitário Lisboa Central, Lisbon, Portugal.

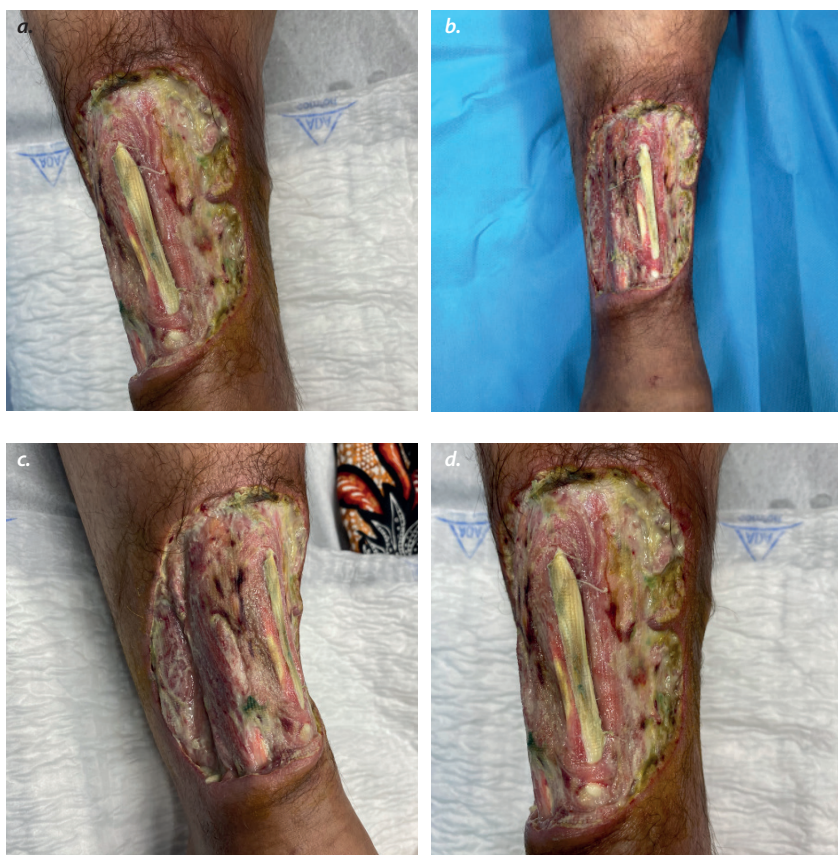

Figure 1. (A-D) Anterior, lateral and medial views of leg ulcer on hospital admission.

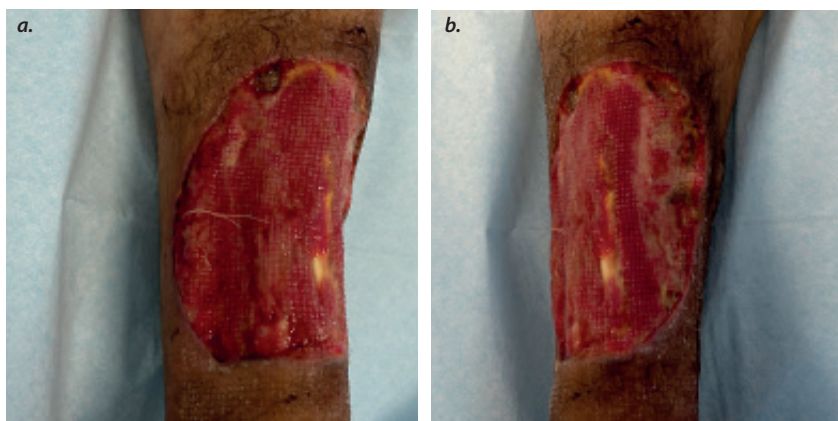


Figure 2. Anterior (a) and lateral (b) views of leg ulcer after 1 month of hospital admission and first surgery.

al, 2011; Sheng et al, 2013; Sapkota et al, 2021).

Skin and soft tissue infections with *P rettgeri* are rare and there are few studies or case reports described in the literature.

In this article, we present a clinical case of a leg ulcer of several months' duration that presented in the Emergency Department.

Case report

A 43-year-old woman from Brazil presented in the Emergency Department (ED) at a hospital in Lisbon, Portugal, complaining of a wound in the

right leg of 3 months' duration.

She reported no recent travel aboard, animal bites or other trauma. The only medical history were varicose veins in her lower limbs.

Upon physical examination, an ulcer with 15 cm × 10 cm of the anterior margin of the lower third of the right leg was objectified, with exposure of tibial crest and fibula as well as the anterior tibial tendon [Figure 1]. The arterial pulses of the limb were present and she did not perform foot dorsiflexion. She did not have any apparent sensory or other motor deficits.

According to the Clinical-Etiology-Anatomy-Pathophysiology (CEAP) classification, she had grade 1 varicose veins in the left lower limb and grade 6 varicose veins in the affected leg.

On the day she presented at ED, she was admitted and surgical wound debridement was performed. Meropenem was prophylactically initiated, and daily bandage care was started. The swabs isolated *P rettgeri* and *Pseudomonas aeruginosa*.

After the microbiological results, IV antibiotics were switched to piperacillin/tazobactam. A sample was sent to histopathology, and the wound was considered as cutaneous ulcer compatible with venous ethology due to chronic stasis.

After surgical debridement and endovenous antibiotic therapy, the ulcer had favourable evolution and formed granulation tissue [Figure 2]. Doppler ultrasound revealed insufficient saphenofemoral junction and internal saphenous vein, leading to insufficient collaterals.

One month after admission, the patient was submitted to another surgical debridement and split-thickness skin grafting to achieve soft tissue coverage.

The patient was discharged 5 days after the second surgery with good healing of the wound [Figure 3].

Discussion

There are several differential diagnoses for leg ulcers and it must include venous stasis, ischemia, malignancy, infection, neuropathy, trauma or underlying systemic disease, as immunological and rheumatological aetiologies.

Given this patient's age, the absence of comorbidities besides varicose veins and the described development of the wound, venous ethology due to chronic stasis followed by polymicrobial infection may have produced an environment where the opportunistic *P rettgeri* could proliferate. Venous leg ulcers are usually chronic manifestations of venous insufficiency

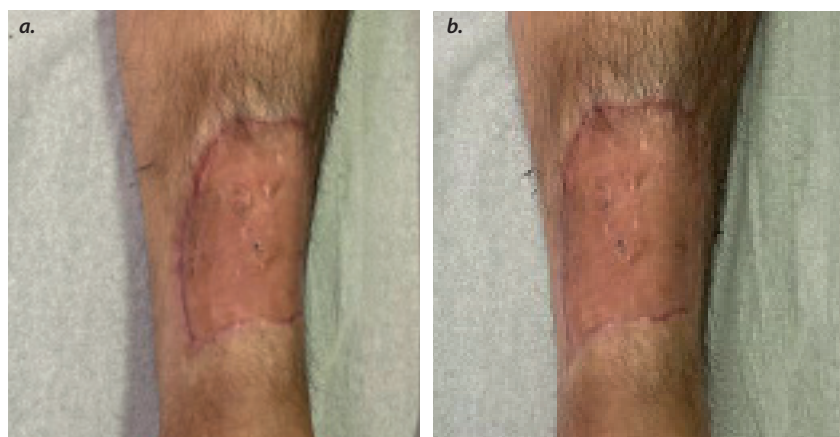


Figure 3. Anterior (a) and lateral (b) views of leg ulcer 1.5 months after split-thickness skin graft.

with delayed progression over time. In this report, this was not the case.

Providencia infections in humans are rare and are usually acquired in nosocomial settings, usually implicated in UTI, bacteraemia and catheter-associated infections. Rarely, it can be seen in wound infections.

In this case report, it is unclear where the organism was acquired and how it contributed to wound pathology, since no virulence factors have been described for *P rettgeri* (Washington et al, 2015). It is possible that it was introduced following a skin wound exposure to contaminated water or soil. *Providencia* species typically manifest as polymicrobial infections, and previous colonisation with *Pseudomonas*, isolated in microbiological results in this case, probably enhanced infection process and ulcer development, creating a favourable environment and attenuating local immune response.

P rettgeri belongs to the Enterobacteriaceae family, which represents the first World Health Organization priority classification in the list for new antibiotic needs, stressing its importance in terms of greater understanding (WHO, 2017).

Conclusion

It is important to understand how *P rettgeri* affects wound pathophysiology in order to distinguish between colonisation and infection, and to establish clinical care standard and treatment goals.

The literature regarding *P rettgeri* skin infections is limited, and to the authors' knowledge, only two other studies described the use of a split-thickness skin graft following an infection with *P rettgeri* — one in a post-burn infection and another one in a snake bite, and both reported successful outcomes (Cheong et al, 2015; Huff and Blome-Eberwein, 2022).

Conflicts of interests

The authors have no conflicts of interest to disclose.

Consent

Consent to publish was given by the patient.

References

- Al-Jubouri MA, Vardhan MS (2001) A case of purple urine bag syndrome associated with *Providencia rettgeri*. *J Clin Pathol* 54(5): 412
- Cheong CY, Lee CK, Zuki Z (2010) A rare infection following snakebite. *Malaysian Orthopaed J* 4(1): 53–5
- Goldfarb PM, De Bakey E (1951) Empyema due to *Proteus rettgeri*, report of a case with recovery. *J Med Assoc State Ala* 21(2): 33–7
- Huff ML, Blome-Eberwein S (2022) *Providencia rettgeri* infection compromising post-burn recovery: a lesson in the importance of follow-up care. *Cureus* 14(5): e25450
- Koreishi AF, Schechter BA, Karp CL (2006) Ocular infections caused by *Providencia rettgeri*. *Ophthalmology* 113(8): 1463–6
- O'Hara C.M., Brenner F.W., Miller J.M. Classification, Identification, and Clinical Significance of *Proteus*, *Providencia*, and *Morganella*. *Clinical Microbiology Reviews*, October 2000, Vol 3, No 4, 534–546
- O'Hara CM, Brenner FW, Miller JM (2000) Classification, identification, and clinical significance of *Proteus*, *Providencia*, and *Morganella*. *Clin Microbiol Rev* 13(4): 534–46
- Rosenberger LH, Hranjec T, Politano AD et al (2011) Effective cohorting and “superisolation” in a single intensive care unit in response to an outbreak of diverse multi-drug-resistant organisms. *Surg Infect (Larchmt)* 12(5): 345–50
- Sapkota S, Karn M, Regmi SM et al (2021) *Providencia rettgeri* infection complicating cranial surgery: illustrative cases. *J Neurosurg Case Lessons* 2(8): CASE21318
- Sapkota S., Karn M., Regmi S.M., Thapa S., Miya F.U., Yonghang S. *Providencia rettgeri* infection complicating cranial surgery: illustrative cases. *Journal of Neurosurgery* August 2021 Vol 2 Issue 8
- Sheng WH, Badal RE, Hsueh PR (2013) Distribution of extended-spectrum β -lactamases, AmpC β -lactamases, and carbapenemases among Enterobacteriaceae isolates causing intra-abdominal infections in the Asia-Pacific region: results of the study for Monitoring Antimicrobial Resistance Trends (SMART). *Antimicrob Agents Chemother* 57(7): 2981–8
- Washington MA, Barnhill J, Griffin JM (2015) A case of wound infection with *Providencia rettgeri* and coincident gout in a patient from Guam. *Hawaii J Med Public Health* 74(11): 375–7
- World Health Organization (2017) WHO publishes list of bacteria for which new antibiotics are urgently needed. <https://www.who.int/news/item/27-02-2017-who-publishes-list-of-bacteria-for-which-new-antibiotics-are-urgently-needed>(accessed 07.12.23)
- Yoh M, Matsuyama J, Ohnishi M et al (2005) Importance of *Providencia* species as a major cause of travellers' diarrhoea. *J Med Microbiol* 54(Pt 11): 1077–82