

DAILY IAD MONITORING

GENERAL DATA

Date

Patient ID

Nurse initials


IAD CATEGORISATION

Categorisation of IAD according to GLOBIAD

- 1A Persistent redness without clinical signs of infection
- 1B Persistent redness with clinical signs of infection
- 2A Skin loss without clinical signs of infection
- 2B Skin loss with clinical signs of infection

PERSISTENT REDNESS


Indicate the squares where you observe persistent redness



% redness

SKIN LOSS

Indicate the squares where you observe skin loss



% skin loss

OEDEMA AND MACERATION

- Oedema is present, skin feels tense or swollen at palpation
- Macerated skin

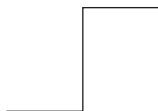
SIGNS OF INFECTION

- Satellite lesions (pustules surrounding the lesion, suggesting a *Candida albicans* fungal infection)
- White scaling of the surrounding skin (suggesting a fungal infection)
- Changes in colour in the wound bed (such as green, yellow, brown, greyish)
- Purulent exudate (pus)
- Excessive exudate level

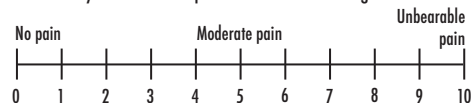
PATIENT EXPERIENCE

IAD related

- Itching
- Tingling
- Burning
- Pain



Intensity of IAD-related pain via Numerical Rating Scale



Self-report is not possible