Clinical experience using UrgoTul Ag with negative pressure wound therapy (NPWT) in management of complex wounds

Negative pressure wound therapy (NPWT) is used to manage acute, chronic and complex wounds, particularly those with substantial tissue loss where promotion of granulation tissue formation is required. However, dressing removal can present challenges as granulation tissue develops and grows into the foam or filler, commonly referred to as tissue ingrowth. Pain, bleeding and disruption of newly formed tissue may affect patient tolerance and healing progression. To mitigate tissue ingrowth, an appropriate wound contact layer can separate the wound surface from the NPWT foam or filler while maintaining negative pressure. UrgoTul Ag is a technology lipido-colloid (TLC) wound contact layer containing silver salts that provides a non-adherent wound contact layer and antimicrobial activity for wounds with signs of local infection or at risk of infection. Previous clinical experience has described its use in conjunction with NPWT.

Dr Le Phat Dat
MD, Burn and Plastic Surgery Department, Cho Ray Hospital, Ho Chi Minh City, Vietnam
Sarah Ratcliffe
Wound Consultant, West Wimmera Health Service, Victoria, Australia
Dr Manoj Johar
Principal Director and Head of Department, Department of Plastic, Aesthetic and Reconstructive Surgery, Max Super Speciality Hospital, Zone-2, Delhi-NCR, India
Dr Zhen Wang
Burn and Plastic Aesthetic and Wound Healing Department, Guangzhou First People's Hospital, Guangzhou, China
Dr Burra Viswa Chaitanya
Assistant Professor, Burns, Plastic and Reconstructive Surgery, NRI Medical College, Sangivalsa, Andhra Pradesh, India

Key words
- Negative pressure wound therapy (NPWT)
- UrgoTul Ag
- Interface dressing
- Wound healing
- Granulation tissue
- Wound contact layer

The cases in this article show wound-management challenges including fragile or newly formed tissue, discomfort during dressing changes, complex wound geometry and local wound bioburden. UrgoTul Ag was used as part of a multimodal approach in conjunction with NPWT and debridement. The cases showed progressive wound bed preparation, reduced wound dimensions and, among patients reporting pain at baseline, improvement in pain scores. These observations illustrate the potential benefits of UrgoTul Ag but do not establish causality. The findings are consistent with previous clinical experience using non-adherent lipido-colloid interfaces with NPWT.

Introduction

NPWT is used to manage acute, chronic and complex wounds, particularly those with large tissue defects, including surgical wound dehiscence, traumatic wounds, diabetic foot wounds, pressure injuries, burns, grafts and complex postoperative wounds (Guangtao and Yating, 2026). By applying controlled subatmospheric pressure, NPWT removes excess exudate, reduces oedema, promotes tissue perfusion and granulation tissue formation, and stimulates tissue regeneration (Zeng et al, 2026).

As granulation tissue develops, newly formed capillaries and extracellular matrix may extend into foam pores, making dressing removal painful and potentially causing bleeding or tissue disruption (Alhajj and Goyal, 2022). When NPWT is applied over exposed bone, tendon, vessels or orthopaedic hardware, protecting these vulnerable structures is essential (Robert, 2017). An appropriate wound contact layer between the foam or filler and wound bed can protect fragile tissue while allowing negative pressure (Gefen et al, 2022).

UrgoTul Ag is a flexible, thin lipido-colloid wound contact layer incorporating silver salts. Its matrix combines lipophilic and hydrophilic components to create a non-adherent interface to maintain a moist wound environment (Urgo, 2024). On contact with exudate, the matrix forms a gel that maintains contact with the wound while limiting adherence to newly formed tissue. The sustained release of silver ions provides broad-spectrum antimicrobial activity for wounds with signs of local infection or elevated bioburden (Urgo, 2024).

In a prospective multicentre evaluation of 66 wounds treated with NPWT using UrgoTul as the contact layer, removal of the interface/dressing combination was considered easy or very easy in 94% of cases, adherence was absent in 88%, and pain during dressing changes decreased from baseline (Téot et al, 2006). In a prospective randomised study of 38 patients with pressure ulcers, wound size decreased significantly over the treatment period in the UrgoTul group, whereas the change was not statistically significant in the NPWT-only group (Baek et al, 2020). Although these studies support using a non-adherent wound contact layer in conjunction with NPWT, their small populations and differing metHead of Departmentologies limit generalisability.

UrgoTul Ag has also been described as a protective interface during NPWT in a complex postoperative abdominal wound associated

Declarations
This article has been funded by an educational grant from Urgo Medical.

with dehiscence and enterocutaneous fistulas (Domagalska et al, 2020). This case series builds on existing experience by showing its use across clinical settings, anatomical locations and wound aetiologies, including diabetic foot ulcers, pressure injuries, burns, soft tissue infections and postoperative spinal surgical site infections (SSI). UrgoTul Ag may be used under NPWT because it provides a non-adherent wound contact layer and antimicrobial activity when clinically indicated. It is one component of multimodal wound management, which may also include NPWT, debridement, infection management, compression, offloading and other standard wound care (Urgo, 2024).

Considerations when using an interface with NPWT

Traditional NPWT involves placing polyurethane foam or gauze into the wound cavity, sealing it with an occlusive drape and applying controlled negative pressure via a tube connected to a suction device. Suction may be continuous or intermittent (Zeng et al, 2026).

Tissue ingrowth and dressing-related trauma may be exacerbated by prolonged NPWT, repeated dressing changes and wounds with irregular surfaces, undermining or exposed bone, tendon, vessels or orthopaedic hardware (Apelqvist et al, 2017; Foghetti, 2024). An appropriate interface can help protect tissue while maintaining negative pressure (Zeng et al, 2026).

Interface selection should consider adequate pressure, conformity to the wound surface and minimal adherence to the wound bed (Gefen et al, 2024; Zeng et al, 2026). Materials that are too occlusive may impair fluid transfer or pressure transmission, while adherent materials may increase trauma during dressing changes (Keenan et al, 2025). These considerations are particularly relevant for fragile, irregular or anatomically complex wounds.

Clinical case studies

The following cases show the use of UrgoTul Ag as a wound contact layer in conjunction with NPWT in complex wounds. Rather than introducing a novel NPWT technique, they provide clinical experience across wound types and settings, highlighting the potential role of a non-adherent antimicrobial interface when protecting fragile tissue.

Where sufficient data were available, changes in wound dimensions and pain scores are presented. Wound-area reductions are approximate, calculated from reported length (L) x width (W) measurements, as wounds had irregular geometry and planimetric measurements were unavailable. Patient consent was obtained for publication of all images.

Case 1. Management of a complex postoperative spinal SSI

*Author: **Dr Le Phat Dat**, MD, Burn and Plastic Surgery Department, Cho Ray Hospital, Ho Chi Minh City, Vietnam*

Patient presentation and history

A 67-year-old female presented with a non-healing surgical wound following spinal fixation surgery for L3–L4 disc herniation using plates and screws. Her recovery was complicated by a deep SSI involving the lumbar incision. Despite frequent conventional dressing changes, the wound failed to progress towards healing, and the patient reported significant pain.

Wound assessment

The wound measured 20cm (L) x 10cm (W) x 3cm (depth [D]) and showed extensive tissue destruction [Figure 1]. The wound bed comprised approximately 70% necrotic and 30% granulation tissue, with exposed tendon, muscle and spinal fixation hardware. Heavy purulent yellow exudate and a moist, erythematous periwound area indicated significant local inflammation.

Before referral, the wound was cleansed with povidone-iodine and 0.9% sodium chloride solution and dressed twice daily with povidone-iodine gauze. Pain was rated 7/10 on a numerical rating scale.

Treatment

Surgical debridement was performed to remove non-viable tissue and reduce the infection burden. NPWT was then initiated using UrgoTul Ag as the wound contact layer beneath the NPWT foam, with continuous negative pressure of 120mmHg.

UrgoTul Ag was selected to provide a non-adherent antimicrobial wound contact layer while protecting exposed structures. The wound was cleansed with 0.9% sodium chloride solution at each dressing change, which occurred weekly. UrgoTul Ag was used in conjunction with NPWT for 23 days, until complete wound closure.

Results

On day 7 [Figure 2], the wound measured 18cm (L) x 8cm (W) x 3cm (D). Necrotic tissue decreased from 70% to 30%, while granulation tissue increased to 70%. Exudate reduced from heavy to moderate pink serous, and pain decreased to 5/10.

By day 14, the wound measured 18cm (L) x 6cm (W) x 2cm (D), with granulation tissue

Case 1

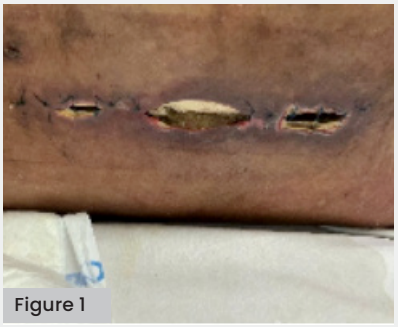
Figure 1


Figure 2


Figure 3


Figure 4

Figure 1. Postoperative lumbar SSI at presentation, showing extensive necrosis, exposed tendon, muscle and spinal fixation hardware, heavy purulent exudate and periwound erythema (20cm [L] x 10cm [W] x 3cm [D]).

Figure 2. Lumbar wound on day 7 of UrgoTul Ag and NPWT, showing reduced necrosis, increased granulation tissue and improved periwound skin (18cm [L] x 8cm [W] x 3cm [D]).

Figure 3. Lumbar wound on day 21, showing a healthy granulating wound bed, no necrotic tissue, minimal exudate and healthy surrounding skin (17cm [L] x 5cm [W] x 1.5cm [D]).

Figure 4. Definitive wound closure on day 23 following wound bed preparation with UrgoTul Ag and NPWT.

covering 90% of the wound bed. Periwound inflammation had further resolved, exudate remained moderate, and pain decreased to 4/10.

By day 21 [Figure 3], the wound measured 17cm (L) x 5cm (W) x 1.5cm (D), with a healthy granulating bed and no remaining necrotic tissue. This represented an approximate 58% reduction in wound area from baseline (calculated using length x width). Periwound erythema had resolved, exudate was minimal, and pain decreased to 3/10. Complete wound closure was achieved by day 23, following successful control of the local infection, concluding NPWT [Figure 4].

UrgoTul Ag was easy to position beneath the foam or filler, and conformed to the complex wound geometry. Dressing removal caused no clinically observed disruption of granulation tissue or bleeding. These outcomes occurred alongside debridement, cleansing and NPWT, and cannot be attributed to UrgoTul Ag alone.

Conclusion

This case shows the management of a complex postoperative spinal SSI with exposed tendon, muscle and orthopaedic hardware. UrgoTul Ag used alongside debridement, NPWT and wound cleansing was associated with an approximately 58% reduction in wound area by day 21, progressive granulation tissue formation, reduced exudate and improved pain (7/10 to 3/10). Wound closure was achieved on day 23. The case provides further clinical experience of a non-adherent antimicrobial interface in a postoperative wound containing exposed hardware.

Case 2. Management of a complex diabetic foot wound

*Author: **Sarah Ratcliffe**, Wound Consultant, West Wimmera Health Service, Victoria, Australia*

Patient presentation and history

A 75-year-old female was referred following deterioration of a chronic diabetes-related foot ulcer. Her medical history included type 2 diabetes mellitus, acute kidney injury, atrial fibrillation, peripheral vascular disease and obesity. She was admitted with methicillin-resistant *Staphylococcus aureus* (MRSA) sepsis and commenced on intravenous antibiotics.

Wound assessment

Before surgical debridement, the extensive wound measured 60mm (L) x 35mm (W) x 20mm (D) and had exposed bone and surrounding tissue undermining [Figure 5]. Initial management involved cleansing with wound irrigation solution and applying a silver dressing beneath gauze filler NPWT. Maintaining an adequate seal was difficult because of the wound's location on the foot, resulting in alarms and inconsistent NPWT delivery.

Conservative sharp debridement revealed poor tissue perfusion and limited bleeding, raising concerns about vascular status. Given the severe peripheral vascular compromise and tissue loss, possible lower-limb amputation was discussed.

Treatment

The regimen was modified to include UrgoTul Ag between the wound bed and foam filler, following cleansing with wound irrigation solution. Dressing changes occurred three times weekly, with conservative sharp debridement as clinically indicated.

UrgoTul Ag was selected to provide a conformable antimicrobial contact layer between the wound bed and NPWT foam, to protect exposed structures, minimise dressing adherence and support granulation tissue formation while maintaining effective negative pressure.

The patient remained an inpatient during the initial treatment period [Figures 6–7]. NPWT with UrgoTul Ag continued from day 1 to day 54. Following discharge on day 39, treatment continued in the community, although social circumstances affected attendance at dressing appointments. The wound continued to demonstrate granulation and contraction during community management on day 45 [Figure 8]. The patient was readmitted on day 51. On day 54, the interface was changed to UrgoStart contact layer while NPWT continued. NPWT was discontinued on day 59, and care continued with UrgoStart contact layer, absorbent secondary dressings, compression bandaging and fortnightly debridement.

Results

By day 24, healthy granulation tissue had developed along the wound edges, with progressive improvement in tissue quality [Figure 7]. By day 62, the wound measured 60mm (L) x 20mm (W) x 5mm (D), indicating reduced width and depth with unchanged length.

Dressing changes were well tolerated, with no significant discomfort reported during removal or reapplication. UrgoTul Ag remained non-adherent, allowing removal without clinically observed disruption of newly formed granulation tissue. Although maintaining an effective seal remained challenging, the flexible contact layer could be positioned around exposed bone and undermined areas. The treating clinician found UrgoTul Ag easier to apply than the previous silver dressing, with less concern about contact with surrounding skin.

Improvement occurred during multimodal treatment involving NPWT, debridement, antimicrobial management and subsequent standard wound care. The independent contribution of UrgoTul Ag cannot be established. Following NPWT discontinuation, healing continued with UrgoStart contact layer until the patient was transferred to another healthcare service on day 87 [Figure 9].

Conclusion

This case shows the challenges of managing a complex diabetes-related foot ulcer requiring prolonged NPWT in the presence of peripheral vascular disease, exposed bone, MRSA sepsis and an anatomically difficult wound location. UrgoTul Ag used in conjunction with NPWT, debridement and antimicrobial therapy was associated with progressive improvement in wound-bed quality and granulation tissue formation. Wound measurements at day 62 showed reduced width (35mm to 20mm) and depth (20mm to 5mm), with wound length remaining stable. The treating clinician considered the flexible, non-adherent interface useful around exposed bone and undermined areas.

Case 2


Figure 5


Figure 6

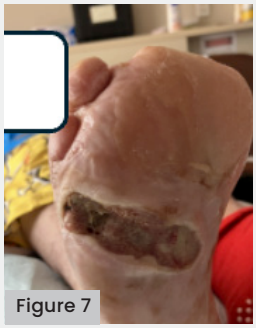
Figure 7


Figure 8

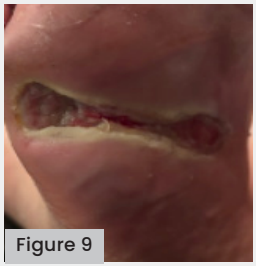
Figure 9

Figure 5. Diabetic foot wound before surgical debridement, showing exposed bone and surrounding undermining tissue (60mm [L] x 35mm [W] x 20mm [D]).

Figure 6. Diabetic foot wound on day 3 of UrgoTul Ag and NPWT, following conservative sharp debridement.

Figure 7. Diabetic foot wound on day 24, showing progressive granulation and improved wound edge viability.

Figure 8. Diabetic foot wound on day 45 during community management, showing continued granulation and wound contraction.

Figure 9. Diabetic foot wound on day 87 before transfer to another healthcare service, showing continued progression with UrgoStart contact layer.

Case 3. Management of necrotising soft tissue infection in a paediatric patient

*Authors: **Dr Manoj Johar**, Principal Director and Head of Department, Department of Plastic, Aesthetic and Reconstructive Surgery, Max Super Speciality Hospital, Zone-2, Delhi-NCR; **Dr Kamlesh Kumar**, Senior Consultant, Department of Plastic Surgery, Max Super Speciality Hospital, Delhi-NCR, India*

Patient presentation and history

A three-year-old girl with acute lymphoblastic leukaemia (ALL) developed blisters following an idiopathic insect bite on the right lower limb, progressing to cellulitis, myonecrosis and septic shock [Figure 10].

Wound assessment

The wound measured approximately 30cm (L) x 28cm (circumference [C]) following surgical management and involved extensive soft tissue damage. Examination under anaesthesia

and surgical debridement were performed to remove non-viable tissue [Figures 10–11].

Treatment

Following debridement, UrgoTul Ag was applied as the primary wound contact layer beneath NPWT [Figure 12]. It was selected to provide a non-adherent wound contact layer, facilitate atraumatic dressing removal and maintain effective negative pressure delivery.

Dressings were changed every five days. An antimicrobial cleanser was used for initial cleansing, followed by normal saline at subsequent changes. NPWT and UrgoTul Ag were continued following serial wound assessments, with progress monitored to determine readiness for reconstruction.

Results

At the first dressing change on day 5, early granulation tissue was visible in some areas [Figure 13], and NPWT was reapplied. By day 10, significant granulation tissue formation was evident across multiple areas [Figure 14], and the wound bed was suitable for application of a Biodegradable temporising matrix (BTM).

The treating clinician reported rapid granulation tissue development during NPWT with UrgoTul Ag, with atraumatic and pain-free dressing removal. The interface maintained a protective layer between the wound bed and NPWT foam or filler.

Conclusion

This case shows the management of severe soft tissue infection in a paediatric patient with ALL, cellulitis, myonecrosis and septic shock. Following debridement, UrgoTul Ag beneath NPWT was associated with progressive granulation tissue formation and wound-bed preparation for BTM application. Wound dimensions remained stable at approximately 30cm (L) x 28cm (C) during the reported 10-day period. Dressing changes were reported to be atraumatic and pain-free. The findings provide longitudinal clinical observations of UrgoTul Ag as a useful adjunct to prolonged NPWT.

Case 3


Figure 10


Figure 11


Figure 12


Figure 13


Figure 14

Figure 10. Initial blister following an idiopathic insect bite to the right leg.

Figure 11. Wound following surgical debridement under anaesthesia on day 0 (approximately 30cm [L] x 28cm [C]).

Figure 12. UrgoTul Ag applied beneath NPWT immediately after debridement.

Figure 13. Wound on day 5 of UrgoTul Ag and NPWT, showing early granulation.

Figure 14. Wound on day 10, showing significant granulation before BTM application (approximately 30cm [L] x 28cm [C]).

Case 4. Management of a stage 4 sacrococcygeal pressure injury

*Author: **Dr Zhen Wang**, Burn and Plastic Aesthetic and Wound Healing Department, Guangzhou First People's Hospital, Guangzhou, China*

Patient presentation and history

An 87-year-old female with diabetes mellitus developed a severe sacrococcygeal pressure injury following prolonged immobility after a cerebrovascular accident. Two weeks before admission, extensive black discolouration developed, and her family managed the wound with iodophor. Three days before presentation, the wound deteriorated, with ulceration, copious exudate and malodour. Fever and confusion developed the day before admission.

Wound assessment

The stage 4 pressure injury measured 20cm (L) x 18cm (W) [Figure 15]. The wound bed contained black and grey necrotic tissue, exposed sacrococcygeal bone and necrotic exposed tendons, with a small amount of oedematous, aged granulation tissue around the margins. The periwound skin was dull, with hyperpigmentation. Copious exudate and malodour indicated severe local infection. Pain was rated 8/10.

Before admission, dressings were changed every three to five days using iodophor for cleansing.

Treatment

Bedside sharp debridement was performed to remove devitalised tissue and reduce the infection burden. Continuous NPWT was initiated with UrgoTul Ag beneath the foam as a non-adherent antimicrobial wound contact layer to

limit direct contact with exposed structures.

The wound was cleansed with iodophor at each dressing change, which occurred every five days. Further bedside debridement removed residual necrotic tendon and detached bone fragments while preserving newly formed granulation tissue.

Results

By day 30 [Figure 16], the wound measured 18cm (L) x 18cm (W), representing an approximately 10% reduction in estimated area based on length x width. Necrotic tissue had decreased, healthy bright red granulation tissue covered most of the wound bed, and epithelialisation was evident at the margins. Periwound erythema and oedema were absent, exudate had reduced to a moderate amount, and pain decreased to 4/10.

By day 58 [Figure 17], the wound measured 12cm (L) x 10cm (W), representing an approximately 67% reduction in estimated area from baseline. Healthy granulation tissue predominated, previously exposed bone was covered, and no exposed necrotic tendon remained visible. The wound had contracted, periwound skin remained free from erythema and swelling, exudate was minimal, and pain decreased to 3/10.

UrgoTul Ag remained easy to position beneath the NPWT foam or filler, and conformed to the irregular wound surface. Dressing removal caused no clinically observed disruption of granulation tissue or bleeding. These outcomes occurred alongside debridement, cleansing and NPWT, and cannot be attributed to UrgoTul Ag alone.

Conclusion

This case shows the management of a large stage 4 sacrococcygeal pressure injury with exposed bone and tendon, local bioburden and severe pain. UrgoTul Ag used alongside continuous NPWT, repeated debridement and cleansing was associated with an approximately 67% reduction in estimated wound area over 58 days (from 20cm [L] x 18cm [W] at baseline to 12cm [L] x 10cm [W] at day 58), reduced necrotic tissue and exudate, progressive granulation tissue formation and improved pain (8/10 to 3/10). At day 30, estimated wound area had reduced by approximately 10%, with further contraction and coverage of previously exposed bone evident by day 58. The findings provide longitudinal clinical observations of a non-adherent wound contact layer used during prolonged NPWT.

Case 5. Management of a complex scalp burn

Author: **Dr Burra Viswa Chaitanya**, *Assistant Professor, Burns, Plastic and Reconstructive Surgery, NRI Medical College, Sangivalsa, Andhra Pradesh, India*

Case 4


Figure 15


Figure 16

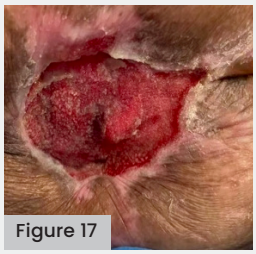
Figure 17

Figure 15. Stage 4 sacrococcygeal pressure injury at presentation, showing extensive necrosis, exposed bone and necrotic tendons, copious exudate and periwound hyperpigmentation (20cm [L] x 18cm [W]).

Figure 16. Pressure injury on day 30 of UrgoTul Ag and NPWT, showing reduced necrosis, healthy granulation and advancing epithelialisation, with residual exposed bone and tendon (18cm [L] x 18cm [W]).

Figure 17. Pressure injury on day 58, showing substantial wound contraction, granulation over previously exposed bone, no exposed necrotic tendon and minimal exudate (12cm [L] x 10cm [W]).

Patient presentation and history

A 31-year-old male presented with 21% total body surface area electrical burns involving the scalp, face and both lower limbs. Injuries included deep partial- and full-thickness burns, with a third-degree scalp burn. Initial management involved tangential excision of the scalp burn, followed by daily cleansing using povidone-iodine and saline.

Wound assessment

The scalp wound showed extensive tissue damage from the full-thickness burn. On post-burn day 5, debridement was performed to remove eschar and slough, and prepare the wound bed for reconstruction [Figures 18–19].

Treatment

On post-burn day 27, a second surgical procedure involving outer table excision of the skull was performed [Figure 20]. UrgoTul Ag was applied directly to the wound bed as the primary contact layer, followed by NPWT [Figure 21]. UrgoTul Ag remained beneath NPWT for seven days (post-burn days 27-34) and was selected to minimise adherence of the foam or filler to exposed structures while allowing negative pressure delivery.

Following NPWT, the wound had developed sufficient granulation tissue for reconstruction. Split-thickness skin grafting (SSG) was performed on post-burn day 35, and UrgoTul Ag was reapplied as a protective dressing over the graft [Figure 22].

Results

Healthy granulation tissue developed during the seven-day NPWT period, facilitating SSG on post-burn day 35. The treating clinician reported atraumatic, pain-free dressing removal, and

Case 5


Figure 18


Figure 19


Figure 20


Figure 21


Figure 22


Figure 23

Figure 18. Full-thickness scalp burn before surgical debridement.

Figure 19. Scalp wound following tangential excision and debridement on post-burn day 5, showing removal of eschar and slough.

Figure 20. Scalp wound following outer table excision of the skull on post-burn day 27.

Figure 21. UrgoTul Ag applied beneath NPWT following outer table excision on post-burn day 27.

Figure 22. Scalp wound following split-thickness skin grafting on post-burn day 35, with UrgoTul Ag reapplied as a protective dressing.

Figure 23. Scalp wound on post-burn day 50, showing successful graft take and continued healing progression.

prevention of foam or filler adherence to the wound surface.

UrgoTul Ag was continued following grafting as part of postoperative wound management, with its antimicrobial properties considered beneficial for infection prevention. By post-burn day 50, successful graft take and continued improvement in wound appearance were observed [Figure 23].

Conclusion

This case shows the management of a complex full-thickness scalp burn requiring serial surgical intervention, NPWT and skin graft reconstruction. UrgoTul Ag beneath NPWT was associated with healthy granulation tissue formation, supporting successful SSG on post-burn day 35, following seven days of NPWT. The treating clinician reported atraumatic dressing removal without foam or filler adherence. Continued use after grafting formed part of the overall wound management strategy, alongside progressive healing through post-burn day 50.

Discussion

The five cases provide further clinical experience with UrgoTul Ag as a wound contact layer during NPWT across different complex wounds and clinical settings. This approach has previously been described. A prospective multicentre evaluation of UrgoTul beneath topical negative pressure reported favourable ease of removal, low wound adherence and reduced pain during dressing changes in 66 acute and chronic wounds (Mouës et al, 2007). A prospective randomised study of 38 patients with pressure ulcers reported greater wound-size reduction with UrgoTul and NPWT than with NPWT alone (Baek et al, 2020). UrgoTul Ag has also been described as an interface during NPWT in a complex postoperative wound with dehiscence and enterocutaneous fistulas (Domagalska et al, 2020). The present series extends this clinical experience.

The cases show practical challenges that a wound contact layer may help address, including protection of fragile or newly formed tissue, dressing changes, complex wound geometry and exposed anatomical structures. These considerations are particularly relevant when bone, tendon or orthopaedic hardware is exposed and direct contact with NPWT foam or filler may complicate dressing management (Urgo, 2024).

Across the cases, UrgoTul Ag was associated with progressive improvement in wound-bed quality and granulation tissue formation when used in conjunction with NPWT. However, treatment also included interventions such as surgical or conservative sharp debridement, antimicrobial therapy, wound cleansing, compression and subsequent standard wound care. The contribution of individual components cannot be separated; therefore, these findings represent observations from multimodal treatment rather than evidence of an independent treatment effect.

The antimicrobial properties of UrgoTul Ag may be relevant in wounds with signs of local infection or elevated bioburden. Its TLC matrix provides a non-adherent interface that helps maintain a moist wound environment and protect newly formed tissue during dressing changes. In these cases, infection and bioburden were managed as part of broader clinical treatment, with improvement occurring alongside NPWT, debridement and antimicrobial management (Aisa and Parlier, 2022; Urgo, 2024). These observations do not establish that UrgoTul Ag independently controlled infection.

The cases included several objective clinical outcomes. In Case 1, estimated wound area decreased by approximately 58% by day 21, pain improved from 7/10 to 3/10, and wound closure was achieved by day 23. In Case 2, serial quantitative wound measurements showed a reduction in wound width. Dressing

changes were well tolerated and progressive granulation tissue formation was observed during treatment.

In Case 3, early granulation tissue was observed by day 5, with substantial development by day 10, allowing application of a BTM. In Case 4, estimated wound area decreased by approximately 67% by day 58, while pain improved from 8/10 to 3/10. In Case 5, granulation tissue developed following seven days of NPWT with UrgoTul Ag, supporting split-thickness skin grafting on post-burn day 35, with further healing reported by day 50. These outcomes provide clinical context but were not collected using a standardised prospective protocol and should not be interpreted as comparative measures of effectiveness.

A strength of this series is the diversity of wound types and clinical circumstances, including a postoperative spinal SSI with exposed orthopaedic hardware, a complex diabetic foot wound with peripheral vascular disease and MRSA sepsis, a severe paediatric soft tissue infection, a stage 4 pressure injury with exposed bone and tendon, and a full-thickness scalp burn requiring skull surgery and skin grafting. This diversity shows the practical circumstances in which a wound contact layer may be considered during NPWT, although it limits direct comparison between cases.

The main limitations are the small number of heterogeneous wounds, absence of a comparator group and retrospective, descriptive design. Variation in wound characteristics and treatment regimens, incomplete serial wound measurements and inconsistent reporting of dressing use further limit interpretation. The series cannot establish causality or determine the contribution of UrgoTul Ag relative to NPWT, debridement, antimicrobial treatment, compression or other wound-care interventions.

Overall, this series complements existing evidence by describing the practical use of a non-adherent antimicrobial wound contact layer during NPWT across different wound types, anatomical sites and care settings. Prospective comparative studies using standardised outcomes, including percentage wound-area reduction, time to NPWT discontinuation or wound closure, dressing-change frequency, validated pain scores and adverse events, are needed to further define its clinical value.

Conclusion

Appropriate wound contact layer selection is an important consideration during NPWT. Across these five cases, UrgoTul Ag was used in complex wounds, including those with exposed bone, tendon and orthopaedic hardware. Its use alongside NPWT and other wound-care interventions was associated with progressive granulation tissue formation, improved wound-bed quality and, where reported, reduced wound dimensions and pain. Dressing removal was also reported to be well tolerated in several cases.

These findings extend previous clinical experience with UrgoTul and UrgoTul Ag during NPWT but do not establish an independent treatment effect. The small, heterogeneous case series and absence of a comparator limit conclusions regarding effectiveness. Further prospective comparative studies using standardised objective outcome measures are warranted to clarify the contribution of wound contact layers during NPWT and their potential impact on wound progression and patient comfort.

References

Aisa J and Parlier M (2022) Local wound management: A review of modern techniques and products. *Vet Dermatol* 33(5): 463-78

Alhajj M and Goyal A (2022) Physiology, granulation tissue. In StatPearls [Internet]. StatPearls Publishing

Apelqvist J, Willy C, Fagerdahl AM et al (2017) EWMA document: negative pressure wound therapy: overview, challenges and perspectives. *J Wound Care* 26(Sup3): S1-154

Baek W, Lee N, Han EJ et al (2020) A prospective randomized study: the usefulness and efficacy of negative pressure wound therapy with lipido-colloid polyester mesh compared to traditional negative pressure wound therapy for treatment of pressure ulcers. *Pharmaceutics* 12(9): 813

Domagalska D, Bobkiewicz A, Banasiewicz T et al (2020) UrgoTul® Ag/Silver dressing as an intermediate layer in negative pressure wound therapy in patient with unhealing wound after laparotomies. *Leczenie Ran* 17(3): 147-50

Foghetti D (2024) Surgical Wounds: Principles of Postoperative Care. In Infections in Surgery: Prevention and Management. Cham: Springer Nature Switzerland. 133-41

Gefen A, Alves P, Beeckman D et al (2022) Mechanical and contact characteristics of foam materials within wound dressings: Theoretical and practical considerations in treatment. *Int Wound J* 20(6): 1960-78

Gefen A, Alves P, Beeckman D et al (2024) How should clinical wound care and management translate to effective engineering standard testing requirements from foam dressings? Mapping the existing gaps and needs. *Adv Wound Care* 13(1): 34-52

Guangtao H and Yating W (2026) Consensus guidelines on negative pressure wound therapy for wound repair (2025 version). *Regen Repair Rehab* 2(1): 73-9

Keenan C, Obaidi N, Neelon J et al (2025) Negative pressure wound therapy: challenges, novel techniques, and future perspectives. *Adv Wound Care* 14(1): 33-47

Mouës CM, Van den Bemd GJCM, Heule F et al (2007) Comparing conventional gauze therapy to vacuum-assisted closure wound therapy: a prospective randomised trial. *J Plast Reconstr Aesthet Surg* 60(6): 672-81

Robert N (2017) Negative pressure wound therapy in orthopaedic surgery. *Orthop Traumatol Surg Res* 103(1): S99-103

Téot L, Lambert L, Ourabah Z et al (2006) Use of topical negative pressure with a lipido-colloid dressing: results of a clinical evaluation. *J Wound Care* 15(8): 355-8

Urgo (2024) UrgoTul Ag. Available at: UrgoTul Ag | Urgo Medical

Zeng Y, Tu J and Qin J (2026) The mechanism by which negative pressure wound therapy promotes wound healing. *J Tissue Viability* 100982