

Challenging wounds, improving outcomes

**Treatment of complex
diabetic foot wounds using
topical oxygen therapy**

FOREWORD

The essential role of oxygen in wound healing is well documented, and recent developments in the delivery of topical oxygen therapy has made this a more viable treatment in practice (Harding, 2016).

Diabetic foot ulcers (DFUs) are a significant and growing problem, compounded by lack of resources in general wound care, making this a challenging area of practice (Chadwick and Armstrong, 2017). The aim of this document is to inform practitioners of the potential benefits of using topical oxygen therapy to improve outcomes in patients with complex diabetic foot wounds. Evidence provided in this document suggests that topical oxygen therapy can improve the patient experience and reduce the economic burden associated with DFUs.

EXPERT PANEL

The group of clinical experts involved in the development of this document included:

- Hanna Kaufman
- Joanne McCardle
- Nia J. Jones

PUBLISHED BY:

Wounds International,
Ground Floor, 108 Cannon Street, London EC4N 6EU, UK
Tel: + 44 (0)20 3735 8244
info@woundsinternational.com
www.woundsinternational.com

© **Wounds International 2018**

To cite this document:

Challenging wounds, improving outcomes: Treatment of complex diabetic foot wounds using topical oxygen therapy. *Wounds International*, 2018.

Available from: www.woundsinternational.com

This document has been developed by Wounds International and supported by Inotec AMD Ltd

The views expressed are those of the authors and do not necessarily reflect those of Inotec AMD Ltd

SETTING THE SCENE FOR THE DIABETIC FOOT

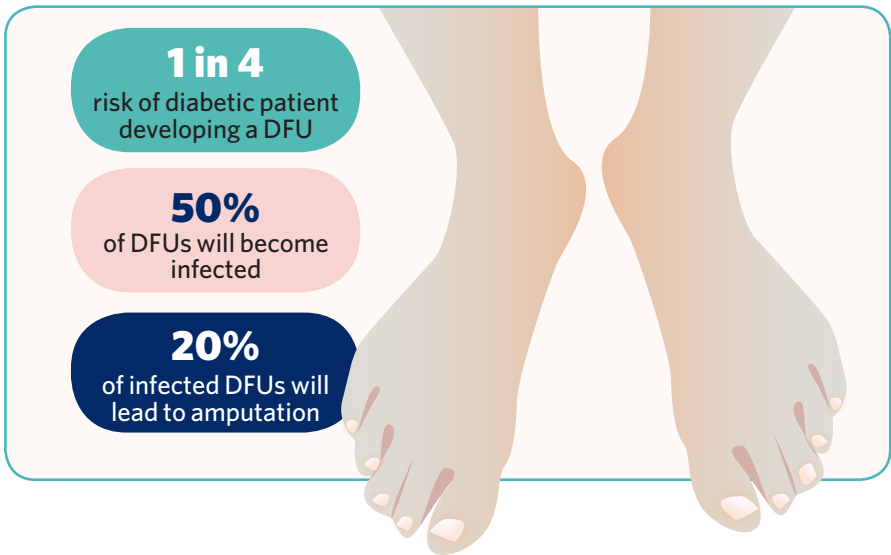
It is estimated that 422 million (8.5%) of the world's adult population has diabetes (WHO, 2016), and these patients have a one-in-four risk of developing a DFU over their lifetime (Armstrong et al, 2017).

All DFUs are complex wounds from onset, as they are a marker of serious disease and comorbidities. They have a major long-term health impact on patients' morbidity and mortality (Jupiter et al, 2016). Diabetic foot ulceration also represents a significant quality of life issue for patients, for example through reduced mobility, loss of independence, and multiple clinic visits. Many patients with DFUs report pain levels that affect daily activities and disrupt sleep (Bradbury and Price, 2011).

The risk of recurrence is high: a patient with a healed DFU has a 17–60% risk of another DFU occurring within the following 3 years (Armstrong et al, 2017).

Diabetic foot wounds are costly to treat and frequently involve risk of increased complications, such as infection, delayed healing and amputation. Around 50% of DFUs become infected, and in approximately 20% of these patients, infection will lead to amputation (Wu et al, 2007). Half of patients with a DFU who undergo amputation will die within the following 5 years (Brennan et al, 2017).

As well as representing a huge issue for both patient and practitioner, in terms of cost and resource utilisation, DFUs are at least equivalent to other major chronic diseases such as heart disease, stroke, and cancer (Skrepnek et al, 2017).




COST IMPLICATIONS

The Burden of Wounds study demonstrated high and increasing costs: the overall cost for wound care in the UK is estimated at £4.5–5.1 billion (Guest et al, 2015).

Diabetic foot wounds and their associated complications are particularly expensive to treat and costs are rising. The costs associated with diabetes in the US and in Europe respectively are increasing by approximately US\$9–13 billion and up to €10 billion per year (Prompers et al, 2008; Rice et al, 2014).

The increasing socio-economic burden of delivering gold standard care in the treatment of DFUs is becoming a global challenge. While financial and practical issues need to be considered, patient related outcomes must still be top priority.

Value-based health care is key – providing the best outcomes with the resources available. The principle aim is not to save money, but to achieve the best results for the individual patient. It is important to remember the wider perspective – the focus should be on optimising healing and minimising the risk of costly complications where possible.



UK wound care spend (Guest et al, 2015)

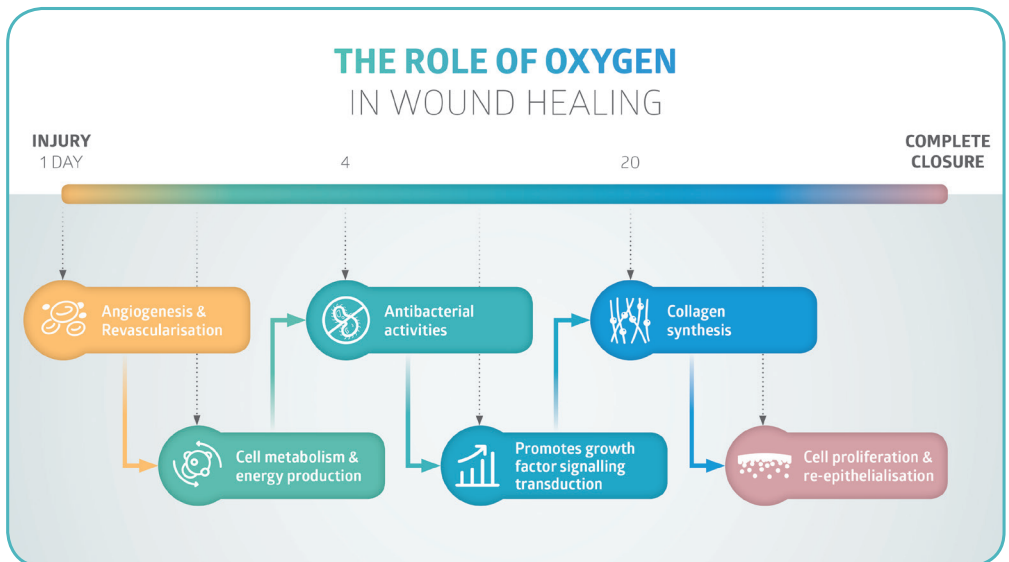
THE ROLE OF OXYGEN

Oxygen is critical to wound healing (Wounds UK, 2017). Transcutaneous oxygen measurement ($TcPO_2$) can be used to predict the likelihood of healing and the risk of amputation in DFUs: the amount of tissue oxygen is positively correlated with the likelihood of healing (Wang et al, 2016).

Patients with diabetes are twice as likely to have peripheral arterial disease (PAD) as those without diabetes (Wounds International, 2013). This has a significant impact on the outcomes of DFU treatment and is associated with the most severe adverse outcomes, including:

- Lower probability of healing
- Longer healing times
- Higher probability of recurrence
- Greater risk of toe as well as major amputations
- Potentially higher mortality (Armstrong et al, 2011).

However, many patients with DFUs are not good candidates for revascularisation surgery due to complications arising from comorbidities, late presentation, or chronic ischemia associated with irreversible tissue injury (Yu et al, 2016). Emerging evidence suggests that topical oxygen therapy may provide novel solutions to some of these wound healing challenges (Harding, 2016; Yu et al, 2016).



The role of oxygen in wound healing

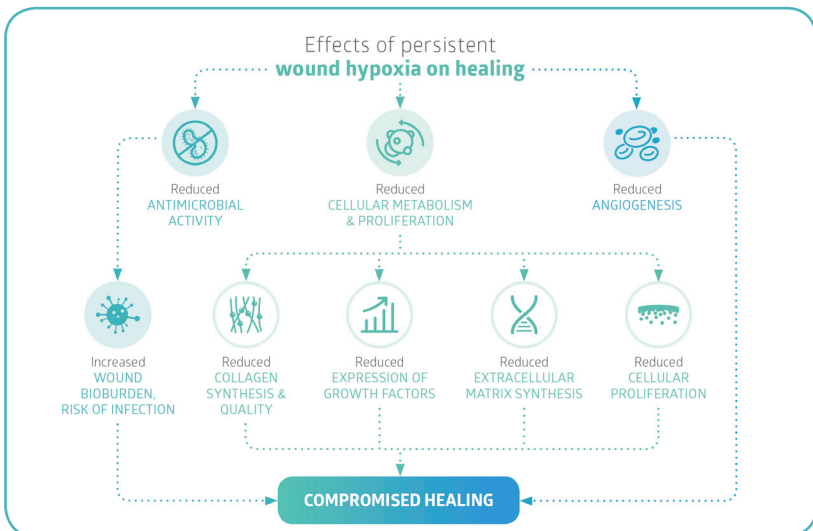
MANAGING CHALLENGING WOUNDS

A critical lack of oxygen to the wound can cause a range of issues from hypoxia to delayed healing which can be further compounded by an increased susceptibility to infection.

Diabetic foot ulcers are particularly high risk of developing these lower limb-threatening complications, and given the burden of disease there is a need to cultivate new innovative therapies to improve the delivery of topical oxygen direct to the wound bed (Wounds UK, 2017).

TABLE 1: Effects of persistent hypoxia on wound healing (Wounds UK, 2017)

Effect of persistent hypoxia	Impact on wound healing
Reduced oxygen availability for cell metabolism	<ul style="list-style-type: none"> Impairs the ability of cells to generate energy and so may reduce synthesis of proteins, DNA, RNA and cell components
Reduced fibroblast proliferation	<ul style="list-style-type: none"> Fewer fibroblasts results in lower collagen production Hypoxia may also impair differentiation of fibroblasts into myofibroblasts, which are important for wound contraction
Reduced synthesis of collagen	<ul style="list-style-type: none"> Synthesis, cross-linking, tensile strength and maturation of collagen are impaired when oxygen levels are reduced, resulting in delayed healing and reduced scar strength
Reduced antimicrobial activity	<ul style="list-style-type: none"> Low oxygen levels impair the ability of immune cells to generate the reactive oxygen species used to prevent bacterial colonisation of wound infection Bacterial growth may use oxygen and worsen hypoxia
Reduced angiogenesis	<ul style="list-style-type: none"> Delivery of nutrients and oxygen to wound tissues is limited
Perpetuation of inflammation	<ul style="list-style-type: none"> Excessive protease production may occur that delays healing by degrading extracellular matrix and growth factors

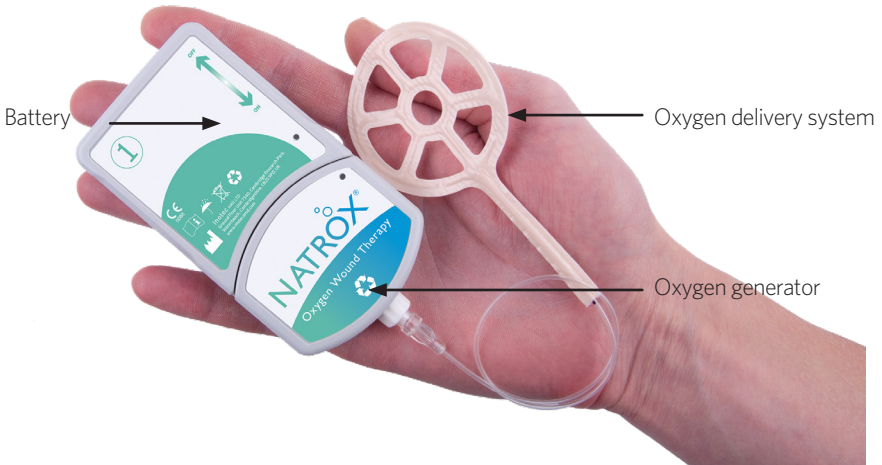


INTRODUCING NATROX®

NATROX® Oxygen Wound Therapy (Inotec AMD Ltd) is an innovative, simple and lightweight device that has been clinically proven to deliver 98% pure humidified oxygen direct to the wound bed.

This device provides an active therapy which can be maintained 24 hours a day, 7 days a week until the wound achieves complete re-epithelialisation. It is battery-operated, portable, discreet and silent, which enables the patient to continue with their daily activities with minimal disruption.

The burden of living with a chronic wound on a patient's quality of life has been well established in the literature (WHO, 2016). However, findings from a recent DFU study reported that patients rated the acceptability of NATROX® Oxygen Wound Therapy as 9.9/10 (Inotec AMD Ltd, data on file).



Clinical evidence generated in challenging and non-healing wounds showed that NATROX had a positive effect upon healing:

- After 8 weeks of treatment, 30% of the control group healed, whilst 90% healed in the NATROX arm (Yu et al, 2016)
- 57% DFUs and arterial ulcers completely healed after >25 days of treatment (Kaufman, 2016)
- 53% reduction after 8 weeks of treatment, with 7/10 DFUs on healing trajectory (Hayes et al, 2015)
- A case study showed that a patient's wound achieved full re-epithelialisation within 10 weeks, after 10 months of non-healing with optimal standard care: the estimated cost savings of NATROX therapy, compared to previous treatment, was in the region of £3,707 (Jones et al, 2016).

NON-HEALING FOR 120 DAYS HEALED IN 56 DAYS

Case 1

Hanna Kaufman

This was a 57-year-old patient with a 4-month history of a non-healing diabetic foot ulcer to the fifth metatarsal head. The patient had been treated initially with advanced wound dressings and off-loading; concordance was not an issue. During this time, regular debridement was carried out; however, the wound failed to progress as expected. Due to the lack of progression, NATROX was initiated. At this time the wound measured approximately 2 cm x 1.8 cm with significant callus around the periwound skin. There were no clinical signs of infection and off-loading was maintained. Dressing changes were carried out twice weekly, and the NATROX ODS was also changed at this time.

Result:

Following 56 days of therapy, complete wound closure was achieved. During therapy, the need for debridement was significantly reduced and the peri-wound skin improved in condition. The patient found charging and changing the battery extremely easy and the device allowed him to be relatively mobile. He liked the fact it did not interfere with his normal sleep pattern or activities of daily living.

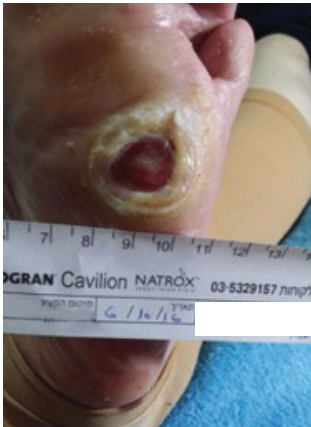

Figure 1: The wound on presentation

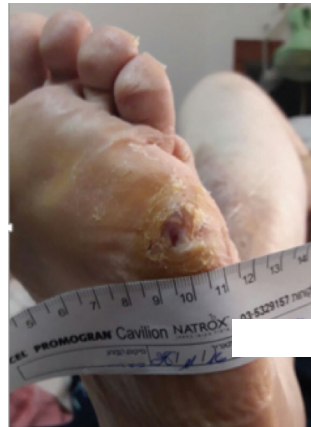

Figure 2: The wound following treatment with NATROX

NON-HEALING FOR 70 DAYS HEALED IN 31 DAYS

Case 2

Joanne McCardle

This was a 46-year-old male with a history of Type 1 diabetes. The patient had a long history of poor control and concordance had been problematic at times. The patient had been attending the clinic twice weekly for the past 10 weeks with a small but challenging diabetic foot ulcer to his fourth metatarsal head. Regular debridement was carried out along with advanced wound dressings applied; however, the wound failed to progress. The patient was keen to “return to normal life”, as the ulcer impacted on his life significantly. It was decided to commence NATROX. Clinic visits were maintained twice weekly and a foam dressing was used as a secondary dressing.

Result:

Complete wound closure was achieved in 31 days. The tissue quality was excellent, which helps to reduce the likelihood of recurrence. The patient found the device very simple to manage at home and liked having some level of responsibility for his own therapy.

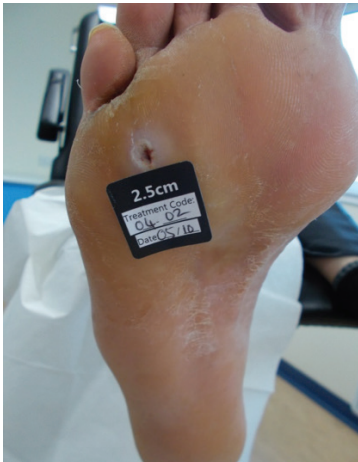

Figure 1: The wound on presentation

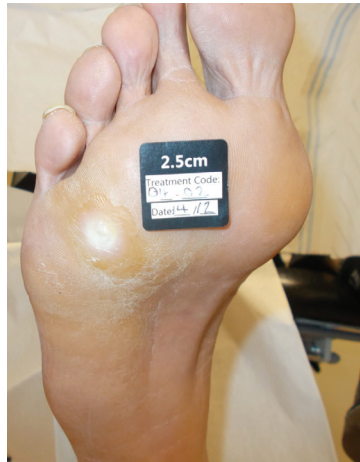

Figure 2: The wound following treatment with NATROX

NON-HEALING FOR 300 DAYS HEALED IN 70 DAYS

Case 3

Nia J. Jones

This 44-year-old male presented at the diabetic foot clinic with a chronic neuropathic ulcer on the plantar aspect of his left mid foot (Figure 1). On examination he had palpable pedal pulses but absent 10g monofilament and vibration perception. Over the next 10 months, he was reviewed once a week for sharp debridement and was placed in a non-removable total contact cast (TCC) for optimal off-loading. However, the wound failed to progress. The patient was unable to continue working during this period and he became quite anxious that this prolonged absence from work would result in him losing his job. This had a negative impact on his health and wellbeing. In September 2016, NATROX was initiated as an adjunct therapy to standard care. Over the following weeks, the frequency of debridement, dressing changes and off-loading modality remained unaltered.

Result:

After 10 weeks of continuous NATROX therapy, complete wound re-epithelialisation was achieved (Figure 2). The patient reported a reduction in anxiety and an improvement in his health and wellbeing.

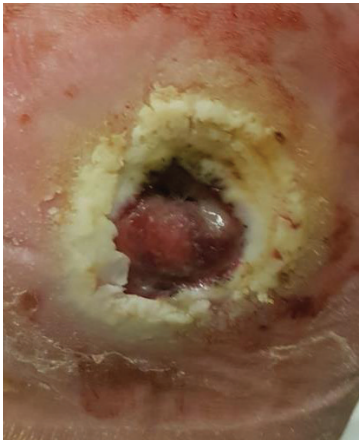


Figure 1: The wound on presentation

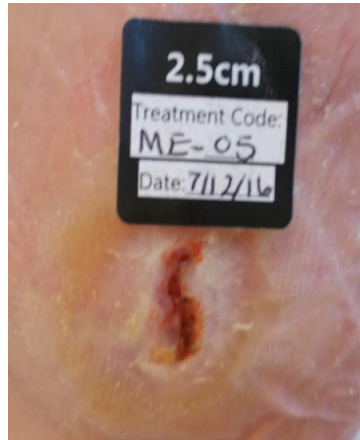

Figure 2: The wound following treatment with NATROX

SUMMARY

NATROX therapy is a simple and extremely easy therapy for patients to manage in the home care setting. Its ability to manage and heal challenging and previously non-healing wounds offers not only clinical and patient benefits, but has the potential to offer health economic benefits as well. Healing wounds frees up resources, both from practitioners' time but also clinic time. With an average episode of care costing £97 in the UK, the cost saving could be significant when implemented appropriately.

References

- Armstrong DG, Cohen K, Courric S et al (2011) Diabetic foot ulcers and vascular insufficiency: our population has changed but our methods have not. *J Diabetes Sci Technol* 5(6): 1591-5
- Armstrong DG, Boulton AJM, Bus SA (2017) Diabetic foot ulcers and their recurrence. *New Eng J Med* 376: 2367-75
- Bradbury S, Price P (2011) The impact of diabetic foot ulcer pain on patient quality of life. *Wounds UK* 7(4): 32-49
- Brennan MB, Hess TM, Bartle B et al (2017) Diabetic foot ulcer severity predicts mortality among veterans with type 2 diabetes. *J Diabet Complications* 31(3): 556-61
- Chadwick P, Armstrong DG (2017) Local management of diabetic foot ulcers Made Easy. *Wounds International*. Available online at: <http://www.woundsinternational.com/made-easys/view/local-management-of-the-diabetic-foot-made-easy> (accessed 2.03.2018)
- Guest JF, Ayoub N, McIlwraith T et al (2015) Health economic burden that wounds impose on the National Health Service in the UK. *BMJ Open* 5: e009283
- Harding K (2016) The essential role of oxygen in wound healing. Presentation. Wounds UK, Harrogate Inotec AMD Ltd. Data on file
- Jones NJ, Curran G, Ivins N et al (2016) An economic evaluation comparing the cost of Natrox therapy versus standard care in the management of diabetic foot ulceration. Poster presentation
- Jupiter DC, Thorud JC, Buckley CJ, Shibuya N (2016) The impact of foot ulceration and amputation on mortality in diabetic patients. I: From ulceration to death, a systematic review. *Int Wound J* 13: 892-903
- Kaufman H (2016) A new approach in oxygen wound therapy: an overview of NATROX experience in Israel. Abstract and presentation. World Union of Wound Healing Societies, Florence
- Prompers L, Huijberts M, Schaper N et al (2008) Resource utilization and costs associated with the treatment of diabetic foot ulcers. Prospective data from the Eurodiale Study. *Diabetologica* 51: 1826-34
- Rice JB, Desai U, Cummings AKG et al (2014) Burden of diabetic foot ulcers for Medicare and private insurers. *Diabetes Care* 37(3): 651-68
- Skrepnek GH, Mills JL, Lavery LA, Armstrong DJ (2017) Health care service and outcomes among an estimated 6.7 million ambulatory care diabetic foot cases in the US. *Diabetes Care* 40(7): 936-42
- Wang Z, Hasan R, Firwana B (2016) A systematic review and meta-analysis of tests to predict wound healing in diabetic foot. *Journal of Vascular Surgery* 63(2): S29-36
- World Health Organization (2016) Global report on diabetes. Available online at: http://apps.who.int/iris/bitstream/10665/204871/1/9789241565257_eng.pdf (accessed 2.03.2018)
- Wounds International (2013) *International Best Practice Guidelines: Wound management in diabetic foot ulcers*. Available at: http://www.woundsinternational.com/media/best-practices/_/673/files/dfubestpracticeforweb.pdf (accessed 22.03.2018)
- Wounds UK (2017) *Consensus round table meeting: Clinical pathway for using topical oxygen therapy in practice*. Available online at: <http://www.wounds-uk.com/supplements/consensus-round-table-meeting-clinical-pathway-for-using-topical-oxygen-therapy-in-practice> (accessed 07.03.2018)
- Wu S, Driver VR, Wrobel JS et al (2007) Foot ulcers in the diabetic patient, prevention and treatment. *Vasc Health Risk Manag* 3(1): 65-76
- Yu J, Lu S, McLaren A-M et al (2016) Topical oxygen therapy results in complete wound healing in diabetic foot ulcers. *J Vasc Surg* 24(6): 1536

