

THE AUTOLYTIC DEBRIDEMENT OF VENOUS LEG ULCERS

Deborah Hofman is Clinical Nurse Specialist in Wound Healing, Department of Dermatology, Churchill Hospital, Oxford

Wound debridement is part of the wound healing process which may occur without intervention but, more often, assistance is needed. It is important to recognise the situations when debridement is not appropriate. This article will describe how to recognise dead tissue that should be removed from the wound, when debridement should not be attempted and the various methods that can be used.

Debridement describes any method that facilitates the removal of dead (necrotic) tissue, cell debris or foreign bodies from a wound (O'Brien, 2003). It is regarded as an essential part of wound bed preparation, as it enhances the potential for a wound to heal. Dead tissue in the wound not only physically prevents the wound from

healing, but also makes the wound vulnerable to infection by providing a source of attachment and nutrients for bacteria.

Identifying dead tissue

Recognising necrotic tissue can present difficulties for the inexperienced practitioner. Devitalised or necrotic tissue arises as a result of a loss of blood supply to the wound bed or as a result of infection. It may have a variety of appearances from loosely adherent slough to tightly adherent leathery black eschar.

Slough is generally described as yellow or brown tissue in the wound, and its texture may vary from slimy to leathery (Figure 1). Yellow slough is frequently present in venous leg ulcers, particularly in ulcers behind the malleoli. A certain amount of yellow slough in a leg ulcer will not necessarily impede healing and will often resolve once compression therapy is introduced. If after a couple of weeks of optimal compression the slough fails to resolve,

autolytic debridement should be attempted.

Tendon, bone, and fatty tissue is also yellow and so care should be taken not to mistake these structures for slough since attempts to debride would be inappropriate.

In some leg ulcers, calcium deposits may be present (Figure 2). These are also yellow and can be distinguished from slough and other anatomical structures as they feel like a 'tooth' when touched with forceps. Wounds will not heal under these circumstances and normally surgical intervention is necessary to remove calcium deposits. If these are observed within the wound, the patient should be referred as appropriate.

Necrotic tissue is generally described as black or dark brown tissue covering the wound surface and is not normally present in healing venous leg ulcers. If black necrotic tissue is present in

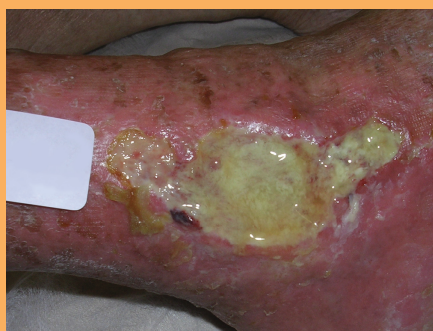

Figure 1. Sloughy tissue in a venous leg ulcer.

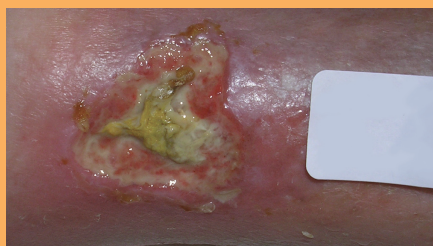


Figure 2. A wound containing calcium deposits.

a leg ulcer, other causes of ulceration should be looked for, e.g. ischaemia (Figure 3), in which case urgent referral to a vascular unit should be instigated. *Pyoderma gangrenosum* and vasculitis are relatively rare conditions which cause leg ulceration and often cause necrosis. In patients with vasculitis, there are usually multiple lesions present (Figure 4). *Pyoderma gangrenosum* usually presents as a rapidly enlarging, very painful lesion with necrosis and typically there is undermining at the wound edges (Figure 5). Patients where these conditions are suspected should undergo urgent referral to a dermatologist.

Slough which is heavily colonised with anaerobic bacteria is also often black. However, this is usually slimy, as opposed to the dry leathery texture of necrotic tissue, and can be effectively managed with topical metronidazole. Topical metronidazole can be used safely on wounds for up to six weeks. There is no known risk of resistance or contact sensitivity. However, in patients who are taking warfarin, it should be used with care as it affects the international normalised ratio (INR).

Dried blood on the wound surface is also black and may be difficult to distinguish from necrotic tissue.

It is important to be able to recognise and describe different types of tissue and to know when to leave well alone. If in doubt specialist help should always be sought.

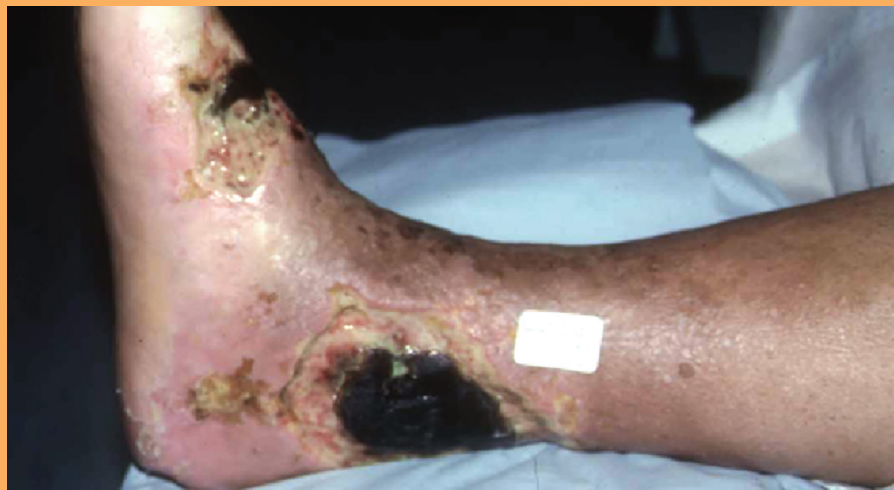

Figure 3. Necrotic tissue in ulcer with significant arterial insufficiency.

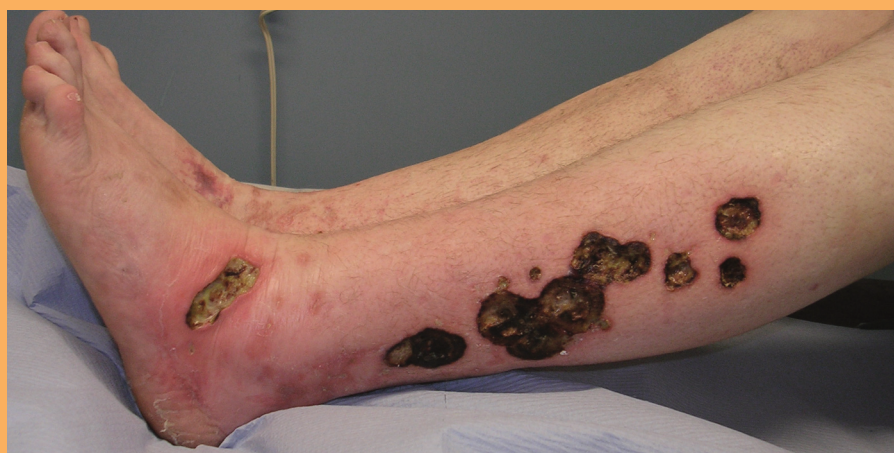

Figure 4. Vasculitis.

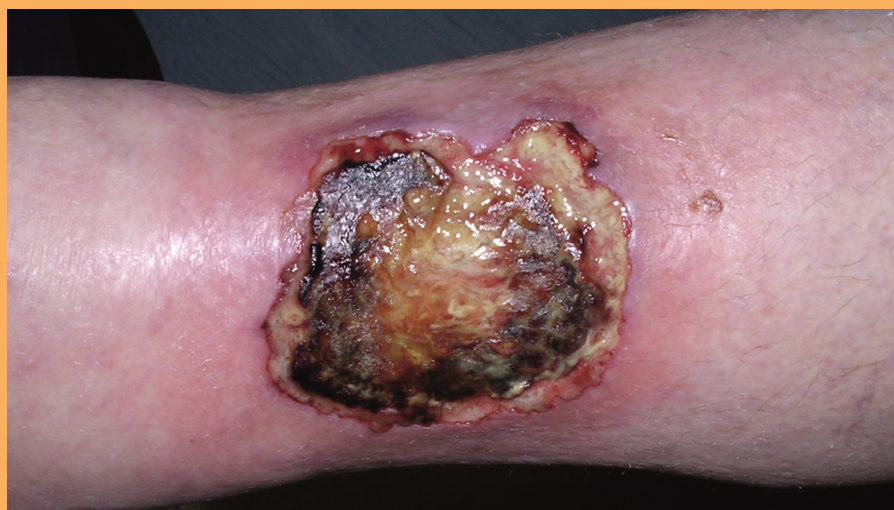

Figure 5. *Pyoderma gangrenosum*.

Selecting a method of debridement

The selection of a method of debridement depends on the availability of product,

local expertise and patient preference.

There are a number of debridement techniques used by

healthcare professionals, and they can be categorised into:

- ▶▶ Active debridement
- ▶▶ Autolytic debridement (either moisture donating or moisture absorbing).

Active debridement

Surgical debridement

Surgical debridement involves the removal of dead tissue from the wound bed. It is carried out under surgical conditions and results in a bleeding wound bed as a result of complete removal of necrotic material. This is carried out by surgeons, podiatrists and specialist nurses who have been trained in the procedure, using scalpel and forceps.

Sharp debridement

Sharp debridement is the removal of dead tissue with scissors or scalpel. This should only be carried out by a healthcare professional who has been trained in the procedure.

Larval therapy

Larvae or maggots have been used in the UK to debride wounds for at least 10 years and are a fast, effective and safe method of debridement (Thomas, 1998). Maggots are now available either as 'free-range' (and placed directly into the wound) or contained in bags. The powerful enzymes in their saliva dissolve necrotic tissue, which the maggots then ingest. They do not have to be in direct contact with the wound bed. However, free-range maggots have the advantage of being able to penetrate crevices and sinuses more effectively. The disadvantage is that they can escape and cause distress to both patient and

practitioner. A detailed guide to larval therapy can be found on p.156–9.

Enzymatic

There are various enzyme preparations which are effective at digesting dead tissue, e.g. collagenase and papain, but these are not currently available in the UK (Bellingeri and Hofman, 2006).

Autolytic debridement

Autolytic debridement is the process by which the body attempts to shed devitalised tissue by the use of moisture. Where tissue can be kept moist, it will naturally degrade and deslough from the underlying healthy structures. This process is helped by the presence of enzymes called matrix metalloproteinases (MMPs), which are produced by damaged tissue and which disrupt the proteins that bind the dead tissue to the body. This process can be enhanced by the application of wound management products which promote a moist environment. These products can be divided into two categories: those that donate moisture to the dead tissue and those that absorb excess moisture produced by the body. Both are designed to facilitate the autolytic debridement process (Gray et al, 2005).

Moisture donation

Hydrocolloids and hydrogels (amorphous gel in a tube or hydrogel sheets), donate moisture to the dead tissue to facilitate autolytic debridement. These dressings are particularly useful in wounds that are not heavily exuding (*Tip 1*).

The use of a second generation hydrogel sheet, e.g. Actiform Cool®, will absorb a certain amount of moisture while donating it so, in many cases, will provide a good moisture balance at the wound surface. If desired the dressing can be cut to fit the wound (*Tip 2*). The white backing should be peeled off and the dressing laid gel side down on to the wound surface. Dressings should be changed when there is strikethrough, but may be left on for up to seven days if there is no leakage. A second generation hydrogel sheet dressing may continue to be used after debridement has occurred through to healing as it promotes granulation tissue and maintains a clean wound bed (*Figures 6,7,8,9*).

Moisture absorption

Alginates, cellulose dressings and foams are designed to absorb exudate. By absorbing excess wound fluid, these products avoid damage to the surrounding skin from maceration (*Tip 3*). The structure of some foam dressings alters under compression so that the moisture remains in contact with the skin. Care should be taken therefore to select an appropriate foam. These dressings

Tip 1

- ▶▶ A common error is to apply a hydrogel to a wet wound that contains some slough in an attempt to debride the wound. It is more important to get the moisture balance right than to remove the sloughy tissue which will resolve itself in the right environment.

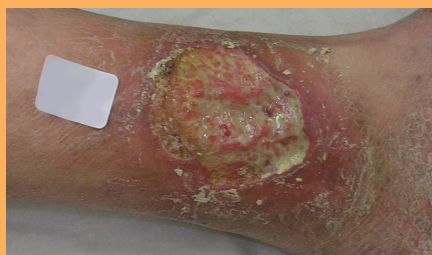

Figure 6. Slough is present on the wound bed before application of dressing.



Figure 7. Remove the backing from the hydrogel sheet and place gel side down on the wound.

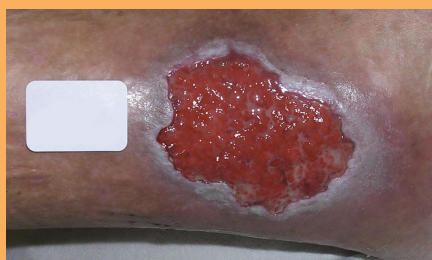

Figure 8. A clean wound bed on removal of the dressing.

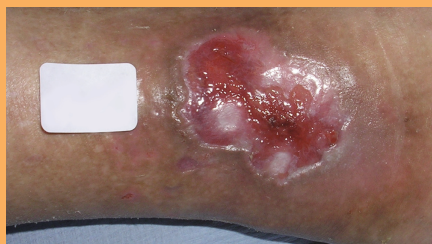

Figure 9. Once debridement has occurred, the dressing can be continued to promote granulation.

should not be used on a dry sloughy wound as they will further dry out the tissue, making it more adherent and painful.

Dressings which reduce the bacterial burden of the wound

A heavy bacterial burden in a wound will encourage tissue

degradation and slough formation. Dressings which reduce bacteria in a wound such as honey, silver, or cleansing fluid such as Prontosan® (Horrocks, 2006), may help to reduce slough and promote healthy granulation.

The process of debridement will increase exudate and this in turn may damage surrounding skin. The frequency of dressing change may have to be increased and surrounding skin protected with a suitable barrier such as Cavilon™ cream/ointment (3M Health Care) or zinc paste. Dressings which donate moisture (such as hydrogels) should not be used on a wet wound as the increase in moisture will macerate the skin. Honey dressings, although increasing exudate in the initial phase, will, by reducing bacterial load, also eventually reduce exudate.

The choice of method of debridement depends on wound severity and patient preference. Many patients like the idea of a natural product such as honey. The only reason to avoid this dressing would be pain as patients often find the drawing sensation intolerable. Maggot treatment is more rapid than autolytic debridement and if the wound is very offensive and there is a lot of sloughy/necrotic tissue the larval therapy should be considered.

If the wound is very painful it is unlikely that maggot treatment will be tolerated, and some patients are repelled by the idea of larval therapy. In a painful wound, the use of a second generation hydrogel sheet should be considered.

Common misconceptions

- ▶▶ Practitioners are rightly taught that debridement is an essential part of wound healing. However, dressings which are marketed as having a debriding action, e.g. hydrogels, are often applied inappropriately without consideration of moisture balance. This can result in maceration.
- ▶▶ In an attempt to debride wounds on wet leg ulcers, the healthcare professional often uses a combination of dressings which are thereby rendered ineffective, e.g. hydrogels (moisture donating) and alginates (moisture absorbing) or hydrogels and foams (moisture absorbing). A combination of these dressings results in a 'sludge' which has no debriding effect.

Where the wound is very wet the practitioner should attempt to identify the

Tip 2

- ▶▶ Patients should be warned that the constituency of the second generation hydrogel sheet dressing will change and there may be an unpleasant odour. This is also true of hydrocolloid dressings.

Tip 3

- ▶▶ Capillary action dressings or those with a super absorbent capability may be useful in the management of very wet sloughy wounds.

cause and address moisture balance before considering debridement. Possible causes of wetness include:

1. Heavy bacterial burden: Does the patient need systemic antibiotics and/or topical antibacterial management (e.g. honey, silver, iodine)?
2. Wet eczema: does the patient need referral to a specialist nurse or dermatologist? Topical steroid therapy may be needed.
2. Oedema: Is the patient receiving adequate compression? Are they elevating their legs sufficiently? Have they been taught dorsiflexion exercises to reduce oedema?
3. Is the dressing sufficiently absorbent? Dressings within the same category perform differently, e.g. foams. Some will remove the exudate from the wound, but others keep the exudate next to the skin causing further tissue damage. Many foams do not perform well under compression. Alginates and cellulose (Aquacel® ConvaTec) dressings can be beneficial. If there is heavy pseudomonal exudate, which has a characteristic bright green colour, dressings containing silver may be helpful.

When is debriding a venous leg ulcer not appropriate?

1. Arterial ulcers should not normally be debrided (Leaper, 2002). If there is a poor blood supply to the limb, it is best to keep a necrotic wound dry until seen by a vascular surgeon, as wet gangrene can occur.
2. When diagnosis is in doubt. For example, *pyoderma*

gangrenosum is characterised by rapid ulceration and necrosis. Debridement is contraindicated as it may cause extension of the ulceration (Chakrabarty and Philips, 2002).

3. The debridement of malignant wounds serves no useful purpose and may cause bleeding. If diagnosis is in doubt, specialist help should be sought.
4. When the patient is systemically severely unwell, for example, in ITU or terminally ill. Local intervention is unlikely to help heal the wound and patient comfort rather than debridement should be a priority.

Conclusions

There are four questions that should be asked before making a decision on how to manage a sloughy/necrotic wound:

1. Is the tissue in the wound definitely slough?
2. Is debridement appropriate?
3. What is causing the slough within the wound? Infection? Poor blood supply?
4. Are the causes being addressed?
5. In choosing dressings which promote debridement, has moisture balance and patient preference been considered?

If in doubt specialist help must be sought. **WE**

Bellingeri A, Hofman D (2006) Debridement of pressure ulcers. In: *Science and Practice of Pressure Ulcer Management*. Springer-Verlag, London:129-39

Chakrabarty A, Phillips TJ (2002) Diagnostic Dilemmas:Pyoderma gangrenosum. *Wounds* 14(8): 302-5

Glossary

Autolysis: natural degradation of dead tissue in a wound.

Calcification: calcium deposits which may occur in a leg ulcer.

Debridement: removal of dead tissue from a wound.

Necrotic tissue/necrosis: dead tissue which is desiccated usually dark brown or black.

Slough: yellow or grey or brown in colour, wet stringy tissue that adheres to the wound bed.

Eschar: dry necrotic tissue.

INR: the time taken for blood to clot compared to a control. Normal range is 0.9-1.2.

Gray D, White R, Cooper P, Kingsley A (2005) Applied Wound Management. In: *Wound Healing: A Systematic Approach to Advanced Wound Healing and Management*. Wounds UK, Aberdeen: 59-96

Horrocks A (2006) Prontosan wound irrigation and gel: management of chronic wounds. *Br J Nurs* 15(22): 1222-8

Leaper D (2002) *Sharp Techniques for Wound Debridement*. World Wide Wounds, Dec 2002

Moffatt C, Morison MJ, Pina E (2004) Wound bed preparation for venous leg ulcers. In: *European Wound Management Association (EWMA) Position Document: Wound Bed Preparation in Practice*. MEP Ltd, London: 12-15

Thomas S, Jones M, Andrews AM (1998) The use of larval therapy in wound management. *J Wound Care* 7(10): 521-4

O'Brien M (2003) Exploring methods of wound debridement. In: White R, ed. *Trends in Wound Care*. Vol 2. Quay books, MA Healthcare, London: 95-107