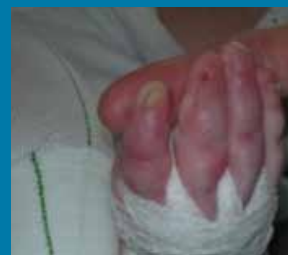
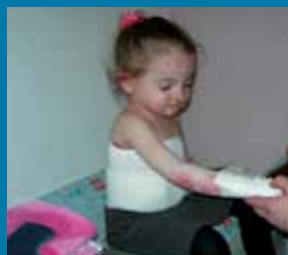
INTERNATIONAL CONSENSUS

BEST PRACTICE GUIDELINES FOR SKIN AND WOUND CARE IN EPIDERMOLYSIS BULLOSA



Great Ormond Street 
Hospital for Children
NHS Foundation Trust

Guy's and St Thomas' 
NHS Foundation Trust


for people whose
skin doesn't work
we do



A Wounds International publication
www.woundsinternational.com

Supported by an award from the Urgo Foundation



The Urgo Foundation is a non-profit-making foundation that offers clinicians the opportunity of funding for projects which will benefit the wound care community.

The funding is awarded to clinical projects that lead progress in medical practice and patient care. For further information: www.urgo.co.uk/331-foundation-urgo

Produced by

Wounds International/Wounds UK
A division of Schofield
Healthcare Media Limited
Enterprise House
1-2 Hatfields
London SE1 9PG, UK
Tel: +44 (0)20 7627 1510
www.woundsinternational.com
www.wounds-uk.com



On behalf of DEBRA:



DEBRA is the national charity that supports individuals and families affected by epidermolysis bullosa (EB) — a genetic condition which causes the skin to blister and shear at the slightest friction, or even spontaneously.
www.debra.org.uk
www.debra-international.org

GUIDELINE DEVELOPMENT TEAM

Authors

Jacqueline Denyer, EB Senior Clinical Nurse Specialist, Great Ormond St Hospital for Children NHS Foundation Trust, London and DEBRA UK

Elizabeth Pillay, EB Nurse Consultant, Adults, Guy's and St Thomas' NHS Foundation Trust Hospital, London and DEBRA UK

Clinical teams and experts

EB team includes:
Great Ormond Street Hospital, London
St Thomas' Hospital, London
Birmingham Children's Hospital
Birmingham Heartlands Hospital
Prof Richard White, University of Worcester, UK
Jacqui Fletcher, Cardiff University, UK
DEBRA, Netherlands
DEBRA, Spain
BrightSky, Australia
DEBRA, New Zealand

All the experts invited to review the guidelines have considerable specialist experience of working with people with EB and have large patient caseloads, or are experts in wound care, on which they base their recommendations.

Disclaimer

This document does not seek to be prescriptive, but it provides a framework for practice. It is not intended to replace clinical judgement and in each situation the clinician must use their own judgement about their patient and their particular wounds. In addition, manufacturers' instructions for product usage should also be noted.

Conflict of interest

None of the authors declared a conflict of interest. Although the guidelines have been funded by an educational grant from the Urgo Foundation, there has been no influence on the content or process of developing the guidelines.

To cite this document

Denyer J, Pillay E. *Best practice guidelines for skin and wound care in epidermolysis bullosa*. International Consensus. DEBRA, 2012.

All rights reserved. © 2012

No reproduction, copy or transmission of this publication may be made without written permission. No paragraph of this publication may be reproduced, copied or transmitted save with written permission or in accordance with the provisions of the Copyright, Designs & Patents Act 1988 or under the terms of any licence permitting limited copying issued by the Copyright Licensing Agency, 90 Tottenham Court Road, London W1P 0LP.

Great Ormond Street 
Hospital for Children
NHS Foundation Trust

Guy's and St Thomas' 
Hospital, London and DEBRA UK
NHS Foundation Trust

Introduction

PURPOSE AND SCOPE

These guidelines have been developed to aid clinicians in the management of skin and wound care for patients with the genetic skin fragility disorder epidermolysis bullosa (EB). Management strategies for wounds or wound complications are suggested for patients of any age diagnosed with any form of this genetically inherited disorder.

ABOUT THIS DOCUMENT

This document was developed using a survey of clinicians from different countries who work with EB and who were prepared to share their knowledge of EB wounds and their management. A systematic literature search (described below) was undertaken to provide further evidence for recommendations. However, as EB is a rare condition with small patient numbers, the literature is predominantly made up of non-analytic studies or expert opinion (Level 3–4 or D, see right hand column).

The information was supplemented with day-to-day experience of people living with EB and their carers' testimonials. This was gathered informally at home visits and clinic attendances, within the day-to-day work of the EB nursing teams.

This document does not seek to be prescriptive, but it provides a framework for practice. It is not intended to replace clinical judgement and in each situation the clinician must use their own judgement about their patient and their particular wounds. It is a tool that can be used globally and includes advice for practitioners who have limited access to wound care materials. A variety of options for managing EB wounds will be presented.

Cost is always a factor to be considered in any healthcare recommendations and this is particularly relevant for EB treatments where vast quantities of expensive dressings can be used over a lifetime. We have only recommended products that we have experience of using over many years and we are confident of the results they can achieve.

HOW THE GUIDELINES WERE DEVELOPED

The initial work was carried out in workshops; opinions were gathered from clinicians working with patients with EB, both in the UK and worldwide.

As part of an advanced course on EB management, nurses and doctors working with EB patients were asked to complete a questionnaire relating to the management of a range of EB wounds. These wounds ranged from chronic ulcerated areas seen in the more severe forms of EB, to new blister sites. They were chosen by the authors as they represented the most common wound types seen in all forms of EB, or a particular problem area.

The group was supplied with photographs of both typical and atypical wounds and asked which primary and secondary dressings, the preferred method of retention and any topical treatments they would use in managing the wound. They were asked to give a range of options for each category.

There was a wide range of experience of wound management for EB within the group, with some clinicians with large caseloads working solely with EB for many years, while others had only experienced one or two cases. Some of the group worked as individuals while others worked as a team, largely reflecting their common working practices. In addition, some participants had limited access to modern wound management products (see Table 17, p26).

The results of the surveys were drawn together to supply evidence for the guidelines. Opinions were given from clinicians from different countries. The draft guidelines were then subject to international peer review by recognised experts in the field of EB, and modifications were made accordingly. The guidelines were then reviewed by a small group of patients and carers and their feedback was used to modify them further.

LEVELS OF EVIDENCE

- 1** ++/+/-
Clear research evidence, eg RCTs, meta-analyses and systematic reviews
- 2** ++/+/-
Limited supporting research evidence, eg case control or cohort studies
- 3** Non-analytic studies, eg case reports, case series
- 4** Expert opinion

(adapted from SIGN 50 A Guideline Developer's Handbook. Scottish Intercollegiate Guidelines Network, Edinburgh, 2008)

GRADES OF EVIDENCE (adapted from SIGN, 2008)

Note: Grade relates to strength of evidence, whether it is directly applicable to the target population and demonstrates consistent results

- A** At least one meta-analysis, systematic review of RCT rated as 1++; or a body of evidence consisting principally of studies rated as 1+
- B** A body of evidence including studies rated as 2++, or extrapolated evidence from studies rated as 1+
- C** A body of evidence including studies rated as 2++; or extrapolated evidence from studies rated as 2+
- D** Evidence level 3 or 4; or extrapolated evidence from studies rated as 2+

(adapted from SIGN, 2008 as above)

SYSTEMATIC LITERATURE SEARCH

The search strategy used was: skin and wound care in EB. A tightly focused search was performed, followed by a wider search. Specific aspects were then added.

Sources included: British Nursing Index, The Cochrane Library, Embase, Google, Google scholar, Medline, Science Direct, Scopus, the National Institute for Clinical Excellence, Scottish Intercollegiate Guidelines Network, the Department of Health.

Search terms**1. Tightly focused search:**

- Epidermolysis bullosa OR EB AND wound care OR skin care OR wound dressings OR dermatology.

2. Wider search:

- Epidermolysis bullosa OR EB OR wounds OR chronic wounds OR non-healing wounds OR skin damage or skin injury AND wound care OR skin care OR wound dressings OR dermatology AND research OR randomised controlled trial OR guidelines OR clinical trial.

3. Specific aspect search — EB and exudate:

- Epidermolysis bullosa OR EB AND wound care OR skin care OR wound dressings OR dermatology AND exudate OR leakage OR ooze.

4. Specific aspect search — EB and pruritus:

- Epidermolysis bullosa OR EB AND wound care OR skin care OR wound dressings OR dermatology AND pruritus OR itch.

5. Specific aspect search — EB and hand wrapping:

- Epidermolysis bullosa OR EB AND wound care OR skin care.

6. Specific aspect search — EB and silicone medical adhesives remover:

- Epidermolysis bullosa OR EB AND wound care OR skin care OR wound dressings OR dermatology AND silicone medical adhesives remover.

7. Specific aspect search — EB and catastrophic bleed:

- Epidermolysis bullosa OR EB AND wound care OR skin care OR wound dressings OR dermatology AND bleed OR catastrophic bleed OR major bleed.

8. Specific aspect search — EB and malignancy:

- Epidermolysis bullosa OR EB AND wound care OR skin care OR wound dressings OR dermatology AND malignancy OR squamous cell carcinoma OR skin cancer.

Boolean operators and MeSH terms were used as required. All articles were in English, dated from 2000–2011 and they were based on humans.

Understanding epidermolysis bullosa

The term epidermolysis bullosa (EB) describes a rare complex group of inherited skin fragility disorders

The most recent classification for EB, agreed in 2008, names four categories of EB defined by the level of cleavage at the dermal/epidermal junction [1]. These are:

- EB simplex (EBS)
- Junctional EB (JEB)
- Dystrophic EB (DEB)
- Kindler syndrome.

The common factor in all types of EB is the tendency for skin and mucous membranes to blister or shear away in response to minimal everyday friction and trauma.

The severity of EB varies between simple blistering affecting the hands and feet, particularly in warm weather, to death in early infancy from the devastating combination of laryngeal disease and failure to thrive. Those with DEB develop contractures, microstomia and oesophageal strictures as a result of contractural scarring.

People with recessive DEB can experience recurrent blistering and skin loss. There is also a tendency to develop chronic wounds resulting from the underlying gene defect, compromised nutrition, chronic anaemia and repeated infection, together with constant trauma.

Non-cutaneous complications, such as anaemia due to iron deficiency and chronic disease, osteoporosis, growth failure and pubertal delay [2] further compromise wellbeing. There is also a greatly increased risk of aggressive squamous cell carcinoma in those with severe forms of EB [3].

ASSESSMENT AND DIAGNOSIS

Within each of the four categories of EB there are subtypes that display individual clinical effects (see p4–6). Definitive diagnosis is most commonly made from analysis of a skin biopsy using positive im-

munofluorescence (IF), antigenic mapping and transmission electron microscopy (EM). These key diagnostic tools help confirm diagnosis and indicate the particular subtype of EB [4].

Identification of the different causative genes responsible for EB enables the recognition of the precise location of and type of mutation. Due to the rarity of expertise and facilities, however, diagnosis is generally made using IF and antigen mapping.

First trimester DNA-based prenatal diagnosis from chorionic villus samples or amniocentesis can be offered to families in whom causative mutations or informative genetic markers have been identified. Experienced clinicians can often make a provisional diagnosis on clinical observations, but a definitive diagnosis will always be required, particularly in neonates where a clear diagnosis is crucial to facilitate correct management.

CAUSES OF EB

EB can be inherited autosomally, recessively or autosomal dominantly; in general, recessive forms tend to be more severe.

Autosomal inheritance

An autosomal condition is inherited on one of 22 non-sex chromosomes.

Recessive inheritance

All individuals inherit two genes for each of their characteristics, one from each parent. In a recessively inherited condition the affected individual will have inherited a 'faulty' gene for a particular characteristic from each parent. The parents are healthy carriers and will have a 1:4 chance with each pregnancy of passing the condition to any child they have. There is a 1:2 chance of each child being a 'healthy carrier' like themselves.

Abbreviations:

- EB** Epidermolysis bullosa
- EBS** Epidermolysis bullosa simplex
- JEB** Junctional epidermolysis bullosa
- DEB** Dystrophic epidermolysis bullosa
- IF** Immunofluorescence
- IMF** Antigenic mapping
- EM** Electron microscopy

Dominant inheritance

In a dominant condition an affected individual has a 1:2 chance of passing the affected gene to their offspring. The dominant gene 'overwhelms' the non-affected gene. There is no carrier status in a dominant condition. Very occasionally an affected individual will present with no family history and this is said to be 'de-novo' inheritance where the affected individual has developed the dominant mutation rather than inheriting it.

More than 1,000 recorded mutations in 14 genes contribute to the various forms of EB, resulting in a huge variety in clinical presentations.

These guidelines outline each main sub-type and focus on the different skin and wound management requirements as well as general principles for wound management for all types of EB.

EB SIMPLEX

Almost all forms of EB simplex are inherited autosomal dominantly, although some rare forms are recessively inherited. Most EB simplex is a disorder of keratin proteins with the primary defects lying within proteins encoding for keratin 5 and keratin 14. These proteins form the major keratin scaffolding within the basal epidermal cells. Dysfunction of the keratin proteins in EB simplex leads to mechanical weakness of these cells; breakdown occurs due to minor friction or rubbing resulting in blistering [5].

All forms of EB simplex are most troublesome in hot and humid environments due to an increase in sweat production exacerbating frictional forces.

Although there are a number of rarer variants, the three main types of EB simplex are:

- **EB simplex localised (Weber-Cockayne)** which primarily affects the hands and feet with blisters arising from friction or spontaneously when the environment is hot or humid.
- **EB simplex generalised (Köbner)** which causes more widespread blistering at an earlier onset with blisters and skin loss frequently present at birth. Blistering persists throughout life but becomes less troublesome, with the main problematic areas being the hands, feet and where clothing causes friction.

- **EB simplex Dowling Meara** is a more severe type of EBS. Its effects may be very severe in the neonatal period and there is a significant risk of death in this age group resulting from sepsis and laryngeal blistering. Blisters typically occur in clusters and often beneath and around nails and in the mouth. Blistering tends to reduce late in childhood and hyperkeratosis develops over the palms and soles.

Two rarer types of EBS include:

- **EB simplex with muscular dystrophy** is a rare form of autosomal recessive EBS that results from mutations in the gene encoding plectin (PLEC1). Plectin plays an important part in both skin and muscles, helping to maintain mechanical function. While skin involvement may be minimal, laryngeal involvement can be severe and the patient may require a tracheostomy. Progressive muscular dystrophy commonly starts any time from the first year onwards.
- **EB simplex with mottled pigmentation** is an unusual variant of EBS which resembles generalised EBS clinically, healing without scarring or atrophy. Pigmentary changes are the main feature of the disorder, with unusual macules seen on the trunk and limbs.

JUNCTIONAL EB

Junctional EB is a group of autosomal recessively inherited disorders, which are characterised by mechanically-induced blistering at the lamina lucida level of the basement membrane zone, between the basal cells and lamina densa. All forms of junctional EB arise from mutations in genes that encode structural components of the hemidesmosomes or anchoring filaments, which provide mechanical integrity across this zone. Separation of the epithelium occurs within the lamina lucida between the lamina densa of the basement membrane and the basal keratinocytes.

There are three main forms of junctional EB:

- Herlitz junctional EB
- Non-Herlitz junctional EB
- Junctional EB with pyloric atresia.

In all forms of junctional EB, the most problematic wounds occur on the scalp and lower legs, while open nail beds and facial lesions are typical in Herlitz junctional EB. There is a

Abbreviations:

- EB** Epidermolysis bullosa
- EBS** Epidermolysis bullosa simplex
- JEB** Junctional epidermolysis bullosa

tendency for chronic wounds to develop and a particular feature is for wounds to over-granulate from an early age [6]. Common features include hypoplastic dental enamel, alopecia and genito-urinary tract involvement in longer-term patients.

Herlitz junctional EB

In this severe subtype, the protein laminin 332 is absent or greatly reduced. Laminin 332 is a major component of the basement membrane zone, providing anchorage across the lamina lucida [7]. For the vast majority, this type of EB carries a very poor prognosis with most not surviving beyond the first two years of life [8]. Death results from a combination of laryngeal blistering/respiratory distress, a profound and uncorrectable failure to thrive, chronic wounds and sepsis. Despite the severity of the systemic disease, good management can help reduce the severity of the wounds.

Non-Herlitz junctional EB

The majority of cases result from mutations in the genes encoding type XVII collagen or laminin 332, which are expressed in skin and other sites such as the urogenital tract. This protein has an important function and plays a major role in the anchorage of the epidermis to the dermis. Type XVII collagen is expressed in the skin, oral mucosa, the cornea, upper oesophagus and bladder epithelium [9].

This type of EB carries a better prognosis than Herlitz junctional EB, with the majority of patients surviving to adulthood, but there is an increased risk (up to 25%) of developing a squamous cell carcinoma after the age of 25 [10]. Chronic wounds may remain a lifelong problem and areas of previous wounding can become atrophied. Nail dystrophy and scarring alopecia are common in older patients. Dental enamel defects in this subtype of EB are very characteristic and a useful diagnostic pointer.

Junctional EB with pyloric atresia

This is associated with pyloric atresia and is a rare subtype of junctional EB which results from mutations in the alpha-6-beta-4 integrin genes. This integrin is an important component of the hemidesmosomes and is found in skin and other epithelia including the gastrointestinal and urogenital tracts. This type of junctional EB frequently has a

poor prognosis despite surgical correction of the atresia. Many patients die in infancy, while milder phenotypes exhibit outcomes similar to those with non-Herlitz junctional EB. However, significant morbidity from urogenital tract involvement is frequently seen in those with this type of EB.

DYSTROPHIC EB (DEB)

DEB can be inherited either dominantly or recessively, with the more severe forms in general being inherited recessively. In all cases there is a diminished or absent protein — collagen VII — which is a crucial component of anchoring fibrils. Anchoring fibrils act rather like Velcro® hooks attaching the epidermis to the dermis. In DEB, separation occurs at the sub-lamina densa of the basement membrane zone.

The extent of skin fragility is extremely varied depending on whether the causative mutation predisposes to mild or severe disease and whether the affected individual has completely absent or reduced collagen VII. In severe forms of DEB there are many complications, which have an impact on the individual's ability to heal, including:

- Malnutrition
- Anaemia
- Recalcitrant pruritus
- Pain
- Infection and critical colonisation [11].

Types of dystrophic EB

Dominant dystrophic EB

This type has an autosomal dominant inheritance. Blistering can be localised to areas particularly subject to trauma such as the hands, feet, knees and elbows, or it can be more generalised. Healing is usually accompanied by some scarring and milia are often present. Mucous membranes, particularly of the mouth and the anal margins, can be fragile leading to difficulties with eating and constipation.

Recessive dystrophic EB — generalised other (RDEB-O)

This type has an autosomal recessive inheritance. Generally, the affected individual is able to express some type VII collagen, with variable qualitative and quantitative abnormalities of the anchoring fibrils. The clinical presentation will vary with a tendency for generalised blistering and consequent wounding, atrophic

Abbreviations:

- HJEB** Herlitz junctional epidermolysis bullosa
- NHJEB** Non-Herlitz junctional epidermolysis bullosa
- JEBPA** Junctional epidermolysis bullosa with pyloric atresia
- DEB** Dystrophic epidermolysis bullosa
- RDEB-O** Recessive dystrophic epidermolysis bullosa generalised other

scarring and nail loss. The development of anaemia is common with this type of EB and there is often mucosal involvement. The hands will be scarred with some webbing, but full pseudosyndactyly is not seen in RDEB-O (see page 10).

Recessive dystrophic EB-severe generalised (RDEB-SG)

In this form of EB the skin is extremely fragile, often with extensive blistering and wounding. Patients with this form of EB will frequently develop hard-to-heal or never-to-heal areas, or areas that do heal but can very quickly break down. Atrophic scarring and healing leading to disabling contractures are common.

Pseudosyndactyly (see page 10) is often present and may require repeated surgery [12, 13]. Severe pain, nutritional compromise and profoundly difficult-to-correct anaemia will all impact negatively on wound healing. Recalcitrant pruritus can lead to destructive scratching and disruption to wound healing.

Dystrophic EB pruriginosa (DEB-PR)

This form can be inherited by dominant or recessive transmission. Patients with DEB-PR will experience the skin fragility already described above, but will also exhibit intense pruritus, which is exceptionally difficult to manage (see page 10). Scratching and skin breakdown can lead to the formation of disfiguring linear scarring in some patients, which appears almost like keloid scarring. Other patients will have extensive blistering and skin breakdown.

Recessive dystrophic EB inversa (RDEB-I)

This type of DEB may be recessive or, less commonly, dominant. The majority of wounds develop in the flexures such as neck, groin and axillae. Hands become scarred but do not progress to mitten deformity. Oesophageal strictures are problematic in this group and may be particularly severe.

KINDLER SYNDROME

Kindler syndrome is an autosomal recessive disorder caused by mutations in the FERMT1 gene. It is rare, difficult to diagnose and is often confused with other subtypes of EB. FERMT1 gene mutations result in blistering, epidermal atrophy and delayed healing [14]. Trauma-induced skin blisters occur in early life and are prevalent together with skin loss and wounding during the neonatal period. The blistering reduces in infancy but over time photosensitivity and signs of poikiloderma (a skin condition characterised by pigmentary and atrophic changes) develop where the skin takes on a mottled appearance.

Other clinical features include periodontitis, oesophageal strictures, malabsorption and diarrhoea in early life, and urethral strictures. There is also an increased risk of mucocutaneous squamous cell carcinoma in later life [15].

In Kindler syndrome the family fermitin homolog 1 is typically markedly reduced or absent within the epidermis and at the dermal-epidermal junction. Unlike all other types of EB, the level of cleavage is variable, with blister formation taking place within the epidermis, lamina lucida or beneath the lamina densa, thus explaining the variable features demonstrated in Kindler syndrome.

Abbreviations:

RDEB-SG Recessive dystrophic epidermolysis bullosa severe generalised

DEB-PR Dystrophic epidermolysis bullosa pruriginosa

RDEB-I Recessive dystrophic epidermolysis bullosa inversa

Skin and wound management: general principles

Skin and wound management must be tailored to suit both the type of EB and also the specific characteristics of the wound

The presence of multiple wounds of varying duration and ability to heal makes management of EB difficult and complex. The underlying principle of lesion management is to apply an atraumatic dressing to prevent pain and bleeding on removal [16]. However, personal preference and lifestyle, as well as the availability of dressings and carers' time also play an important part in selection [17].

All types of EB are characterised by fragile skin and a range of cutaneous involvement from blistering, primarily on the hands and feet, through to more generalised wounding. Healthcare settings are fraught with danger for the EB patient as routine procedures, such as the use of a PATSLIDE® to move a patient or removal of ECG electrodes, can result in extensive skin loss. Staff caring for EB patients must be trained in specific handling techniques to avoid causing harm from friction and removal of adhesive products. **Care must be taken not to cause further injury.**

It is important to listen to the patient and/or carer as many people with EB will have a tried and tested dressing regimen that avoids injury. For example, they may use soft padding to prevent blistering from the edges of a dressing or apply bandaging in a certain way to reduce the risk of contractures. These dressing techniques will have been developed over years of living with EB and many techniques will be atypical.

Careful discussion will usually elicit the reasons why products are being used by patients in a particular way and the clinician should be prepared to be open-minded. In countries where suitable dressings are not available, dressings can often be modified or alternative materials used (see page 26). In addition, clinicians need to educate patients about wound management and inform them of new products as they appear on the market.

MANAGEMENT OF BLISTERS

Blisters occur in all types of EB following friction and relatively minor trauma. They can be present anywhere on the skin and also on the mucous membranes.

The location of a particular blister may be EB-type specific — EBS localised will occur mainly on the hands and feet; and mild forms of dystrophic EB will occur on the areas subject to the most trauma, such as the bony prominences (*Figure 1*). The blisters can occur singly or in clusters depending on the initial degree of trauma and they may be filled with serous or blood-stained fluid.

Blisters are not self-limiting and will extend rapidly if left unchecked. In contrast to recommendations for other dermatological conditions or wound management, intact blisters should be lanced at their lowest point to limit tissue damage [18]. A fresh hypodermic needle should be used or, if this is not available, a sterilised sewing needle. A needle should be passed through the blister roof, parallel to the skin, to create an entry and exit hole through which fluid can be expelled (*Figure 2*).

A soft piece of material, such as gauze, can be used to gently compress the blister to encourage complete emptying. If this compression is painful, a syringe can be attached to the needle to aspirate the fluid.

Some patients advocate using sterilised scissors or a scalpel blade to create a larger hole to prevent the blister from refilling. The roof should be left on the blister unless personal preference is to de-roof it to prevent refilling, but de-roofing can lead to additional pain and should be discouraged if possible.

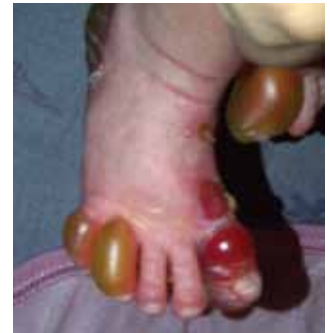

Figure 1. Blisters on toes in patient with EBS.

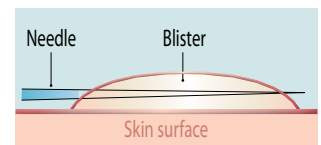


Figure 2. Recommended method of blister lancing. Permission from Birmingham Children's Hospital

MANAGEMENT OF EB SIMPLEX

Dressing management in EB simplex focuses on preventing infection, cooling the blister sites and protecting the skin from trauma. However, observation within the authors' large caseload indicates many patients prefer to leave blisters undressed. Dressings can lead to overheating which increases the tendency to blister as sweating increases friction. The patient may also

blister around the edge of dressings on areas subject to great pressure such as the feet. Dressings and padding on the feet may make it impossible to wear shoes and dressings on the hands may hamper the patient's dexterity. For information on recommended wound dressings see *Table 1*.

The most effective management is lancing the blisters [19]. For patients who dislike dressings

TABLE 1 Recommended dressings for EBS localised and generalised

Dressing type	Brand	Manufacturer	Indication/function	Contraindication/comments
Soft silicone	Mepitel® ADAPTIC TOUCH®	Mölnlycke Health Care Systagenix	Wound contact layer	Mepitel® and ADAPTIC TOUCH® should not be used in patients with Dowling Meara
Lipido-colloid	Urgotul®	Urgo Medical	Wound contact layer	Not suited to very moist wounds (problems with retention)
Foam	Mepilex®/Mepilex® Lite/ Mepilex® Transfer	Mölnlycke Health Care	Protection	Heat-related blistering. Mepitac® can be used with Mepilex® Lite for fixation if required
Hydrogel	INTRASITE™ Conformable	Smith & Nephew	Cooling Pain reduction	Do not allow to dry out
Sheet hydrogel	ActiFormCool®	Activa Healthcare Ltd, an L+R company	Cooling Pain reduction	Unusual pain reactions have been reported. Keep backing on to keep moist for longer
Biosynthetic cellulose	Suprasorb® X	Activa Healthcare Ltd, an L+R company	Cooling Pain reduction	Cover with lipido-colloid to prevent drying out. Will tighten on dessication so use with care around the digits
Bordered	Mepilex® Border/ Border Lite ALLEVYN™ Gentle Border/ ALLEVYN™ Lite Advazorb Silflo® Urgotul® Duo Border	Mölnlycke Health Care Smith & Nephew Advancis Medical Urgo Medical	Protection	May require removal assisted by silicone medical removers such as Appeel® (CliniMed), Niltac™ (ConvaTec) or Peel-Easy® (CD Medical) to avoid skin stripping
Powder	Cornflour (Corn starch)	Commercial	Apply following lancing of blisters	Do not use cornflour on open wounds or in the nappy area where it will turn into a paste

*Table adapted from Denyer J. Wound management for children with epidermolysis bullosa. *Dermatol Clin* 2010; 28: 257-264.

TABLE 2 Recommended dressings for patients with EBS Dowling Meara

Dressing type	Brand	Manufacturer	Indication/function	Contraindications/comments
Lipido-colloid	Urgotul®	Urgo Medical	Wound contact layer	Use as a primary dressing under PolyMem® if there is risk of adhesion. Ensure there are no folds or creases which will result in blistering
Polymeric membrane	PolyMem®	Ferris	Wounds present at birth	Strips of a Hydrofiber® will need to be placed under the edges of the dressing to protect the skin. Change when wet in small infants to avoid hypothermia (See <i>Table 7, page 15</i>)
Hydrofiber®	AQUACEL®	ConvaTec	Protection from edges of dressings (see above)	Irrigate with water or saline to remove if necessary

or find they exacerbate the blister sites, commercial cornflour (corn starch) may be used to dry up the blistered areas and provide a low friction surface. Silk socks can help to reduce friction and are seam free. Clinical experience also suggests that silver may help to keep feet cool [20].

EB simplex Dowling Meara needs specific management as any dressing materials have the potential to create blisters around the edges of the dressing (Table 2).

Neonates may present at birth with wide-spread skin loss and although dressings are required, measures must be taken to protect the skin around the dressing. Once the wounds

are healed dressings are not used for protection in view of the resulting damage. A thin layer of equal parts of white soft and liquid paraffin can reduce friction and soft seam-free clothing offers protection.

MANAGEMENT OF JUNCTIONAL EB

Wound management in junctional EB is focused on managing chronic wounds and excessive granulation tissue (Table 3).

Open nail beds, the umbilical and nappy area all pose particular challenges in infants with Herlitz junctional EB. Use of very potent topical steroid ointments greatly reduces over-granulation and may encourage healing.

TABLE 3 Recommended dressings for patients with junctional EB

First choice of dressing when available: Infants and eroded blister sites - IntraSite™ Conformable; Chronic or acute wounds - PolyMem® with Urgotul® as the primary dressing; Open nailbeds - Mepitel®

Dressing type	Brand	Manufacturer	Indication/function	Contraindications/comments	Wear time
Hydrogel impregnated gauze	INTRASITE™ Conformable	Smith & Nephew	Eroded blister sites. Neonates and infants	Small neonates at risk of hypothermia. May be used with topical morphine only when pain is difficult to	Change daily or when dry. May need Urgotul® as primary contact layer
Hydrofiber®	AQUACEL®	ConvaTec	Very moist wounds where it is difficult to keep dressing in place	Lightly exuding or dry wounds	Change every 3-4 days or when saturated. Rehydrate to remove if dry and adherent
Lipido-colloid	Urgotul®	Urgo Medical	Wound contact layer		Change every 3-4 days
Soft silicone	Mepitel® ADAPTIC TOUCH® Silflex®	Mölnlycke Health Care Systagenix Advancis Medical	Soft silicone wound contact layer	There is a risk of overgranulation when using a soft silicone wound contact layer Silflex® only: Adherence may be too great for very fragile skin	Dependent on condition of wound and patient/carer preference
Polymeric membrane	PolyMem®	Ferris	Chronic and acute wounds	Stimulates high levels of exudate — use barrier film to protect periwound skin if required. Distinct smell does not necessarily indicate infection. Can be difficult to retain on vertical surfaces	As determined by exudate level. Change very frequently until exudate reduces
Soft silicone foam	Mepilex® Mepilex® Lite Mepilex® Transfer	Mölnlycke Health Care	Protection Absorption	May adhere if placed directly on wound bed, use an atraumatic wound contact layer	As determined by exudate level and patient/carer preference
Soft silicone foam with super-absorbers	Cutimed® Siltec®	BSN medical	Protection Absorption Excessive exudate	Can be cut between superabsorbent crystals	As determined by exudate level

*Table adapted from Denyer J. Wound management for children with epidermolysis bullosa. *Dermatol Clin* 2010; 28: 257-264.

DEB Dystrophic epidermolysis bullosa

DEB-PR Dystrophic epidermolysis bullosa pruriginosa

RDEB-SG Recessive dystrophic epidermolysis bullosa severe generalised

Practical advice on patients experiencing pruritus:

- Avoid sudden changes in temperature and over-heated environments where possible. Some patients may benefit from a portable air conditioning unit in the hotter months. This is a particular consideration in overheated hospital environments. A cheaper solution may be a Chillow® which as the name suggests is a pillow that remains cool.
- Avoid using highly perfumed products on the skin
- Use laundry products for sensitive skin
- Clothing should be loose fitting and many people avoid products made of wool. DermaSilk (Espère) and DreamSkin® garments are cool and have anti-pruritic qualities.
- Stress may exacerbate itch and patients may benefit from relaxation techniques and other methods of stress management.

From the authors' experience, a soft silicone mesh has a tendency to encourage over-granulation even to the extent where the tissue grows through the mesh and forms a bridge over the dressing.

MANAGEMENT OF DYSTROPHIC EB

Management of DEB must address critical colonisation and infection, offer protection from trauma, avoid contractures and reduce pruritus. Dressings are often extensive and large sizes must be sought in order to avoid blistering where two smaller dressings join (*Table 4*).

Exudate can be copious and needs careful containment to avoid maceration and leakage (see page 20). Odour can be a feature and must be addressed to avoid embarrassment and social compromise although eradication can be impossible.

Management of pruritus

Pruritus is one of the most challenging aspects of the management of dystrophic EB. Intense itch provokes damaging scratching leading to further cutaneous damage.

Almost healed wounds are particularly pruritic and scratching can lead to wound breakdown. Apart from skin breakdown, intense pruritus can be seen as part of the pain spectrum and can lead to insomnia and depression. This is particularly marked in DEB-PR.

Practical approaches

If the skin is lacking in moisture it has a tendency to be itchier. However, when treating pruritus in EB there has to be a balance between moisturising the skin without it becoming prone to blistering. Topical emollients, including moisturisers, and bath oils are helpful.

Moisturisers containing sodium lauryl sulphate should be avoided as this can exacerbate skin damage [21]. Moisturisers that contain an antimicrobial agent such as benzalkonium chloride and chlorhexidine dihydrochloride, both found in Dermol™ products (Dermal Laboratories), have been reported to be helpful both in reducing itch and helping to reduce bacterial colonisation.

Other topical applications that may be useful include doxepin cream 5%, menthol in an

oil-based product (such as Dermacool®, Pern Consumer Products), while topical steroids may be helpful for particularly acute severe itch. A modified wet-wrap technique similar to that used for severe eczema may be helpful. It is important to cover the skin with a suitable primary dressing before applying the wet-wrap to avoid adherence.

As pruritus in EB is not mediated by histamine, antihistamines tend to be of limited value. However, the sedating effect of some antihistamines may be valuable in managing the urge to scratch, which can occur at night when there is little else to distract the patient.

Other medications that have been used for severe recalcitrant itch include:

- Gabapentin
- Amitriptyline
- Ondansetron
- Thalidomide
- Ciclosporin.

Management of pseudosyndactyly

Neonates with RDEB-SG are frequently born with wounds extending over their limbs, hands and feet, caused by intrauterine movement and delivery trauma. In many cases careful dressing of these wounds, with attention paid to separating the digits, can prevent early fusion [22].

De-gloving injuries are not uncommon following trauma and these also require immediate action to separate the digits to prevent digital fusion.

Despite these measures, over time and following repeated trauma the web spaces are gradually lost and digital fusion and contractures will develop.

Surgery is usually successful in releasing the contractures and separating the fingers, but this is complex and requires skin grafting, repeated general anaesthesia and compliance with post-surgical splinting. In many patients, the process of fusion and contractures begins again within a short time [23].

Some adult patients may decline hand surgery because of the need for repeat procedures, preferring instead to manage with hands that may in some cases exhibit complete 'mitten deformity'.

TABLE 4 Recommended dressings for dystrophic EB

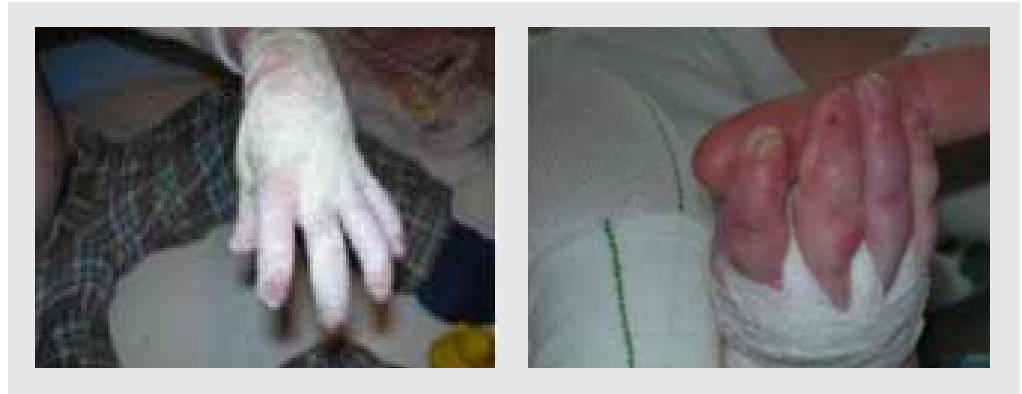
First choice of dressing when available: Chronic or acute wounds – PolyMem®. First choice superabsorbent – Cutimed® Siltec®

Dressing type	Brand	Manufacturer	Indications/function	Contraindications/comments	Wear time
Soft silicone	Mepitel®	Mölnlycke Health Care	Moist wound	Silicone sensitivity resulting from impurities in the silicone, a rare result of long-term continual use Silflex: Adherence may be too strong for very fragile skin	Up to four days depending on presence of infection and patient choice
	ADAPTIC TOUCH®	Systagenix			
	Silflex®	Advancis Medical			
Lipido-colloid	Urgotul®	Urgo Medical	Moist wound, drier wounds and protection of vulnerable healed areas. Use as an alternative to soft silicone (see above) in the presence of overgranulation	Where retention is difficult (eg vertical surfaces)	Up to four days depending on presence of infection and patient choice
Foam with soft silicone	Mepilex®	Mölnlycke Health Care	Absorption of exudate Protection Lightly exuding wounds To transfer exudate to absorbent dressing. Where conformability is required eg digits, axillae	Over-heating May need to apply over recommended atraumatic primary dressing such as Mepitel® or Urgotul®	Change when strikethrough noted
	Mepilex® Lite	Mölnlycke Health Care			
	Mepilex® Transfer	Mölnlycke Health Care			
Soft silicone foam with super-absorbers	Cutimed® Siltec®	BSN medical	High exudate levels	Can be cut between super-absorbers	Change when strikethrough noted
Foam	ALLEVYN™	Smith & Nephew	Absorption and protection	May need to apply over recommended atraumatic primary dressing	Change when strikethrough noted
	UrgoCell®	Urgo Medical			
Polymeric membrane	PolyMem®	Ferris	Where cleansing is required Chronic wounds	Stimulates high levels of exudate. Distinct smell does not necessarily indicate infection. Can be difficult to retain on vertical surfaces	Change when strike-through noted. Change frequently until exudate reduces
Super-absorbent dressings	Sorbion Sana®/Sorbian Sachet S®	H&R Healthcare	For highly exuding wounds	Arterial bleeds. Apply over atraumatic primary wound contact layer (soft silicone mesh or lipido-colloid)	Change when saturated
	Flivasorb®	Activa Healthcare Ltd, an L+R company			
	Curea P1®	Bullen Healthcare/Curea Medical			
	Eclipse®	Advancis Medical			
Bordered dressings	Mepilex® Border/Border Lite	Mölnlycke Health Care	Isolated wounds. Dominant dystrophic and mild DEB	Bordered dressings may require removal with silicone medical adhesive remover to avoid skin stripping. May require primary contact layer in those with very fragile skin. Poor absorption of highly viscous exudate	Up to four days depending on personal choice
	ALLEVYN™ Gentle Border/Border Lite	Smith & Nephew			

*Table adapted from Denyer J. Wound management for children with epidermolysis bullosa. *Dermatol Clin* 2010; 28: 257-264.

Figure 3 (left). Full hand wrapping in a patient with RDEB-SG.

Figure 4 (right). Modified hand wrapping to allow greater freedom of fingers (to be used in infants and toddlers for messy play and finger feeding). May be preferred by older children and adults.



Hand wrapping using a soft conforming 2.5cm bandage that provides downward pull on the web spaces and around the palm, is useful in preventing the loss of web spaces by forcing down the skin (Figures 3 and 4). In some children extending this technique to wrapping each finger individually has been successful in maintaining good results after surgery. Any open wounds or blister sites should be covered with a non-adherent dressing before wrapping and intact skin should be protected with a layer of greasy emollient.

MANAGEMENT OF KINDLER SYNDROME

The level of cleavage in Kindler syndrome is variable at an ultrastructural level, but this is not clinically relevant and does not affect how a patient may present. See Table 5 for the recommended dressings. The lancing of blisters is important in infants and the rate of blistering decreases with age. Application of high factor sun protection is essential from an early age.

TABLE 5 Recommended dressings for patients with Kindler syndrome*

Dressing type	Brand	Manufacturer	Indications	Contraindications/com-ments	Wear time
Soft silicone mesh	Mepitel®	Mölnlycke Health Care	Moist wound	Silfex: Adherence may be too strong on very fragile skin	Up to four days in neonates. Older child/adult less likely to need such dressings but if used change in line with patient preference
	ADAPTIC TOUCH®	Systagenix	Moist/drier wound		
	Silflex®	Advancis medical	Moist wound		
Lipido-colloid	Urgotul®	Urgo Medical	Moist/drier wound	Can be difficult to retain on vertical surfaces	As above
Soft silicone foam	Mepilex®/Lite/Transfer	Mölnlycke Health Care	Exudate management and protective padding	Usually only needed for neonatal wounds	As above
Bordered	Mepilex® Border/Border Lite	Mölnlycke Health Care	Isolated wounds	Border dressings should not be used on older children and adults. May need SMAR (silicone medical adhesive remover) to remove. Adherence may be too strong for very fragile skin	As above
	ALLEVYN™ Gentle Border	Smith & Nephew			
	Advazorb Silflo®	Advancis Medical			

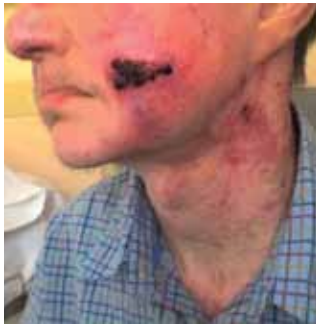

Figure 5. Skin loss following removal of soft silicone tape (Mepitac®, Mölnlycke Health Care).

SMAR Silicone medical adhesive removers

WOUND DRESSING CONSIDERATIONS

Retention of dressings

Great care must be taken to ensure dressings do not slip, which can tear the fragile skin and cause adherence of existing wounds to clothing or bedding.

The retaining bandage or tape can also lead to additional blistering from movement or contact with the surrounding skin. Retention must allow for freedom of movement to discourage development of contractures in those with dystrophic EB.

A range of EB-specific retention garments (Skinnies™) have just been developed with the aid of patients and carers (Table 6).

Silicone medical adhesive removers

The introduction of silicone medical adhesive removers (SMAR) has revolutionised the management of EB. Availability of these products means adhesive materials can be safely used to secure intravenous canulae, central lines and nasogastric tubes. In addition, accidental application of an adhesive product need not result in skin stripping (Figure 5).

The products are also invaluable when clothing or bedding adhere to wounds and blister sites. The spray is useful for removing large dressings or adherent materials and the sterile sachets can be used for the face and around central lines [24].

TABLE 6 Recommendations for dressing retention

Type	Brand	Manufacturer	Indications/function	Contraindications/comments
Bandage	K-Band®	Urgo Medical	Dressing support and retention	Protect dry skin with emollient prior to bandaging. Cover all wounds before bandaging to avoid adhesion
	Easifix K™	BSN medical	Use 2.5cm width for hand wrapping	
Tubular bandage	Tubifast® 2-way stretch	Mölnlycke Health Care	Dressing support and retention	As above
	ComfiFast MultiStretch™	Synergy		
	CliniFast®	CliniSupplies		
	ActiFast®	Activa Healthcare Ltd, an L+R company		
Garments	Skinnies™	Skinnies UK	Skinnies™ have a range of garments designed with clinical teams and the patient group, specifically for EB patients. Standard Skinnies™ are available in paediatric and adult sizes	As above
	Dreamskin®	Dreamskin		
	DermaSilk	Espère		
	Tubifast® garments	Mölnlycke Health Care		
	Comfifast™ Easywrap™ Suits	Synergy		
Cohesive bandage	ActiWrap®	Activa Healthcare Ltd, an L+R company	Dressing support and retention	Do not apply too tightly or it will have a tourniquet effect
Soft silicone tape	Siltape®	Advancis Medical	Use in place of normal adhesive tape	May require SMAR for safe removal from very fragile skin
	Mepitac®	Mölnlycke Health Care		

For advice on mouth and dental care see:

■ Oral Health Care for Patients with Epidermolysis: Bullosa Best Clinical Practice Guidelines 2012. Available at: http://www.debra-international.org/fileadmin/media_data/4_DEBRA_International/Documents/Articles/Oral_Health_Care_-_S_Kraemer.pdf

GENERAL MANAGEMENT PRINCIPLES

Ideally, management of EB should take place in a specialised centre with assessment and treatment available from a multidisciplinary team. In addition to the importance of monitoring the integrity of the skin and providing wound care, attention must also be paid to optimising nutrition and dental health, minimising deformity, ophthalmic complications and genitourinary problems [25]. Abnormal bone health may also further compromise wellbeing and can lead to osteopenia, osteoporosis and fractures [26]. This is a multifactorial complication and causes may be due to lack of weight-bearing exercise, poor nutritional intake, abnormal biochemistry, pubertal delay and a generalised inflammatory state which leads to bone catabolism [27].

Nutritional support

Long-term enteral feeding may be required to optimise nutrition for those with severe forms of EB, in whom intake is compromised due to poor appetite, oral blistering and dysphagia [28]. In addition, vastly increased nutritional requirements are needed to compensate for losses [29, 30] and to aid wound healing. Regular oesophageal dilatations can temporarily improve swallowing when strictures present in patients with dystrophic EB [31].

Pain management

Optimal pain management is vital for patients with all forms of EB and include pharmacological and non-pharmacological interventions. Simple analgesia such as paracetamol and ibuprofen may be sufficient to manage mild pain, while opioids and anxiolytics are necessary for severe pain associated with dressing changes [32]. Severely affected patients benefit from long-acting opioids. All EB patients may benefit from treatment with amitriptyline or gabapentin to help control neuropathic pain. Effective non-pharmacological interventions include guided imagery and distraction therapies. A validated pain scoring system should be used to evaluate a patient's pain experience. **When a new dressing regimen is recommended it should not add to the patient's experience of pain** [33].

Psychological evaluation

Depression, social isolation and despair can all have a significant impact on people with EB and their families [34], as well as on occasion those professionals caring for them [35]. The negative feelings that result from living with a chronic incurable disease can lead to the patient be-

coming disillusioned with healthcare provision and non-concordant with treatments offered as a result. It may lead to patients not attending appointments and refusing certain medications. When recommending new dressings, healthcare professionals may be greeted with scepticism and should be prepared to explain carefully why they are suggesting a new dressing and what its benefits might be.

Bathing

Cleansing of patients with EB is a contentious issue, with some advocating daily bathing and others discouraging the practice due to difficulties, such as handling and time factors or intractable pain.

While patients with severe EB benefit from bathing or showering in terms of general hygiene and wound cleansing, many find this too difficult, painful and time-consuming. There is also a wide difference of opinion as to what constitutes best practice in wound cleansing for EB patients [36], with clinicians recommending a variety of techniques including:

- Chlorhexidine baths before surgical procedures (eg when releasing pseudosyndactyly). Chlorhexidine should be provided for a limited period of time in an attempt to reduce gram-positive organisms. Conversely others believe caution should be exercised with use of chlorhexidine as it may be neurotoxic [37].
- Vinegar soaks to gain control of gram-negative organisms, such as pseudomonas [37].
- Diluted bleach has been shown to reduce rates of infection in those with atopic dermatitis [38]. The National Eczema Society recommends 10ml bleach per gallon of water (5ml/5 litres of water), or one small capful to a baby bath and one quarter to one half cup to a full-size bath [39]. The dilute bleach should be rinsed off after bathing to prevent itch. This method has been advocated in some centres for patients with EB.
- Salt baths have proved popular with some patients, possibly because the osmotic effect is useful in preventing pain. Add approximately 90g of table salt to 10 litres of water to achieve a 0.9% solution. Salt can be used in combination with antiseptics to reduce their potential to sting [40]

However, all these methods require the patient to get into a bath and many are simply unwilling or unable to do this. Therefore, other methods of cleansing and reducing the bioburden of wounds must be deployed (see page 22).

Special considerations

EB is a life-long disorder that requires specialist intervention and considerations to minimise complications and improve quality of life

CARE OF NEONATES WITH EB

Blisters are usually present at birth or appear during the neonatal period. Secondary infection is the primary complication. For the recommended dressings used in the management of neonates with EB see *Table 7*.

In addition there are several wound care and blister prevention techniques that can be administered when caring for a newborn that may help lessen the chance of infection and reduce pain (see Box 1, page 16).

TABLE 7 Recommended dressings for neonates with EB

First choice of dressings when available: wounds – PolyMem®; nappy area – IntraSite™ Conformable; between digits – AQUACEL®

Dressing type	Brand	Manufacturer	Indications/function	Contraindications/comments	Wear time (extended due to poor response to handling exhibited by neonates)
Hydrogel impregnated gauze	INTRA-SITE™ Conformable	Smith & Nephew	HJEB Eroded blister sites Wounds/blister sites in nappy area Can be used over nappy cream such as Bepanthen or a barrier (eg Proshield® Plus)	Small neonates at risk of hypothermia	Change daily or when dry. May need primary contact layer (eg Urgotul®)
Hydrofiber®	AQUACEL®	ConvaTec	Very moist wounds where it is difficult to keep dressings in place. Between digits where there is a risk of fusion	Lightly exuding or dry wounds	Change every 3–4 days or when saturated
Lipido-colloid	Urgotul®	Urgo Medical	Wound contact layer	Can be difficult to retain on vertical surfaces	Change every 3–4 days
Soft silicone mesh	Mepitel®	Mölnlycke Health Care	Wound contact layer	Increased risk of overgranulation in JEB. Increased risk of blistering in EBS DM	Change every 3–4 days
Soft silicone foam	Mepilex®/ Mepilex® Lite/ Mepilex® Transfer	Mölnlycke Health Care	Protection Absorption	Use as secondary dressing over primary layer of soft silicone or lipido-colloid mesh to prevent adherence	As determined by exudate level
	Advazorb Silfix®	Advancis Medical		Silfix: Adherence may be too strong for very fragile skin	
Soft silicone foam with super-absorbers	Cutimed® Siltec®	BSN medical	Protection Absorption where exudate excessive	For lightly exuding wounds. Can be cut between superabsorbent crystals	As determined by exudate level
Polymeric membrane	PolyMem®	Ferris	First choice dressing for severe neonatal wounding. Critical colonisation/ infection	Change when wet to avoid hypothermia	As determined by exudate level

BOX 1: Additional recommendations for the care of neonates with severe EB

Procedure	Rationale
Remove from incubator unless prescribed for other medical condition such as prematurity	Heat and humidity exacerbate blistering
Remove cord clamp and replace with ligature	To prevent trauma to umbilical area
Line nappy with soft material	To prevent blistering at edges of nappy
Cleanse nappy area with 50% liquid/50% white soft paraffin in ointment or spray (Emollin™) form	To ensure cleansing without trauma. To reduce pain
Delay bathing until prenatal and birth trauma healed	To avoid damage from infant being handled naked
Nurse on neonatal incubator mattress	To enable infant to be lifted on mattress and avoid shearing forces from carer's hands
Use long soft teat such as lamb's teat or a Haberman Feeder	To avoid friction damage to underside of nose and oral mucosa
Apply teething gel to teat (use a preparation that is safe to use from birth)	To alleviate pain from blistered mucosa

TABLE 8 Care of the EB patient in the operating theatre

Procedure	Action	Rationale	Comments
ECG monitoring OR OR	<ul style="list-style-type: none"> ■ Stick electrodes directly to skin ■ Stick electrodes to Mepitel One® (Mölnlycke Health Care) ■ Lightly bandage upper arms and stick gelled electrodes to bandage 	To achieve effective monitoring without damaging the skin	Only stick electrodes directly to the skin if silicone medical adhesive remover (SMAR) is available. When SMAR is not available cover open wounds with non-adherent dressing before bandaging
Blood pressure monitoring	Place layer of padding such as velband/softband beneath cuff	To minimise skin damage and reduce the risk of blistering	Cover any open wounds with non-adherent dressing before applying velband
Protection of the eyes and lids	Apply lubricating drops/ointments. Cover with Gelperm® (Geistlich Sons)	To reduce risk of eyelid damage or corneal abrasions	Omit lubrication in small children and warn older children or adults about blurred vision upon recovery
Venepuncture	Avoid use of elastic tourniquet or glove. Squeeze limb firmly, avoiding shearing forces. Avoid excessive rubbing during skin preparation	To minimise skin trauma	Wrap dressing material/softband around limb before squeezing. Cover any broken or blistered areas with non-adherent dressing before applying the protective layer
Retention/securing of cannula and equipment	<ul style="list-style-type: none"> Use soft silicone tape — Siltape® (Advancis Medical) or Mepitac® (Mölnlycke Health Care) Use adhesive tape Use commercial clingfilm 	<ul style="list-style-type: none"> To avoid skin stripping Fixation Fixation 	<ul style="list-style-type: none"> May need to use SMAR if skin is very fragile If SMAR not available and adhesive used apply 50% liquid/50% white soft paraffin to saturate tape and slowly work free Use clingfilm if soft silicone tape or SMAR not available
Using face mask	<ul style="list-style-type: none"> Apply Mepitel® One (Mölnlycke Health Care) over face and under chin Apply Vaseline® gauze over face and under chin 	<ul style="list-style-type: none"> To avoid shearing forces when using a facemask (especially when there is a change of personnel) To avoid blistering from mask 	<ul style="list-style-type: none"> May need sterile SMAR (Appeel Sterile®, CliniMed) to remove Mepitel® One if skin is very fragile Take care during change of personnel as the mask may slip

CARE OF EB PATIENTS IN THE OPERATING THEATRE

Common surgical procedures include repair of 'mitten glove' deformity, release of contractures, dental extraction, oesophageal dilatation, formation and repair of gastrostomy sites, excision of squamous cell carcinoma, skin grafting and limb amputation. When a patient with EB requires surgery, adjustments are also required to anaesthesia and theatre protocols to minimise skin damage and to protect the vulnerable airway (Table 8). Consideration should also be given to pressure area care.

GASTROSTOMY SITE MANAGEMENT

Long-term enteral feeding is necessary for many of those with severe EB (Table 9, see also Case Report page 34). The combination of fragility of the mucosa of the upper gastrointestinal tract, leading to blistering of the mouth and pain on eating, dysphagia secondary to narrowing and scarring of the oesophagus, the raised nutritional requirement exacted by exuding wounds, and the chronic inflammation seen in severe forms of EB mean oral intake alone is inadequate. Additionally, chronic constipation and painful dentition can lead to a reluctance to eat [41]. Despite the advantages in enteral feeding, cutaneous complications following the intractable leakage of acidic stomach contents onto

the skin of the abdomen lead to skin loss and chronic wounds.

Careful selection of the device can help to reduce complications. 'Button' type gastrostomy tubes are popular as they are discrete; however, they need the feeding tube to be connected very close to the abdomen with possible trauma to the stoma and skin as a result. Trauma to the stoma may cause leakage. Percutaneous endoscopic gastrostomy (PEG) tubes are longer and allow connection to take place well away from the stoma and delicate abdominal skin.

Some children and adults with dystrophic EB develop delayed gastric emptying, which encourages leakage from the site. In severe cases gastrostomy feeding is not tolerated and jejunal feeding may be necessary. The gastrostomy is replaced with a gastro-jejunal device. Although jejunal feeding allows adequate delivery of nutrition, the gastrostomy will continue to leak gastric contents.

Jejunal feeding requires a sterile technique to be used and certain medications commonly given via a gastrostomy cannot be delivered via the jejunal route. Systemic treatments with H₂-receptor antagonists and proton pump inhibitors can be used singly or in combination to reduce the acidity of the gastric contents.

TABLE 9 Gastrostomy site management

Type	Brand	Manufacturer	Indications/function	Contraindication/comments
Barrier	Proshield® Plus	H&R Healthcare	Protection	Some patients may experience stinging when applied to very raw skin Avoid contact with gastrostomy device. Can make retention of dressings difficult
	Equal parts of sucralfate/ Cavilon™ (3M)	In-house pharmacy manufacture		
	Cavilon™ Durable Barrier Cream/ No Sting Barrier Film (spray)	3M		
	Sillesse™	Trio Healthcare		
	Medihoney™ Barrier Cream	Derma Sciences		
	50% white soft/50% liquid paraffin			
Soft silicone mesh	Mepitel®	Mölnlycke Health Care	Wound contact layer	Use double layer with the pores in the mesh non-aligned if over- granulation tissue present Silflex: Adherence may be too strong for very fragile skin
	Silflex®	Advancis Medical		
Lipido-colloid	Urgotul®	Urgo Medical	Wound contact layer	Dictated by condition of wound/ patient preference

TABLE 9 continued...

Superabsorbent	Sorbion Drainage® Curea P1® Drain Sorbion Sana® Cutimed® Siltec® Flivasorb® Curea P1® Eclipse®	Sorbion Curea Medical Sorbion BSN medical Activa Healthcare Ltd, an L+R company Bullen Healthcare/Curea Medical Advancis Medical	Leakage Excessive leakage	Use over primary dressing Use over superabsorbent drainage dressing (applies to all products except drainage dressings)
Steroid	Maxitrol® eye ointment Dermovate™ Cutivate®	Alcon Laboratories GlaxoSmithKline UK PharmaDerm	Overgranulation tissue	As required
Anti-fungal topical	Nystaform® Canesten®	Typharm Bayer	Yeast infection	To treat Candida infection following cultivation on swab
Anti-fungal topical with steroid	Nystaform® HC Canesten® HC Trimovate® Timodine®	Typharm Bayer GlaxoSmithKline UK Alliance Pharmaceuticals	Yeastl infection	To treat Candida infection and reduce inflammation
Oral antifungal	Fluconazole (Diflucan®)		Persistent Candida	Where topical treatment is ineffective

TRACHEOSTOMY MANAGEMENT

In our centres very few patients with EB have tracheostomies, but we have experience of their management both in dystrophic and junctional EB. The main problem for the skin is protection from the tightly fastened securing tapes (*Table 10*). The stoma site requires protection from the phalange of the tube and the tapes can cut into the back of the neck particularly in young infants where the neck is short. Use of a suitable barrier product (eg Proshield Plus, H&R Healthcare) may be helpful to protect vulnerable skin.

The proximity of the tube in relation to the underside of the chin in small infants can lead to wounds on this area and an extension to the tube should be considered to avoid this (*Figure 6*).

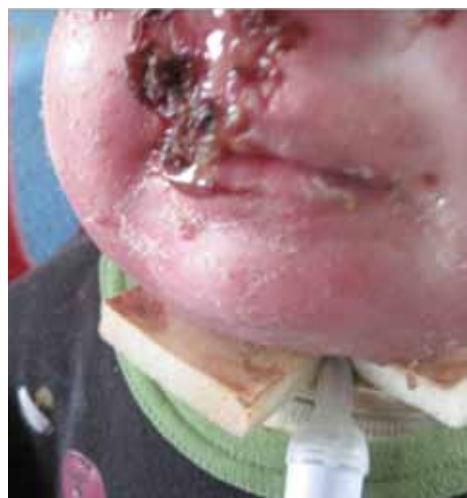

Figure 6. When using a tracheostomy tube in small infants an extension tube may be needed to prevent it rubbing under the chin.

TABLE 10 Tracheostomy care

Brand	Product	Manufacturer	Indications/function	Contraindication/comments
Lipido-colloid	Urgotul®	Urigo Medical	Wound contact layer Use underneath tapes	Use wide strip to prevent embedding
Soft silicone mesh	Mepitel®/Mepitel® One Silflex®	Mölnlycke Health Care Advancis Medical	Wound contact layer Use around stoma site	Overgranulation tissue (if soft silicone is required use a double layer with pores in mesh misaligned) Silflex: Adherence may be too strong for very fragile skin
Soft silicone foam	Mepilex® Transfer Mepilex® Lite	Mölnlycke Health Care	Use over Urgotul® under tapes	
Polymeric membrane	PolyMem®	Ferris	Around stoma site for cleansing and protection	Check with tracheostomy nurse regarding thickness of dressings for safety reasons to avoid risk of decannulation

MANAGEMENT OF HEAD LICE INFESTATION

Infestations of head lice are common among school children worldwide. However, treatment is not always effective and options are limited, even for those with a healthy skin and scalp, while resistance to insecticides is an increasing problem [42, 43] (See *Case Report* page 36).

Management of lice in those with EB can be difficult and may result in excoriation of the scalp, infection and hair loss. Simple measures should be deployed initially. Many children have been treated at the EB Centre at Great Ormond Street Hospital, London, where Dermol™ 500 lotion (Dermal Laboratories), an emollient containing an antimicrobial agent, has been found to be effective. This can be applied to the hair and scalp before being combed out with a fine-toothed comb. If proprietary insecticides are used, all wounds, blister sites or areas of excoriation on the scalp should first be protected using a thick layer of Vaseline® (Unilever).

If the lice cannot be controlled quickly by using the above methods there is a danger that scratching the scalp will lead to infection, permanent hair-loss and problematic crusting. The lice live under the crusts found on the scalps of many people with severe forms of EB, making mechanical or chemical elimination impossible.

An alternative is the drug ivermectin, which selectively binds to specific neurotransmitter receptors of the peripheral motor system of invertebrates [44]. This treatment is also effective in the management of scabies and again eliminates the need for insecticides to be applied to fragile skin. The drug is not recommended for those weighing less than 15kg.

MANAGEMENT OF CHRONIC WOUNDS IN EB

The most important tool at the clinician's disposal when dealing with non-healing wounds is to try to establish the cause of the chronicity. Although this sounds obvious, it is often easy in the context of severe EB to be overwhelmed by the wide variety of presenting wound-related problems.

The most common causes of chronic wounds in EB are likely to be:

- High bioburden (critical colonisation)
- Frank infection due to the loss of the protective function of the skin with large wounded areas and intense pruritus leading to destructive scratching [45, 46]
- Presence of necrotic material, commonly soft slough
- The disordered cellular activity seen in all chronic wounds
- Poorly controlled exudate with extremely alkaline exudate which is a wounding agent in its own right [47]
- The suspected presence of a biofilm will inhibit wound healing and should be suspected in non-healing EB wounds. A biofilm is a multi-species microbial community that secretes a protective matrix, which makes identification on traditional wound swabs impossible. Treatment by systemic antibiotics or topical methods will be ineffective [48]
- The margins of chronic wounds in EB are frequently hyperkeratotic with the presence of dried crusty exudate and this devitalised tissue will inhibit the migration of epidermal cells from the wound edges [49]
- There is evidence to support the notion that skin stem cells become 'exhausted' in their never-ending battle to heal wounds [50]

- Pressure and friction will contribute to wound chronicity and pressure relief may be required
- Inappropriate product usage can contribute to wound chronicity.

Beyond the wound the whole patient must be considered and the context in which the wound healing is failing to take place must be assessed and addressed. Anaemia and malnutrition will have a negative impact on the patient's ability to heal. Pain also affects the patient's ability to heal, and this may arise from sources other than the wounds. Pruritus may contribute, with scratching frequently leading to the breakdown of newly-healed or healing skin.

WOUND BED PREPARATION AND EB

Wound bed preparation (WBP) is a familiar concept for all clinicians working with patients living with a wound and this concept is equally applicable to chronic wounds seen in patients with EB. It is not the purpose of this document to re-state this concept but, briefly, the principle of WBP is to remove barriers to healing and to create an optimal wound healing environment. TIME is a framework that can be used to apply the principles of WBP in practice [51]. This comprises the following components:

- **Tissue** — the wound bed should be free of necrotic material
- **Infection or inflammation** — the bacterial burden should be controlled by systemic or topical therapies. Inflammatory stimuli due to scratching seen in recalcitrant pruritus in EB may be difficult to manage effectively
- **Moisture** — excess exudate should be controlled resulting in a moist wound bed and preservation of the periwound skin
- **Epithelial advancement** may be inhibited by abnormal cellular activity within the wound.

T — Tissue

Debriding necrotic tissue

This may be an ongoing process in a chronic wound and so-called 'maintenance debridement' may be required. There are four main debridement options (Table 11):

- **Autolytic debridement** — this is a normal process within a wound whereby proteolytic enzymes and macrophages remove necrotic material. Some dressings can enhance this process.
- **Sharp debridement** is performed in theatre.

However, this is not usually an option in EB due to the fact that most of the chronic wounds are exceptionally painful and bleed profusely.

- **Mechanical debridement** can be as simple as wound cleansing or the use of a debridement pad (Debrisoft®, Activa Healthcare Ltd, an L+R company) to remove sloughy tissue. In some centres whirlpool baths have been used with good effect to cleanse wounds and skin for patients with EB and remove necrotic material. Appropriate analgesia must be given prior to attempting mechanical debridement.
- **Larval therapy** to remove necrotic material has been successful, particularly since the larvae have been available in a 'tea-bag' presentation, rather than free range which led to difficulties in containment given that adhesive products cause skin damage. However, larval therapy can cause pain in some patients.

I — Infection/critical colonisation

In all forms of EB, skin fragility may result in bacterial colonisation or infection, particularly in the more severe forms where wounds may be multiple and long-standing. This is because the body has lost some of its first-line defences against microbes. The increased bioburden in critically colonised or infected wounds impairs healing and therefore recognition of these situations, and appropriate measures to promote a healing environment, are fundamental to the care of EB wounds [52] (see Table 12).

M — Moisture control (exudate management)

Exudate is frequently difficult to manage in chronic wounds seen in patients with EB (Table 13). This is because of the quantity of exudate and the fact that it is often highly viscous. The high viscosity can mean there are difficulties with absorption into the dressing, leading to pooling under dressings causing damage to the wound bed and the surrounding skin. It should be noted that most dressings' absorptive capacity is demonstrated using a low viscosity fluid.

The ability of a dressing to manage exudate is also affected by its ability to 'vent' excess fluid from the back of the dressing. Dressings with a backing which allows for a high moisture vapour transmission rate (MVTR) will greatly assist in the management of wound exudate.

TABLE 11 Recommendations for wound debridement in patients with EB

Dressing type	Brand	Manufacturer	Indications/function	Contraindications/comments	Wear time
Autolytic debridement					
Hydrogel	Many available Equal parts of liquid paraffin and white soft paraffin	No specific brand recommended	Dry necrotic material	Be aware of additional moisture causing maceration Can be used to debride hyperkeratosis and areas of dried exudate. Remove once softened with plastic forceps	1-3 days Take care not to damage viable tissue or cause pain
Honey (medical-grade only)	Various: in ointment, sheet or impregnated dressing	No specific brand recommended	Dry necrotic material. Soft slough	Can cause stinging and pain. Can increase exudate. May need superabsorbent secondary dressing	Change when strikethrough noted
Sheet hydrogel	ActiForm-Cool®	Activa Healthcare Ltd, an L+R company	As above particularly in keloid type scarring seen in EB pruriginosa	Be aware of product drying out and adhering to wound bed	Change when product becomes discoloured
Hydrofiber®	AQUACEL®	ConvaTec	Soft slough	Be aware of product adhering to hyperkeratotic material at wound margins (eg the wound can be wet, but still have dry margins)	Change when gel formed
Foams	PolyMem® Mepilex®/ Mepilex® Border ALLEVYN™ Gentle / Gentle Border	Ferris Mölnycke Health Care Smith & Nephew	Soft slough Soft slough Soft slough	Be aware of initial increase in exudate Use bordered products where skin not so fragile. Be aware of potential for maceration if not changed frequently enough. May need SMAR to ease removal As above	Daily initially then decreasing frequency as per exudate levels Dictated by exudate levels 1-3 days
Sharp debridement in theatre by a plastic surgeon under general anaesthesia					
Enzymatic debridement (not currently used for EB)					
Mechanical debridement					
Method	Brand	Manufacturer	Indications/function	Contraindications/comments	
Debridement pad	Debrisoft®	Activa Healthcare Ltd, an L+R company	Soft slough	Can cause pain/discomfort	
Irrigation and wound cleansing	Prontosan® Octenisan® Potassium permanganate	B. Braun Schülke Various	Hyperkeratosis and dried exudate Soft slough	Apply to the wound and leave for 10 minutes	
Whirlpool baths		Various	Soft slough, hyperkeratosis and dried exudate	Can cause pain/discomfort. Not readily available	
Larval debridement					
Sterile maggots	LarvE® (free range larvae or contained in a mesh pouch with foam)	BioMonde	Soft slough and necrotic tissue	Not to be used in patients with clotting disorders, on anticoagulant therapy, or on wounds with exposed blood vessels or that bleed easily Free-range maggots must be contained within the wound bed. All maggots must be kept moist. May reduce patient distaste if contained in a pouch. Larval therapy may cause pain	

TABLE 12 Recommended antimicrobial treatments for infected and critically colonised wounds

First choice of treatment when available: PolyMem®, Flaminal®

Dressing type	Brand	Manufacturer	Indications/function	Contraindication/comments	Wear time
Enzyme alginogel	Flaminal® Hydro (light to moderate exudate) Flaminal® Forte (moderate to heavy exudate)	Crawford Health-care	Debrides, de-sloughs and is antimicrobial. Has some action in modulating excess proteases	Can be used on all wounds apart from third degree burns. Do not use if patient has sensitivity to alginates or polyethylene glycol	Reapply at each dressing change. This should be carried out as dictated by condition of wound
Honey	Algivon	Advancis Medical	Malodorous wounds. Chronic wounds where biofilm may be present	General note: Only use medical, gamma-irradiated products due to risk of transmission of botulism spores. On occasion, pain levels can be initially increased by the application of honey. Honey is difficult to use in warmer climates where there is poor hygiene/sanitary conditions and no conditioning and where insects are rife May need to use it over a recommended primary dressing to ensure non-adherence. Can sting	Up to four days depending on patient choice. May need to change secondary dressing more frequently due to increase in exudate For Medihoney™ Gel Sheet replace when no evidence of gel sheet remains Apply at each dressing change
	Medihoney™ Antibacterial Gel Sheet (for sensitive wounds)	Derma Sciences	Sensitive wounds where dressing removal is difficult		
	Mesitran® Ointment S	Aspen Medical	Sensitive wounds		
Polyhexamethylene biguanide	Suprasorb® X + PHMB	Activa Healthcare Ltd, an L+R company	Infected wounds (particularly those that are painful or itching)	May provide a cooling effect to help reduce pain and a mechanical barrier to scratching. Can sting	Daily for optimum pain relief and cooling effect
	Prontosan® Wound Irrigation Solution/Wound Gel/Gel X	B. Braun	Regular cleansing, rehydrating and removal of bacteria and debris	Apply to the wound and leave for 10 minutes	Apply at each dressing change. The gel can be applied to the wound and covered with a suitable secondary dressing
	Octenisan®	Schülke	Body wash every day as a liquid soap, for a shower, bath or washing		
DACC	Cutimed® Sorbact®	BSN medical	Use over atraumatic primary dressing (a soft silicone mesh or lipido-colloid)	Better for prevention rather than treatment of infection	As dictated by strike-through on secondary dressing
Polymeric membrane	PolyMem®	Ferris	Note: Not marketed as an antimicrobial, but has been found to be effective in infected wounds	May provoke initial increase in exudate and frequent changes may be required. This should decrease with time	When strikethrough observed
Hydrogen peroxide	Crystacide®	Derma UK	Superficial infection		
Silver	PolyMem® Silver Mepilex® Ag	Ferris Mölnlycke Health Care	Infected wound where foam dressing is required	Silver products should be used with caution in infants under one year. Also potential risk of raised plasma silver levels /argyria. Restrict use to 14 days and apply to a small area for short-term use only	Every 3–4 days or as dictated by strikethrough or personal preference
	Urgotul® Silver/SSD	Urgo Medical	Primary dressing		
	AQUACEL® Ag	ConvaTec	EBS-DM		
	FLAMAZINE™ (silver sulfadiazine)	Smith & Nephew	Short-term use only		
Povidone iodine	INADINE®	Systagenix	Short-term use only	With caution in paediatrics, pregnancy and breast-feeding because of risk of thyroid suppression. Do not use when receiving lithium	When colour leached
Cadexomer iodine	IODOFLEX™ IODOSORB™	Smith & Nephew	For use on chronic exuding wounds, will assist in the removal of wet necrotic material (slough)	With caution in paediatrics, pregnancy and breast-feeding because of the risk of thyroid suppression. Do not use when receiving lithium	IODOFLEX™ is a paste which should be covered with an absorbent pad. Daily changes required initially. IODOSORB™ is an ointment. Change frequency as above
Metronidazole gel	Numerous brands available		Malodorous wound/ anaerobic infection/ fungating wounds	Recommended for short term only unless in palliative care. Most effective in HJEB for malodour	With dressing change

*Table adapted from Denyer J Wound management for children with epidermolysis bullosa. *Dermatol Clin* 2010; 28: 257–264.

TABLE 13 Moisture/exudate management

First choice of dressing when available: Cutimed® Siltec®, PolyMem® Max

Dressing type	Brand	Manufacturer	Indications	Contraindication/comments	Wear time
Foam	Mepilex®/ Mepilex® Border	Mölnycke Health Care	Low–moderately exuding wounds	Silicone sensitivity. Poor absorption of highly viscose exudate	Change when strikethrough noticed
	Mepilex® Transfer with secondary padding	Mölnycke Health Care	Moderate–highly exuding wounds	Silicone sensitivity	Change secondary padding when wet
	ALLEVYN™ Gentle/Gentle Border range	Smith & Nephew	Moderate/ highly exuding wounds	Silicone sensitivity for border range	As dictated by exudate levels
Specialised foam	PolyMem® Max/ PolyMem® WIC	Ferris	Moderately/ heavily exuding wounds	Contains a highly absorbent starch	Change when wet/ heavy
Superabsorb- ent	Cutimed® Siltec® Sorbion® Flivasorb® Kerramax® Eclipse® Curea P1®	BSN medical Sorbion Activa Healthcare Ltd, an L+R company Crawford Healthcare Advancis Medical Bullen Healthcare/ Curea Medical	Heavily exuding wounds	Arterial bleeds	Change when wet/ heavy

In addition, adhesive dressings which may have provided a 'seal' around a wound, thereby containing the exudate, cannot be used, because of the potential for skin stripping on removal.

E — Epithelial advancement

The wound care practitioner may have addressed all the causes of chronicity, and may now have a wound bed which appears healthy, but the wound can still fail to epithelialise. The practitioner may then have to consider such factors as dressings-induced trauma, particularly if dressings are adherent, or are changed with inappropriate frequency. The wound margins may be inhibited from progression by the presence of callus and hyperkeratosis.

A further consideration is the concept of skin stem cell exhaustion as mentioned previously [50].

Management of the periwound skin

The periwound skin in all patients with chronic wounds is vulnerable to further damage and this is particularly so in EB

where a large area of the skin can be considered periwound, while other unbroken areas are vulnerable to damage and breakdown because of the nature of the condition itself.

Chronic wound exudate is potentially corrosive to intact skin and is itself a wounding agent. Maceration of the periwound skin with wound extension is common particularly in areas where exudate drains downward. Red fiery excoriation also leads to skin breakdown and increases pain.

Choosing a dressing appropriate to the level of exudate is of crucial importance. A dressing should be selected that provides protection by absorbing exudate and holding the moisture within the dressing. Some dressings also protect against lateral wicking of exudate across intact skin.

The frequency of dressing change is also important in protecting the periwound skin as damage from maceration can result if the dressing change frequency is inappropriate for the volume of exudate.

Some dressings (eg PolyMem®, Ferris; PROMOGRAN® and PROMOGRAN PRISMA®, Systagenix) may initially increase the level of exudate and require more frequent dressing changes.

At dressing changes the periwound skin should be gently cleansed to remove exudate. Adhesive dressings should be routinely avoided in EB to prevent skin stripping — even dressings with low adherence may need to be used with caution in patients who have extremely fragile skin.

A variety of topical products can be used to protect the periwound skin when it is thought to be vulnerable (Table 14). Padding of vulnerable areas, particularly those that are scarred, may also help prevent further injury and skin breakdown.

Other advanced therapies, directed towards wound healing such as injected fibroblasts, bone marrow transplants, and gene corrected skin grafts are also being used in limited numbers of EB patients within research trials. This is a rapidly developing field (Table 15).

On occasion the aim of management may not be to heal the wound, which may prove beyond the skills of the most able of practitioners, but to effectively manage the wound-related symptoms, ie exudate, infection, odour and pain, as well as providing a dressing regimen that is acceptable to the patient and carer [53].

TREATMENTS OF CHOICE FOR CHRONIC WOUNDS IN EB

Table 15 highlights wound care products that have been particularly helpful in either improving or healing stalled wounds in EB at the London EB Centres. Dressing choice will, of course, depend on the complete clinical picture following an holistic assessment.

TABLE 14 Recommendations for the management of periwound skin

Type	Brand	Manufacturer	Indications/function	Contraindications/comments
Barrier creams	Cavilon™ Durable Barrier Cream	3M	Barrier against body fluids	Avoid use under adhesive products as it can increase adhesion. Barrier creams may interfere with the ability of soft silicone products to adhere properly to the skin and may exacerbate lateral wicking of exudate
	Proshield® Plus	H&R Healthcare		
	Medihoney™ Barrier Cream	Derma Sciences		
	Equal parts of liquid paraffin and white soft paraffin	Various		
Barrier films	Cavilon™ No Sting Barrier Film	3M	Barrier against body fluids	May prevent adherence of soft silicone products
	LBF® No Sting Barrier Film	CliniMed		
Cleansing agents	Proshield® Foam	H&R Healthcare	Can be used on both intact skin and wounds	Does not require rinsing from the skin
	Sillesse™ Skin Barrier Wipe	Trio Healthcare		

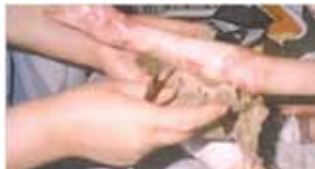TABLE 15 Advanced therapies for chronic wounds

Type	Brand	Manufacturer	Indications	Contraindications/comments
Bioengineered skin grafts	Dermagraft®	Dermagraft	Long-standing non-healing wounds	Careful wound bed preparation required. Expensive
	Apligraf®	Organogenesis		
Other products to consider				
Collagen dressings	Catrix®	Cranage Healthcare	For hard-to-heal wounds	May assist in improving anal fissures. May offer some pain reduction. Requires a secondary dressing. May produce an unpleasant odour. Of bovine origin therefore patients may refuse use for ethical or religious reasons
	Helisorb® Particles/ Neuskin-F™	Medira Ltd		

TABLE 16 Treatment of choice for chronic wounds based on consensus opinion

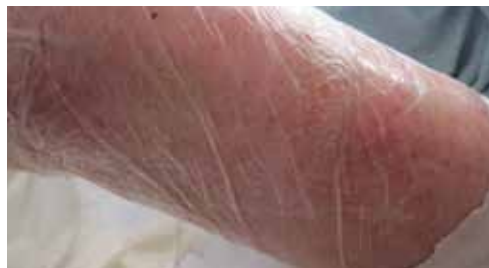First choice of treatment when available: PolyMem®, Flaminal® Hydro/Forte

Dressing type	Brand	Manufacturer	Indications	Contraindications/comments	Wear time
Polymeric membrane	PolyMem® PolyMem® Max PolyMem® Wic under a secondary dressing or a further layer of PolyMem®	Ferris	Infected wounds and those where healing has stalled	Can provoke an initial large increase in the volume of exudate and this can cause further skin damage if not properly controlled. Distinctive unpleasant odour is possible. To prolong wear, slash film backing before applying dressing to allow exudate to pass through dressing, put additional PolyMem Max dressing over the top and change the Polymem Max regularly leaving the wound contact layer undisturbed.	Dictated by exudate levels but will need frequent changing initially
Honey	Activon® Tulle/ Algivon/ Activon® Medical Honey	Advancis Medical	For sensitive wounds	Honey dressings can cause transient stinging or pain due to its acidity and high osmotic 'pull'. In turn this will contribute to high levels of exudate	As dictated by exudate levels
	Medihoney™/ Gel Sheet	Derma Sciences			
	Mesitran®	Aspen Medical			
	Mesitran® Ointment S	Aspen Medical			
Protease modulators	Urgotul® Start range	Urgo	When excess proteases may be present	A point of care diagnostic test (WOUNDCHek™ Protease Status test, Systagenix) can be used to check for elevated protease activity (EPA) in the wound	Frequent initial change may be needed
	PROMOGRAN® PROMOGRAN PRISMA® (with silver)	Systagenix			
Enzyme alginogel	Flaminal® Hydro	Crawford Healthcare	Light to moderate exudate	Debrides, de-sloughs and is antimicrobial. Has some action in modulating excess proteases. Can be used on all wounds apart from third degree burns. Do not use if patient has sensitivity to alginates or polyethylene glycol	Reapply at each dressing change
	Flaminal® Forte		Moderate to heavy exudate. For drier wounds		



Figures 7-9 (above). Melted fat is spread onto toilet paper; the toilet paper is wrapped around skin and wounds; it is easily removed without adherence.

Figure 10 (right). Clingfilm is applied directly to intact skin and open wounds.



UNORTHODOX METHODS OF WOUND CARE IN EB

While those with EB seen at centres in the UK are fortunate to have access to a great selection of dressings, others in less developed countries or where finances are limited must seek alternative methods of wound care.

Table 17 shows a few examples we have learned from resourceful families and healthcare professionals.

TABLE 17 Unorthodox treatment options for those with limited access to medical supplies

Type	Indication/function	Contraindication/comments
Clingfilm/clear food wrap	Open wounds/intact skin for protection. Use if no dressings available, or patient preference. See Figures 7-10	Apply antiseptic/antimicrobial ointment under film. Use padding between two layers of film for areas needing protection [54] Watch for over-heating
Cotton material/gauze	Open wounds/intact skin. Use if no dressings available	Spread with greasy emollient. Change frequently to prevent adherence
Cigarette papers	Wounds Use if no dressings are available	Change daily. Irrigate to remove or it will float off when bathing
Toilet paper spread with melted fat	Wrap around as a bandage. See Figures 7-10	Change daily if not bathing or allow to float off in bath

MANAGEMENT OF SQUAMOUS CELL CARCINOMA

In patients with the more severe forms of EB, notably RDEB-severe generalised, there is a high-risk of squamous cell carcinoma.

There needs to be a high level of suspicion that a wound may contain a squamous cell carcinoma. Where suspected, the wound should be biopsied and the sample should be examined by a histopathologist with experience of EB skin cancers, where possible. Suspicion should be aroused if:

- The wound has been present for more than three months
- There is exuberant tissue growth above the level of the surrounding skin
- It is ulcerated
- The wound has little feeling
- The wound is intensely painful, or crucially, the patient reports that it feels different.

Patients and their carers are frequently the first people to recognise that there is a problem and their concerns should be listened to. In the London EB Centres there is a very low threshold for biopsy as it is recognised that even wounds which may at first appear insignificant may in fact harbour squamous cell carcinoma.

MANAGEMENT OF FUNGATING WOUNDS

Patients with severe generalised recessive dystrophic EB, who are at the end of life as a result of an inoperable squamous cell carcinoma will often have a fungating wound [55]. They are generally unresponsive to chemotherapy, but radiotherapy may help in the palliation of symptoms [56, 57].

When caring for a patient who has a fungating or malignant wound the overall aim is to promote patient comfort and maintain or improve quality of life, by addressing the following issues:

- Pain
- Exudate
- Odour
- Bleeding
- Infection [58,59]

While use of multiple dressings should generally be avoided, the clinician caring for a patient with a malignant wound will frequently be required to use a variety of dressings 'layered up' to achieve optimal results. This is because the ideal dressing to manage the complex range of symptoms and challenges seen in fungating wounds has yet to be developed [60] (*Table 18*).

Frequent dressing changes should be avoided, both to prevent additional pain, discomfort and possible bleeding, which is common in fungating tumours as blood vessels are eroded by the growth of the tumour. Dressing changes should also be kept to a minimum to avoid possible distress to the patient and their carers by the visible appearance of the tumour and the potentially severe odour which may increase when the wound is exposed. This has to be balanced with the need for exudate management [60].

A careful, regular, structured assessment must be made of the effectiveness of the wound care regimen and adjustments made accordingly. Effectiveness may be assessed by the patient, carers and professional team [60, 61]. An interdisciplinary approach is imperative in ensuring that the patient receives the best possible care [61].

NOTE: Best Practice Guidelines for the Management of Squamous Cell Carcinoma in epidermolysis bullosa are being authored by Dr Jemima Mellerio and will be available via www.debra.international.com in the near future.

TABLE 18 Recommendations for the management of fungating wounds

Type	Brand	Manufacturer	Contraindications/comments	Wear time
Topical analgesia	Topical morphine (unlicensed)		10 mg morphine for injection in 10g of hydrogel. This dosage can be increased as required [62]. Evidence shows there is little if any systemic absorption, apart from when used over large areas [63]	Re-apply when analgesic effect diminished
	Biatain® Ibu	Coloplast	Do not exceed total daily dose of NSAIDs if patient is also taking systemically	As above
Barrier creams and films	See Table 14		Barrier against body fluids to prevent further destruction of periwound skin and reduce pain and pruritus in this area	As per exudate levels

TABLE 18 Recommendations for the management of fungating wounds continued

Debriding agents	Any hydrogel Honey as below	Various Various	Promotes autolytic debridement, however this will increase exudate levels and the gains must be balanced against the difficulties of managing extra moisture. Surgical debridement is generally not indicated due to the tendency of these wounds to bleed (see Special considerations below)	
Topical deodorisers	Metronidazole gel 0.75%/0.8% Activon® Tulle Medihoney™ Antibacterial Wound Gel Mesitran® Ointment	Various Advancis Medical Medihoney Aspen Medical	Can also be mixed with morphine to combat both pain and odour (unlicensed) Honey is very effective in combatting infection, odour and assisting in autolytic debridement. However, some patients may experience stinging or pain and the clinician should be aware that exudate levels may increase	Dictated by exudate levels and dressing wear time
Odour-absorbing dressings (the authors have used these dressings over a primary non-adherent layer. Many will also lose effectiveness when wet)	CarboFLEX® CliniSorb® Lyof foam™ C ACTISORB® Silver 220	ConvaTec CliniMed Mölnlycke Health Care Systagenix	Cannot be cut to size. Has a wound contact layer and some absorbency Apply over primary dressings. Will lose odour-absorbing capacity when wet Secondary foam dressing with activated carbon. Has absorption-activated charcoal cloth which cannot be cut. Intended as a primary dressing Cannot be cut to size (due to release of activated charcoal) and contains silver to assist with infection control	Dictated by exudate levels
Systemic antibiotics	Various	Various	As per clinical presentation/swab results. May be effective in reducing pain, odour and levels of exudate	
Non-adherent primary dressings	Urgotul® Mepitel® Mepilex Transfer	Urgo Mölnlycke Health Care Mölnlycke Health Care	The fine weave of this dressing make this the first choice of primary dressing for a delicate fungating wound Highly conformable foam dressing which allows for passage of exudate through to a secondary dressing	Up to 7 days but this is unlikely as exudate levels may dictate daily changes
Absorbent dressings	AQUACEL®/ AQUACEL® AG Mepilex®/Lite Lyof foam® C	ConvaTec Mölnlycke Health Care	Multiple layers (as determined by exudate levels) may provide a soft highly conformable secondary dressing. Do not apply direct to the wound as it may adhere Can be used over a Hydrofiber® to provide a barrier to strikethrough Use as a secondary absorbent layer where odour is a problem	Dictated by exudate levels
Bandage/retention	K-Band® Hospiform® Slinky™	Urgo Hartmann Mölnlycke Health Care	There are a large variety of retention bandages available and the choice depends on patient choice, comfort and availability. The bandage should not put additional pressure on the wound but must be firm enough to prevent the dressings slipping. Tubular bandages can also be used	
Special considerations for bleeding: Careful cleansing and avoidance of adherent dressings can help prevent bleeding. It is useful and reassuring to the patient/family to have a small supply of haemostatic products in the home				
Alginates	Kaltostat® Sorbsan®	ConvaTec Aspen Medical	Haemostat Haemostat	
Haemostatic sponge	Spongostan	Johnson & Johnson	Haemostat	
Sucralfate paste	1g mixed with KY Jelly		Self-mixed	
Adrenaline 1:1000			Applied topically. Used with great caution and under medical supervision. Can cause local necrosis and be absorbed systemically	
Palliative radiotherapy			Can reduce tumour size	

GENERAL MEASURES FOR END-OF-LIFE CARE

Analgesia and symptom management

Pain and symptom management will generally be managed by the palliative care team. However, generally there is a requirement for fast acting analgesia for dressing changes. A regular review of the patient's pain levels is crucial.

Syringe drivers

Syringe drivers are well tolerated in EB and can be secured with a soft silicone tape (e.g. Mepitac®, Mölnycke Health Care or Siltape®, Advancis Medical).

Analgesic 'patches'

These can be used even in severe EB and can safely be removed with a silicone medical adhesive remover (SMAR).

Amputation

Our experience of upper and lower limb amputation is that they generally heal well. However, there are difficulties in fitting a prosthesis, particularly if this is on the lower limbs where pressure will potentially provoke skin damage.

With the aid of specialist prosthetists, well briefed on EB, patients have been supplied with prostheses with a mixed degree of success. One patient had a prosthetic leg, which he wore successfully for the last two years of his life. This was fitted a few weeks post-surgery when good healing had been achieved. A silicone liner was used to protect the stump. The patient did report blistering and skin breakdown, but he felt this was no more than he would have experienced on his own foot. Another patient, a young woman with EB, rejected an arm prosthesis, as the perfect prosthetic hand looked nothing like her own contracted and scarred hand.

Pressure relief and manual handling

One of the difficulties faced by patients with a severe form of EB, combined with a malignant wound and possible limb amputation, is simply moving in order to reduce pressure and possible skin damage. There are also potential difficulties in moving patients for procedures eg for radiotherapy or for toileting.

Lateral transfers

For lateral transfers the use of a 'HoverMatt®' (HoverTech International) can be invaluable. This equipment is recommended for all lateral transfers when caring for EB patients who are unable to move themselves. The patient is placed on the 'HoverMatt®' (HoverTech International) which is then inflated using an electronic pump. The mattress is then moved across a solid surface and deflated when the patient is on the desired surface. Thus the patient is not at risk of skin damage.

Pressure redistribution

When the requirement for pressure relief is of low to moderate risk, the 'Repose®' mattress (Frontier Therapeutics) may provide a cost-effective solution which is acceptable for most people with EB.

When the risk of pressure damage is high (such as at the end of life), a low air-loss system is very effective. As there is likely to be high levels of wound fluid, which may leak into the bed, a system which combines a Gore-Tex® sheet, allowing low air loss and moisture management, may be useful [64]. The TheraKair Visio™ low air loss mattress (KCI) is recommended although some patients may not accept this as movement is made more difficult once they are on the mattress.

Toileting

This is always challenging when patients near the end of life. For urinary control 'slipper' bed pans or a device called a 'Shewee' (Shewee Ltd) can be used. Alternatively, a well lubricated urinary catheter can be inserted. The latter is generally contraindicated in severe EB, but at the end of life any resultant minimal damage has to be balanced with the patient's comfort.

Bowel management can be very challenging and pads or nappies may be required if the patient is unable to sit on a bed pan or commode. On occasion, patients have developed diarrhoea in the palliative phase. This is a very difficult circumstance and, on occasion, dressings that are likely to be soiled can be protected with commercial clingfilm to avoid further distressing dressing changes. When the patient is near the end of life, bowel movements generally cease.

CATASTROPHIC BLEEDING

This is a rare event and various methods for control or prevention are cited [65], however this is not within the scope of these guidelines. The following advice applies when it is concluded that there is no means of preventing a sudden large bleed which will almost certainly lead to the death of the patient.

A catastrophic bleed occurs when a tumour erodes through a major blood vessel and the ensuing bleed cannot be controlled, such that the patient will exsanguinate and die. Local policies must be followed when caring for a patient at risk of such a bleed and preparations must be made to manage the situation.

- Consider who to tell. Can the patient cope with this information? Although this has the potential to be a very shocking event it is better that the family and carers know and are prepared for the possibility
- Dark towels and sheets (dark blue or green may be less alarming than red or black) to camouflage the bleeding.
- Fast acting IV/IM sedation — midazolam or diamorphine
- Rectal diazepam
- It is important to stay with the patient to try and support them through this potentially terrifying event
- Local ambulance services should be informed that this is a possibility and they may be called to provide emergency support. A 'Do Not Attempt Resuscitation' (DNAR) form will be required. If the patient is being cared for at home the patient's GP can complete this form, or if the patient is hospitalised a consultant will complete the form. Careful discussion with the patient/family will be required [65].

The authors' experience is that catastrophic bleeds have been the final event for two out of 16 EB patients cared for over a period of 17 years. It was also predicted in another patient who in fact died of another cause. It is always difficult to manage, and may be preceded by heavy 'herald bleeds', which can cause a great deal of distress for the patient, family and carers. However, good care can be achieved by having a clear management plan.

Neonate with recessive dystrophic EB — severe generalised

This infant presented with skin fragility, wounds and nail dystrophy at birth. Analysis of a shave skin biopsy taken on day two showed total absence of type VII collagen which confirmed the diagnosis of severe generalised dystrophic epidermolysis bullosa.

Extensive wounds over the right leg and left foot involving both dorsal and planter aspects and de-gloving of all toes had been caused by a combination of damage from intrauterine movements and trauma from delivery. Further damage was caused by handling resulting in superficial wounds over his back, face and hands.

Treatment plan

The treatment objectives were to help the wounds to heal while minimising contractural scarring and attempting to avoid digital fusion.

Wounds were dressed shortly after birth using Vaseline®-impregnated gauze as a wound contact layer with several layers of dry gauze as a secondary dressing. Unfortunately the Vaseline® gauze dried out causing the dressings to adhere firmly to the wounds. Removal was aided by silicone medical adhesive remover spray but further skin stripping and trauma were caused.

The wounds were then dressed using soft silicone mesh as a primary dressing and soft silicone foam placed over the mesh to absorb exudate and offer protection against further trauma (*Figure 1*). These dressings were readily available and at the time were the standard initial management of severely affected neonates. These dressings were selected for atraumatic removal.

Strips of a Hydrofiber® dressing (AQUACEL®, ConvaTec) were placed between the toes to try and avoid digital fusion (*Figure 2*). Hydrofiber® is highly conformable and because it is very soft it will not cause trauma. It turns to a gel when in contact with moisture and can remain in place when placed between and around de-gloved digits.

After 21 days of dressing with soft silicone healing was slow and the exudate was offensive. The complexity of a two-layer dressing system meant prolonged dressing changes and therefore it was decided to change to polymeric membrane dressings (PolyMem®, Ferris).

PolyMem® is ideal for neonates because a primary dressing is not required, reducing the time taken to change dressings and therefore reducing pain and distress. The dressing contains a non-toxic cleanser (F68) which offers continual cleansing of the wounds, reducing the risk of infection. The cleansing is of particular value as bathing is not recommended until the birth damage has healed as it is not possible to protect from trauma during this procedure.

PolyMem® was wrapped around the legs and taped to itself and a two-way stretch tubular bandage (Tubifast®, Mölnlycke Health Care) was also used to secure the dressing and to prevent rubbing from the overlapping area of PolyMem and the edges of the securing tape.

Outcomes

Initially the PolyMem® dressing required changing daily due to excessive exudate and the resulting wetness which was at risk of lowering the baby's temperature. After that the dressings were changed every three days. The wounds remained clean and gradually healed over a period of eight weeks.

Unfortunately, during dressing changes on the neonatal unit Hydrofiber® strips were not always used to separate the toes and

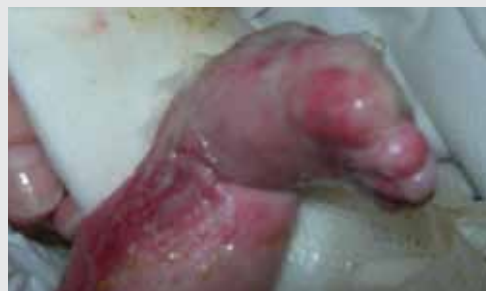

Figure 1. Patient at 18 days old. Soft silicone mesh and foam dressings were used to treat wounds.

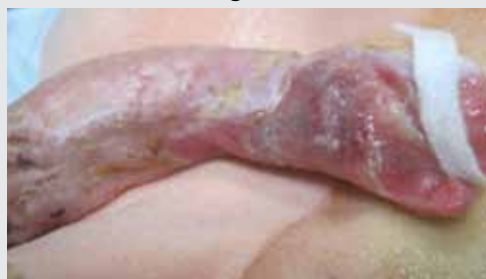

Figure 2. Strips of Hydrofiber® are placed between the toes (all toes except the great toe fused in this infant).

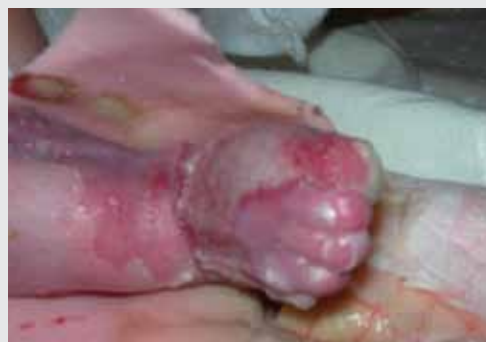
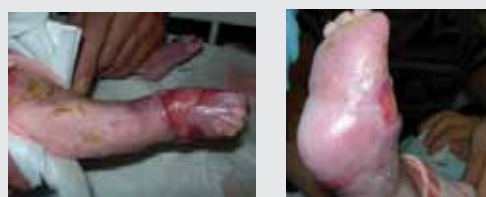
Figure 3. Patient at 28 days old after using polymeric membrane dressings.



Figures 4 and 5. Patient at 48 days old using polymeric membrane dressings.

digital fusion resulted on one foot. This can occur within 24 hours of two raw surfaces being in apposition.

This child has continued to use polymeric membrane dressings and at age three years has not had any infected wounds. Polymeric membrane is now our recommended dressing for neonates with extensive birth trauma.

Neonate with Herlitz junctional EB

The patient was three weeks old with a diagnosis of Herlitz junctional EB. There was blistering around the umbilicus and inflammation around the nail beds that had been present at birth and they were dressed with soft silicone foam. The blistering had spread across the abdomen and sides (*Figure 1*). Healing was compromised because of continual friction from the nappy edges. As expected with this type of EB the infant developed laryngeal blistering, weight loss and anaemia.

Treatment plan

The objectives were to promote comfort, to avoid the spread of further blistering and to reduce friction affecting the wound area. The products chosen were 50% liquid/50% white soft paraffin in ointment or spray form (Emollin® spray) for cleansing the nappy area and hydrogel impregnated gauze (IntraSite* Conformable, Smith & Nephew) to the lesions in the nappy area (*Figure 2*). The remainder of the wounds remained dressed with soft silicone products. Morphine in a hydrogel was used as a topical analgesia.

Within a few days the lesions were much improved and were healed within one week. Pain scores at nappy changes were low but crying was noted when the hydrogel impregnated gauze was applied. This was thought to be because of the shock of the cold wet gauze contacting her warm skin. Dressings were changed with each nappy change.

The wounds and blister sites on her sides and abdomen were deteriorating and therefore dressing management changed from soft silicone products to hydrogel impregnated gauze. Hydrogel impregnated gauze was initially just used in the nappy area and then introduced in place of soft silicone dressings to all other areas at age three weeks. As these wounds were not under the nappy and the gauze was at risk of drying out, lipido-colloid dressings (Urgotul®, Urgo) were placed under the hydrogel impregnated gauze. Retention was achieved by a two-way stretch tubular bandage (Tubifast®, Mölnlycke Health Care). Dressings were initially changed daily but as the disease progressed and the infant became weaker these were reduced to every 2-3 days depending on her level of tolerance.

Outcomes

All lesions healed within four weeks and pain at dressing changes was reduced. The wounds remained clean. New blisters and wounds occurred only occasionally and these healed rapidly despite the progressive cachexia and breathing impairment. The infant died aged 14 months but the skin was largely intact before her death (*Figure 3*).

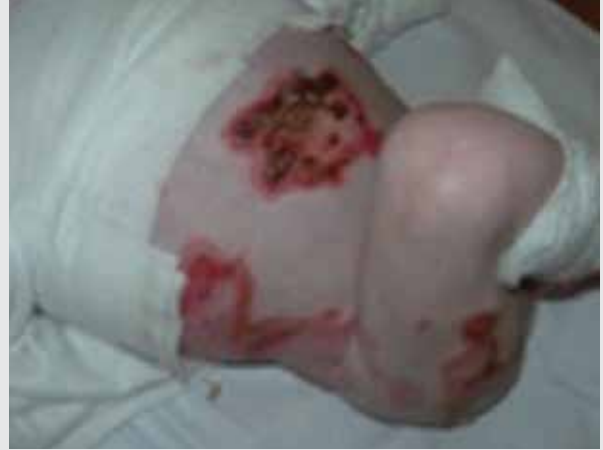

Figure 1. Patient aged three weeks using soft silicone mesh.

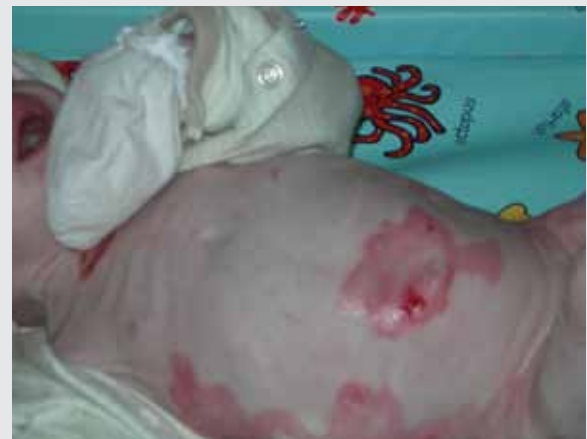

Figure 2. Patient aged six weeks after switching to a hydrogel impregnated gauze.

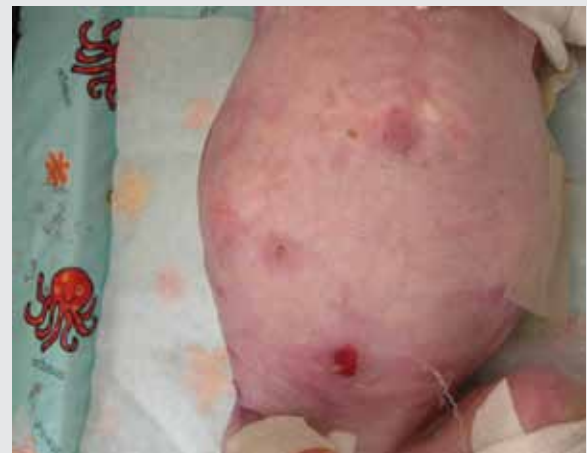

Figure 3. Aged 13 months following treatment with a lipido-colloid as a wound contact layer with a hydrogel impregnated gauze as a secondary dressing.

Chronic facial wounds in a patient with Herlitz junctional EB

Herlitz junctional EB is generally fatal in the first few weeks or months of life. Those who survive for longer than this have a tendency to develop large areas of ulceration particularly on the face. Overgranulation is a particular feature in all types of junctional EB.

In this case, an infant with HJEB developed a large ulcerated area on his face. This lesion started when he was a few months old and was exacerbated by constant trauma from rubbing his face, contamination with food and resisting suction from his tracheostomy. By the age of one year the wound covered his entire face and extended to beneath his chin (*Figure 1*). There was a large amount of overgranulation tissue which was very friable and bled easily. It was not safe to dress these wounds as the constant rubbing would dislodge the dressings which could then occlude the tracheostomy.

Treatment plan

The objectives of the treatment were to reduce the overgranulation tissue, minimise colonisation and prevent the wound from extending. The products selected for this were a topical antimicrobial and a very potent topical steroid ointment. Initially Flaminal® Forte (Crawford Healthcare) was applied daily to reduce the bioburden and then Dermovate™ NN (GSK) — an ointment containing clobetasol, neomycin and nystatin — was applied once a day 12 hours after the dressing application. It was necessary to monitor the patient's blood pressure due to possible absorption of highly potent steroid ointment. It was also important to avoid contact of the steroid ointment with the eyes as there was a risk of glaucoma.

Cleansing of the wound was attempted using Debrisoft® (Activa Healthcare Ltd, an L+R company) but the infant resisted this and so it was used to wipe away food residue.

Outcomes

The overgranulation tissue gradually reduced and healing took place. Flaminal was applied for four weeks only then Dermovate™ NN on a daily basis. The quality of the healed skin was good and it resisted blistering. By two years of age the patient's lower face had healed (*Figure 2*) although the top of his nose and forehead remained fragile with a tendency for the skin to break down when he rubbed these areas.

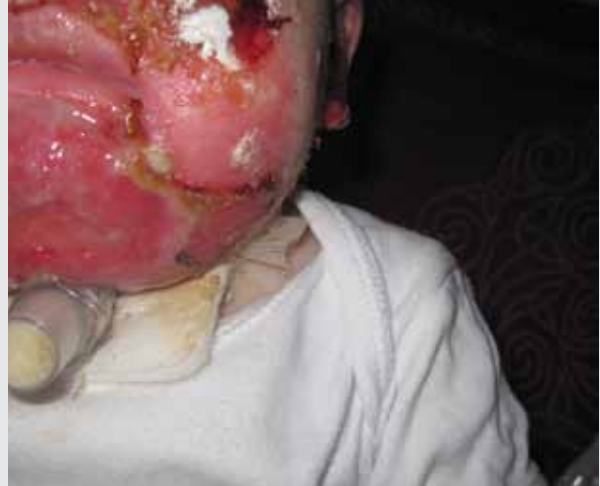

Figure 1. Aged one year. Flaminal® Forte was applied for four weeks only then Dermovate™ NN on a daily basis.

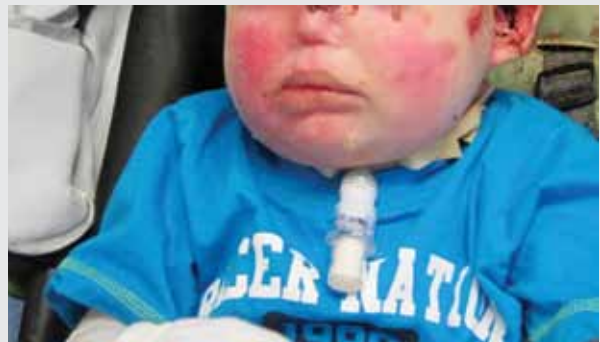

Figure 2. At age two the facial wound was largely healed and the skin resisted blistering.

Wound caused by leakage from a gastrostomy in a patient with severe generalised dystrophic EB

Supplementary enteral feeding is necessary for many children and adults with severe forms of EB. In particular, those with severe generalised dystrophic EB require gastrostomy feeding to meet their increased nutritional requirements in addition to the difficulties in swallowing experienced by many due to repeated oesophageal strictures. One of the complications of gastrostomy feeding in this group is leakage of stomach contents onto the fragile surrounding skin. Leakage is difficult to control as it is partly caused by inflammation within the stomach wall leading to delayed gastric emptying. The excessive leakage of both enteral and oral feeds can compromise nutritional status. Jejunal feeding via a gastro-jejunal tube ensures adequate delivery of nutrition, but does not solve the problem of the leakage of stomach contents.

Case report

The patient was 12 years old and had a wound 5cm x 5cm around her stoma site and deep excoriation extending across her abdomen, sides and back caused by continual leakage of stomach contents from the gastrostomy site (*Figure 1*).

Medical management included systemic treatments of proton pump inhibitors and H2-receptor antagonists and topical application of barrier products. Healing was continually compromised by the constant leakage of acidic stomach contents onto excoriated skin.

Treatment plan

The leakage could not be prevented despite all attempts to correct the problem. The aims of treatment were to ease pain and prevent the extension of the wound and further excoriation. The product chosen was a super-absorbent drainage dressing (Sorbion Sachet S[®] drainage dressing, Sorbion).

The wound was cleansed with saline and then a topical barrier was used (Proshield Plus[®], H&R Healthcare). The primary dressing was a lipido-colloid (Urgotul[®], Urgo) selected for its non-adherent properties, conformability and comfort. Sorbion Sachet Drainage and Sorbion Sana were used as secondary dressings. Sorbion Sachet Drainage was placed around the gastrostomy device to absorb stomach contents as they leaked and the Sorbion Sana placed on top as the drainage dressing was unable to absorb the large volume of fluid. A tubular bandage was used for retention.

Outcomes

Leakage continued but was contained with the superabsorbent dressings. Clothing remained dry which was important to the patient. Over the course of six weeks the wound decreased in size to a 1cm x 1.5cm area beneath the gastrostomy button and the large area of excoriation healed (*Figure 2*). Pain scoring on the Wong Baker Scale dropped from 10 to two during both dressing changes and wear time.

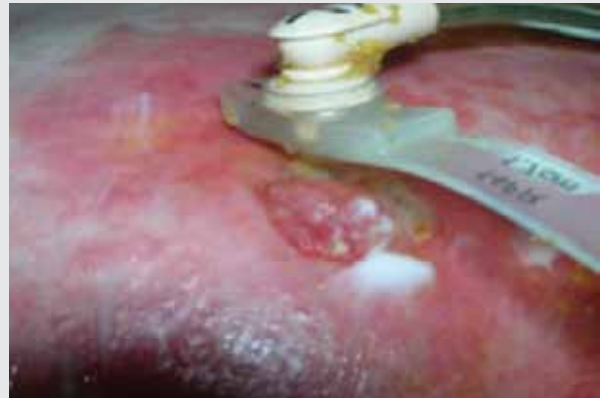

Figure 1. Gastrostomy wound before being treated with superabsorbent drainage dressings.

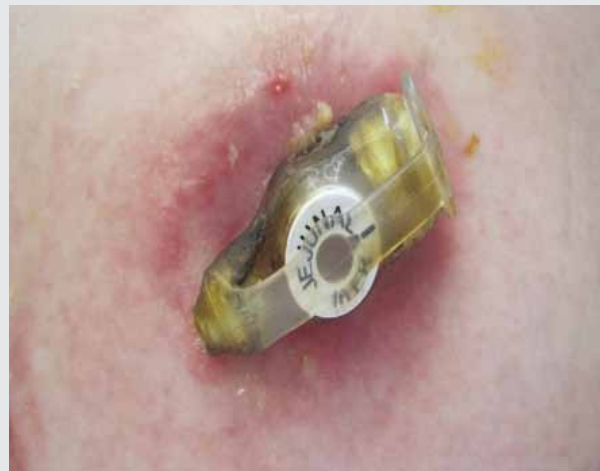

Figure 2. After one month of using superabsorbent drainage dressings.

Treating a shin wound for a patient with non-Herlitz Junctional EB

A 23-year-old man with non-Herlitz Junctional EB sustained injuries while playing football, which led to extensive wounding to both of his shins. The wounds had been present for 17 years and had been treated with topical steroids for prolonged periods, and had extended and worsened over this time. After considerable reluctance on the part of the patient, the clinical team managed to persuade him to discontinue topical steroids in view of the undesirable side effects of systemic absorption and thinning of the skin. The patient was working and was on his feet most days. Pain was not a particular feature of this wound, which was surprising. The wound appeared to have healed at times, as evidenced by the red scarred areas around the wound, which denoted areas of previous wounding. However, the scar tissue remained fragile and vulnerable and frequently broke down thereby extending the wound. Pruritus and consequent scratching contributed to breakdown of previously healed areas.

The wound bed appeared clean, if somewhat overgranulated and fragile. The wound bed was a fiery unhealthy red, and while there were no signs of infection, this was a concern. There was some maceration of the periwound skin, because of high exudate levels. There were also areas of hyperkeratosis in some areas of the periwound skin. The patient had been using two layers of silicone products for at least seven years. A sensitivity to silicone dressings had been noted in other patients with EB who had used the products for long periods. Discontinuing silicone products in some patients had been noted to lead to substantial improvements. Silicone itself is inert; however the sensitivities are thought to arise to impurities within the silicone. 'Silicone allergy' is a topic of some debate, but we based our approach on clinical experience and the fact that a dressing substitution will at worst do no harm, and at best will improve the situation.

Treatment plan

The treatment objectives were to:

- Control exudate levels
- Reduce overgranulation
- Protect the periwound skin
- Debride the hyperkeratotic areas
- Substitute a lipido-colloid dressing for the primary silicone layer
- Prevent infection.

The wound was washed with Octensian® (Schülke) at each dressing change to prevent infection and Dermovate™ NN (GSK) was applied to overgranulated areas for three days after which there was a reduction in hypergranulation tissue. 50/50 emollient was used to soften the hyperkeratotic areas and aid manual debridement with forceps. Urgotul® was used as a primary dressing to ascertain whether the patient was intolerant to the impurities in the soft silicone dressings he had been using. Urgotul® (Urgo) has atraumatic application and removal and can also assist in reducing overgranulation. Mepilex® Transfer (Mölnlycke Health Care) was used to ensure that exudate transferred away from the wound bed and the periwound skin to the secondary absorbent dressing. Release® (J&J) dressing was used as this was the patient's preference. The patient also made the decision to resign from his employment to focus on trying to heal this wound by ensuring rest and regular dressing changes. K-Band® and Tubifast® were used for retention. Cavilon™ (3M) was used to protect the periwound from maceration.

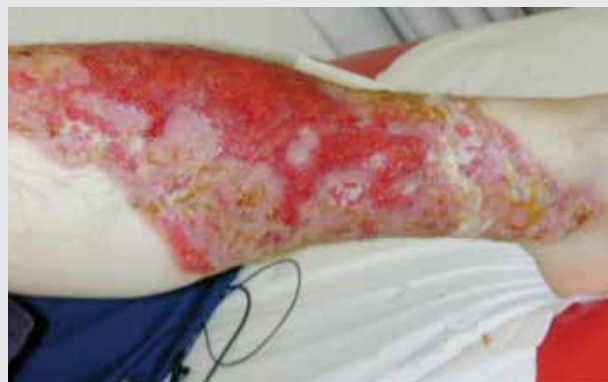

Figure 1. The patient's wound upon presentation.

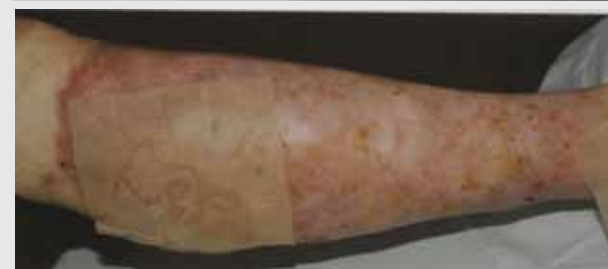
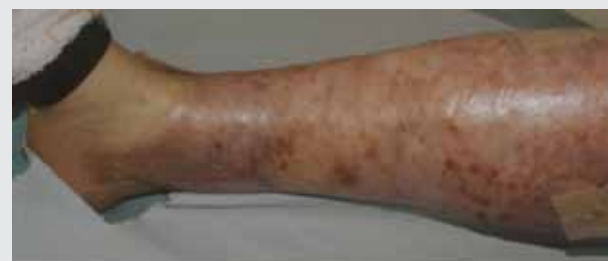
Figure 2. Eighteen months after change of dressing regimen and reduction in activity levels.

Outcomes

Initial improvement was apparent within a week using a lipido-colloid dressing in place of a soft silicone dressing. The wound bed appeared much less inflamed. The wound healed almost completely over a period of 18 months (Figure 2). A large contributory factor to the healing was undoubtedly the fact that the patient stopped work and spent time with his legs elevated and was able to carry out dressing changes more regularly. This, however, had a psychosocial cost and although the patient was very pleased with the healing achieved he became socially isolated and depressed.

Chronic head wounds in a patient with severe RDEB who had used a topical treatment for head lice

A 24-year-old woman with severe RDEB had developed chronic head wounds after an infestation with head lice. The scratching following the infestation had led to the development of extensive wounding with lice being present under encrusted areas. The wounding and inaccessibility of some of the lice made treatments with pediculicide and/or fine tooth combing inappropriate and potentially damaging. The wounds had been present and been gradually worsening for six years (Figure 1). It was not possible to accurately measure the wounds due to the fact they were so numerous and painful. The wounds were not healing because of recurrent infections (including with *Pseudomonas*) and possible biofilm formation. The wounds had heavy exudate with extreme leakage into aural canals and eyes which further contributed to local infection such as conjunctivitis. The woman's scalp was extremely sensitive and pain levels were high. She required opiates to tolerate dressing change and debridement was not a possibility due to the pain levels.

Treatment plan

The objectives of treatment were to absorb and reduce the wound exudate, debride the wounds, reduce malodour and reduce the incidence of infection. The product chosen to do this was Flaminal® Hydro (Crawford Healthcare), which is suitable for low exuding wounds and those at high risk of infection (1,2). Although these wounds had a high level of exudate the patient was unable to tolerate Flaminal® Forte which would have been the formulation of choice. It was applied as a thick layer using a soft swab on the scalp and gently smeared into the scalp wounds.

Mepitel® and Mepilex® Transfer (Mölnlycke Health Care) were chosen as Flaminal® does not adhere to these dressings and they are both well tolerated by patients with RDEB. ActiWrap® (Latex-free cohesive polyamide cohesive bandage, Activa Healthcare Ltd, an L+R company) was used to keep the dressings in place.

Outcomes

The exudate levels initially increased and dressing changes were necessary every day for the first five days. Subsequent exudate levels steadily decreased and dressing changes were reduced to every three days. The malodour decreased and the wounds began to debride. The patient commented that when applied to wounds Flaminal® Hydro had a cooling effect which improved her comfort. Granulation tissue began to appear at the wound margins and the wounds appeared cleaner. No further evidence of infection was noted. The wounds did not heal completely, however there was a remarkable improvement after four weeks of treatment with Flaminal® Hydro (Figure 2).

1. Vandenbulcke, K. et al.(2006) Evaluation of the antibacterial activity and toxicity of two new hydrogels: A pilot study. *Int J Lower Extrem Wounds* 2006; 5(2): 109-114
2. Beele H, Durante C, Kerihuel J-C, et al. (2012) Expert consensus on a new enzyme alginogel. *Wounds UK* 8(1): 64-73

This case study has been contributed by Pauline Graham-King and Karen Snelson, EB nurse specialists, St Thomas' Hospital, London, UK

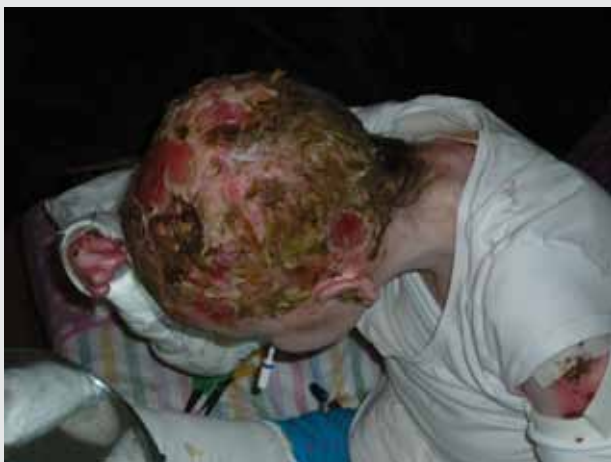

Figure 1. Wounds upon presentation.

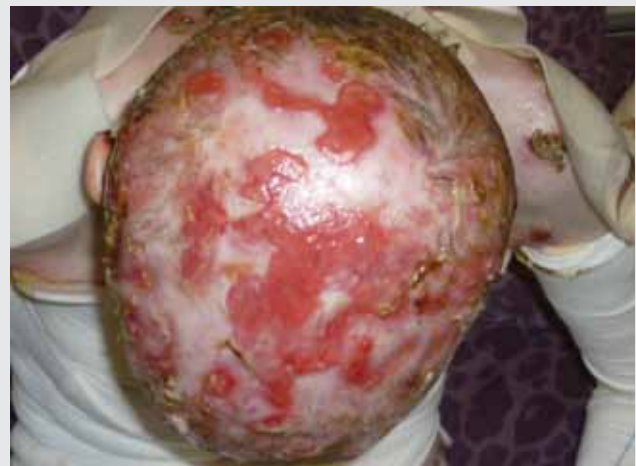

Figure 2. After four weeks of treatment with Flaminal® Hydro.

The use of a hydrogel sheet dressing in the management of pruritus and scarring in patients with EB pruriginosa

These case reports look at the use of a hydrogel sheet dressing to aid the management of two of the most troublesome symptoms of EB pruriginosa: intense unremitting pruritus and disfiguring scarring. The pruritus found in this condition is largely unresponsive to either topical or systemic treatments.

Patient 1

The 25-year-old man with recessive dystrophic EB pruriginosa had extensive, pruritic wounding. The urge to scratch disturbed his sleep, and he often aggravated previously healed areas. This problem was most marked on his shins.

Treatment plan

A hydrogel sheet dressing (Actiform® Cool, Activa Healthcare Ltd, an L+R company) was applied to the anterior aspect of the patient's lower legs. The dressing was changed daily, when he also bathed.

Outcomes

Within hours of application of the hydrogel sheet dressing the patient reported a substantial reduction in pruritus. As a result of this he scratched the area less, and if he did scratch the dressing provided a mechanical barrier that protected the fragile skin. Healing was thereby improved in this area.

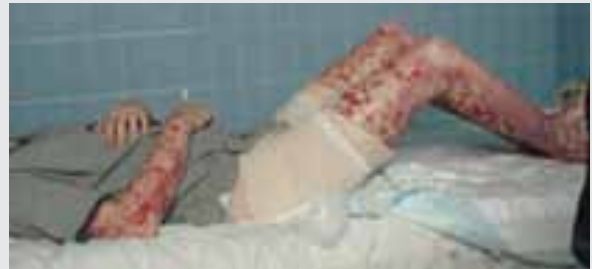

Figure 1. Patient 1 before the application of hydrogel sheet dressings.

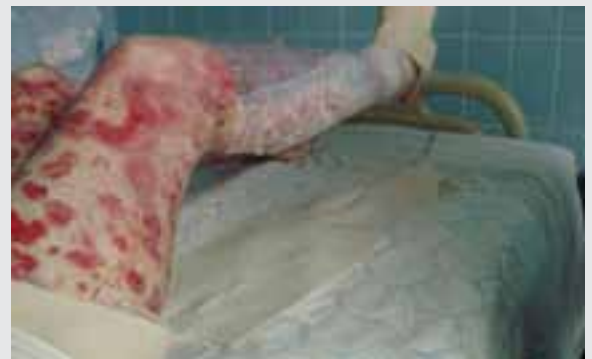

Figure 2. Patient 1 showing application of hydrogel sheet dressings.

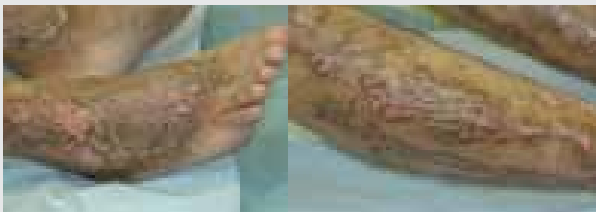

Figure 1. Patient 2 before the application of hydrogel sheet dressings.

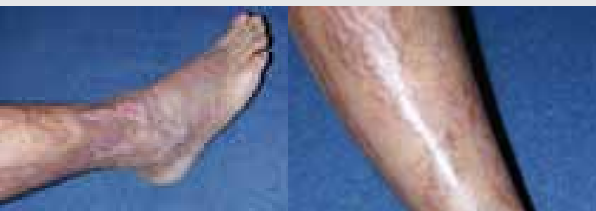

Figure 2. Patient 2 two months after commencement of treatment using sheet hydrogel dressings.

Patient 2

The patient was 54 years old with dominant dystrophic EB pruriginosa. He had a history of longstanding scarring to anterior lower legs and ankles. This was tender and 'cobblestone' like in appearance with open areas. It was intensely pruritic and the patient was sleep deprived and reported feelings of depression.

Treatment plan

A hydrogel sheet dressing (Actiform® Cool) was applied over a bland moisturiser (Diprobase®) and antibacterials (Fucibet and Crystacide) applied to open areas. The only change in management was the application of the hydrogel sheet. The dressing was left in place for three days and the patient changed it when he had a shower.

Outcome

The patient reported a dramatic reduction in pruritus over his shins. This effect occurred rapidly after application of the dressing and lasted until the next application three days later. After the patient showered he dried his skin with a towel and a large quantity of scar tissue was removed from his legs. This was thought to be as a result of the hydrogel sheet dressing having hydrated the scar tissue and the mechanical debridement action of the towel.

**In both cases the backing to the hydrogel sheet dressing was left in place to prevent the dressing becoming desiccated. Both patients had small volumes of exudate in these areas.*

(Taken from a poster presentation: Pillay E The use of a hydrogel sheet dressing in the management of pruritus and scarring. 2010; Wounds UK, Harrogate)

A fungating wound in a patient with recessive dystrophic EB — severe generalised

The patient was a 28-year-old man who had RDEB-SG with squamous cell carcinoma which developed within the left hand. Six weeks after diagnosis a never-to-heal fungating wound developed (Figure 1). The tumour measured 10x8cm and a depth of 2cm. Any treatment given would be palliative as there was extensive metastasis shown by a PET-CT scan. The patient was given palliative radiotherapy to slow the growth of this tumour.

Treatment plan

As the wound would never heal, the treatment objectives were to help the patient to maintain as good a quality of life as possible by promoting comfort and confidence by managing the wound-related symptoms. The main problems were pain, high exudate levels, odour which had caused a loss of appetite and social embarrassment, and the appearance of the wound which was causing distress to the patient and his carers.

It was decided to gently wash the wound using Prontosan® Wound Irrigation Solution (B. Braun) during the daily dressing change. This would help address the problem of bacterial colonisation that was increasing pain, odour and exudate levels. As pain and odour were particular problems it was decided to mix 10mg morphine for infection with 10g of metronidazole gel. Topical morphine has been shown to be effective in the management of wound-related pain and metronidazole gel is effective in controlling anaerobic bacteria which are, in large part, responsible for the severe odour problem associated with fungating wounds. Urgotul® (Urgo Medical) was the chosen primary dressing as this would avoid adherence of the hydrofiber secondary dressing (AQUACEL®, ConvaTec) to the wound and prevent the tumour growing through the primary dressing which would lead to further adherence. Multiple layers of AQUACEL® were used as it is soft and conformable and can cope with high levels of exudate while maintaining comfort. As a further protection against high odour levels ACTISORB® Silver 220 (Systagenix) was used as a third layer as this contains both silver and activated charcoal. As the patient was anxious about exudate leakage and possible damage to the fragile painful tumour a final layer of Mepilex® (Molnycke Health Care) was added. A K-band® (Urgo) was used for retention and Cavilon™ (3M) was applied to the surrounding skin to prevent maceration and further painful skin damage. While 'layering' of dressings is generally undesirable, the difficult management challenges presented by fungating wounds can make the use of multiple dressings unavoidable.

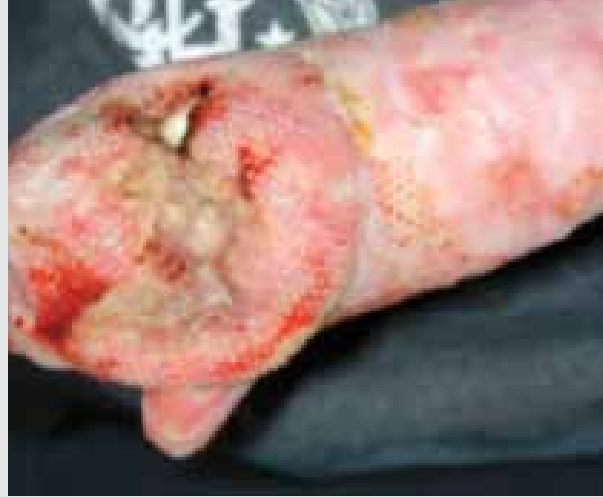

Figure 1. Fungating wound on the dorsum of the left hand three weeks after initial breaching of the skin.

Additionally patient choice plays a part, and the EB patient is frequently the final arbiter in choosing which dressings he or she will or will not use.

Limone® (Clinimed), an ostomy deodorant product, was used at dressing changes when the patient was particularly distressed by the foul odour from his wound. Supplies of an alginate dressing Kaltostat® (ConvaTec) which has haemostatic properties were kept in the patient's home in case of bleeding from the wound.

Outcomes

The dressing changes continued to be distressing because of the pain and the fact that the patient was nearing death. However, he had confidence in his dressing regimen and the wound-related symptoms were adequately controlled. The patient died at home with his family three months after the photograph above was taken (Figure 1).

Treating foot wounds in a woman with severe generalised recessive dystrophic EB and squamous cell carcinoma

A 40-year-old woman with severe generalised recessive dystrophic EB and metastatic squamous cell carcinoma with a terminal prognosis had wounds to the feet that had markedly deteriorated over a three-month period. The wounds had high exudate levels and even though she was in severe pain, the patient insisted on walking.

Treatment plan

The aim of treatment was to control pain and exudate levels and protect the intact skin from the corrosive effects of the exudate. The patient was encouraged to reduce activity levels and elevate her feet as much as possible.

The primary dressing chosen was Biatain® Ibu Soft Hold Foam (Coloplast). The foam dressing was impregnated with ibuprofen and the dressing was changed every 12 hours to ensure sufficient absorption of exudate and sufficient release of ibuprofen to adequately control pain. Soft foam padding was put in the patient's shoes. K-Band® and Tubifast® were used for retention. Cavilon™ (3M) was applied to macerated areas.

Outcomes

At first when the dressings were being changed every 24 hours the pain increased markedly from two to 10 on a 10-point visual analogue scale at about the 14th hour. In view of the high exudate levels it was felt that the ibuprofen was being absorbed very quickly leading to the escalation of pain. The ibuprofen impregnated foam was then changed every 12 hours and better pain relief was achieved. Little healing took place but pain levels were reduced in the last few weeks of the patient's life.

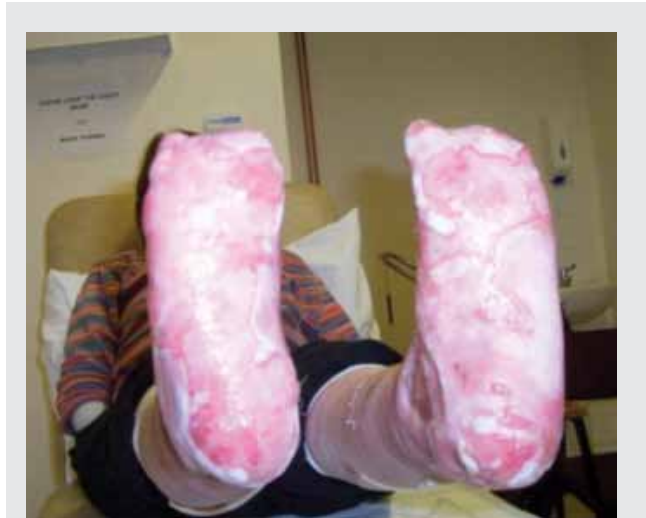

Figure 1. Four months before the patient died.

1. Fine JD, Eady RAJ, Bauer EA, et al. The classification of inherited epidermolysis bullosa (EB): report of the Third International Consensus meeting on Diagnosis and Classification of EB. *J Am Acad Dermatol* 2008; 58: 931-50.
2. Haynes L. Nutrition for children with EB. *Dermatol Clin* 2010; 28: 289-301.
3. Fine JD, Johnson LB, Weiner M, et al. Epidermolysis bullosa and the risk of life-threatening cancers: The National EB Registry experience, 1986-2006. *J Am Acad Dermatol* 2009; 60(2): 203-11.
4. Hintner H, Stingl G, Schuler G, et al. Immunofluorescence mapping of antigenic determinants within the dermal-epidermal junction in the mechanobullous diseases. *J Invest Dermatol* 1981; 76(92): 113-8.
5. Uitto J, Richard G, McGrath JA. Diseases of epidermal keratins and their linker proteins. *Exp Cell Res* 2007; 313(10): 1995-2009.
6. Fine JD. Premature death in EB. In: Fine JD, Hintner H, eds. *Life with Epidermolysis Bullosa (EB): Aetiology, Diagnosis, Multidisciplinary Care and Therapy*. Wien-New York: Springer, 2008; 197-203.
7. Nakano A, Chao SC, Pulkkinen L, et al. Laminin 5 mutations in junctional epidermolysis bullosa: molecular basis of Herlitz vs. non-Herlitz phenotypes. *Hum Genet* 2002; 110(1): 41-51.
8. Atherton DJ, Denyer J. Epidermolysis bullosa: an outline for professionals. 2002; Debra, Berkshire.
9. Van den Bergh F, Giudice GJ. BP180 (type XVII collagen) and its role in cutaneous biology and disease. *Adv Dermatol* 2003; 19: 37-71.
10. Jo-David Fine, Johnson LB, WeinernM, et al. Epidermolysis bullosa and the risk of life-threatening cancers: The National EB Registry experience, 1986-2006. *J Am Acad Dermatol* 2009; 60(2): 203-1.
11. Pillay E. Epidermolysis Bullosa: Causes, Presentation and Complications. *Br J Nurs* 2008; 17(5): 13-26.
12. Greider Jr JL, Flatt AE. Care of the hand in recessive epidermolysis bullosa. *Plast Reconstr Surg* 1983; 72: 222-8.
13. Forsma SA, Maathuis CBG, Robinson PH, et al. Postoperative hand treatment in children with recessive dystrophic epidermolysis bullosa. *J Hand Ther* 2008; 21(1): 80-4.
14. Ashton GH. Kindler Syndrome. *Clin Exp Dermatol* 2004; 29: 116-21.
15. Emanuel PO, Rudkoff D, Phelps RG. Aggressive squamous cell carcinoma in Kindler syndrome. *Skinmed* 2006; 5: 305-7.
16. Caldwell-Brown D, Gibbons S, Reid M. *Nursing Aspects of Epidermolysis Bullosa: A Comprehensive Approach. Basic and Clinical Aspects*. Springer-Verlag, 1992: 281-94.
17. Abercrombie E, Mather C, Hon J, Graham-King P, Pillay E. Recessive dystrophic epidermolysis bullosa. Part 2: care of the Adult Patient. *Br J Nurs* 2008; 17(6) Suppl: S6-S20.
18. Denyer J. Wound management for children with epidermolysis bullosa. In: *Epidermolysis Bullosa: Part II - Diagnosis and Management*. Guest Editor: Murrell DF, Consulting Editor Thiers BH. *Dermatol Clin* 2010; 28: 257-64.
19. Laimer M, Lanschuetzer CM, Diem A et al. Herlitz Junctional Epidermolysis Bullosa. In: *Epidermolysis Bullosa: Part II - Diagnosis and Management*. Guest Editor: Murrell DF, Consulting Editor Thiers BH. *Dermatol Clin* 2010; 28: 55-60.
20. Mather C, Graham-King P. Silver fibre sock can make a difference in managing EB simplex. Poster presentation. Wounds UK, 2008, Harrogate.
21. Denby SG, Al-Enezi T, Sultan A, Chittock J, Kennedy K, Cork MJ. The effect of aqueous cream BP on the skin barrier with volunteers with a previous history of atopic dermatitis. *Br J Dermatol* 2011; 165(2) 329-34. doi:10.1111/j.1365-2133.10395.x Epub 2011 Jul 11
22. Denyer J. Wound management for children with epidermolysis bullosa. In: *Epidermolysis Bullosa: Part II - Diagnosis and Management*. Guest Editor: Murrell DF, Consulting Editor Thiers BH. *Dermatol Clin* 2010; 28: 257-64.
23. Fine N, Johnson LB, Weiner M, et al. Pseudosyndactyly and musculoskeletal contractures in inherited epidermolysis bullosa. *J Hand Surg* 2005; 30: 1: 14-22
24. Denyer J. Reducing pain during the removal of adhesive and adherent products. *Br J Nurs* 2011; 20(15): S28,S30-5.
25. Fine JD, Johnson LB, Weiner M, et al. Genitourinary complications of inherited EB. *J Urology* 2004; 172(5) Part 1: 2040-44.
26. Martinez A, Mellerio J. Osteopenia and osteoporosis in epidermolysis bullosa. In: *Epidermolysis Bullosa: Part II — Diagnosis and Management*. Guest Editor: Murrell DF, Consulting Editor Thiers BH. *Dermatol Clin* 2010; 28: 353-5.
27. Fine JD, Mellerio JE. Extracutaneous manifestations and complications of inherited Epidermolysis bullosa: Part 11 Other organs. *J Am Acad Derm* 2009; 61(3): 387-402.
28. Colomb V, Bourdon-Lannoy E, Lambe C, et al. Nutritional outcome in children with severe generalized recessive dystrophic epidermolysis bullosa: a short- and long-term evaluation of gastrostomy and enteral feeding. *Br J Dermatol* 2012; 166(2): 354-61.
29. Haynes L. Epidermolysis bullosa. In: *Clinical paediatric dietetics, 3rd edition*. Shaw V, Lawson M, eds. Oxford: Blackwell Science 2007; 482-96.
30. Hubbard L, Haynes L, Skylar M, et al. The challenges of meeting nutritional requirements in children and adults with epidermolysis bullosa; proceedings of a multidisciplinary team study day. *Clin Exp Dermatol* 2011; 36(6): 579-83.
31. Azizkhan R, Stehr W, Cohen AP, et al. Esophageal strictures in children with recessive dystrophic epidermolysis bullosa, an 11 year experience with fluoroscopically guided balloon dilatation. *J Pediatr Surg* 2006; 41: 55-60.
32. Fine JD, Johnson LB, Weiner M, et al. Assessment of mobility, activities and pain in different subtypes of epidermolysis bullosa. *Clin Exp Dermatol* 2004; 29(2): 122-7.
33. Denyer J. Management of the infant with epidermolysis bullosa. *Infant* 2009; 5(6): 170.
34. Moss K. Contact at the borderline: psychoanalytic psychotherapy with EB patients. *Br J Nurs* 2008; 17(7): 449-55.
35. Dures E, Morris M, Gleeson K, Rumsey N. 'You're whatever the patient needs at the time'. *Chronic Illness* 2010; 6: 215-27.
36. Arbuckle AH. Bathing for individuals with epidermolysis bullosa In: *Epidermolysis Bullosa: Part II Diagnosis and Management*. Guest Editor: Murrell DF, Consulting Editor Thiers BH. *Dermatol Clin* 2010; 28: 265-6.
37. Schober-Flores C. Wound care for the non-infected and infected wound. *J Dermatol Nurses Association* 2009; 1(1): 21-28.
38. Huang JT, Abrams M, Tlougan B, et al. Pediatrics. Treatment of *Staphylococcus aureus* colonisation in atopic dermatitis decreases disease severity. *Pediatrics* 2009; 123(5): e808-814.
39. National Eczema Society. Ask-the-experts session. NES Conference, 2010. <http://www.eczema.org>
40. Arbuckle HA. Bathing for individuals with epidermyolysis bullosa. *Dermatol Clin* 2010; 28(2): 256-6.
41. Fine JD, Mellerio JE. Extracutaneous manifestations and complications of inherited epidermolysis bullosa. Part 1. Epithelial associated tissues. *J Am Acad Dermatol* 2009; 61(3): 367-84.
42. NHS Clinical Knowledge Summary. Evidence of resistance by head lice to traditional insecticides, 2010. Available from: http://www.cks.nhs.uk/head_lice/evidence/supporting_evidence/resistance_to_traditional_insecticides#-402487
43. Thomas DR, McCarroll L, Roberts R, et al. Surveillance of insecticide resistance in head lice using biochemical and molecular methods. *Arch Dis Childhood* 2006; 91(9): 777-8.
44. Glaziou P, Nyguyen LN, Moulia-Pelat JP, et al. Efficacy of ivermectin for the treatment of head lice (pediculosis capitis). *Trop Med Parasitol* 1994; 45: 253-4.
45. Abercrombie EM, Mather CA, Hon J, et al. Recessive dystrophic epidermolysis bullosa. Part 2: care of the adult patient. *Br J Nurs* 2008; 17(6)
46. Pillay E. Epidermolysis bullosa. Part 1: causes, presentation and complications. *Br J Nurs* 2008; 17(5): 292-6.
47. WUWHS. Principles of best practice: *Wound Exudate and the Role of Dressings*. A Consensus Document 2007; MEP Ltd, London. Available from: www.woundsinternational.com
48. Phillips PL, Wolcott RD, Fletcher J, Schultz GS. Biofilms Made Easy. *Wounds International* 2010; 1(3). Available from: www.woundsinternational.com
49. European Wound Management Association (EWMA). Position Document: *Wound Bed Preparation in Practice*. 2004. MEP Ltd: London. Available from: www.woundsinternational.com

50. Dellambra E, Vailly J, Pellegrini G, et al. Corrective transduction of human epidermal stem cells in laminn-5 dependent junctional epidermolysis bullosa. *Human Gene Ther* 1998; 9(9): 1359-70.
51. Schultz GS, Sibbald RG, Falanga V, et al. Wound bed preparation: a systematic approach to wound management. *Wound Repair Regen* 2003; 11: 1-28.
52. Mellerio JE. Infection and colonization in epidermolysis bullosa. *Dermatol Clin* 2010; 28(2): 267-9.
53. Enoch S, Price P. Should alternative endpoints be considered to evaluate outcomes in chronic recalcitrant wounds? *World Wide Wounds* 2004 (Oct). Available from: <http://www.worldwidewounds.com/2004/october/Enoch-Part2/Alternative-Endpoints-To-Healing.html>
54. Fletcher J. Care of a patient with dystrophic epidermolysis bullosa. *J Wound Care* 1995; 4(1): 20-22.
55. Fine JD, Bauer A, McGuire J, Moshell A. Cancer and inherited epidermolysis bullosa. In: *Epidermolysis Bullosa*. 1999; John Hopkins University Press, Baltimore, MA: 175-92.
56. Venugopal SS, Murrell DF. Treatment of skin cancers in epidermolysis bullosa. *Dermatol Clin* 2010; 28(2): 283-7.
57. Fine JD. Possible role for sentinel node biopsy in the management of squamous cell carcinomas in inherited epidermolysis bullosa. *Arch Dermatol* 2004; 140(8): 75-9.
58. Hampton S. Odour management from a nursing perspective. *Br J Comm Nurs* 2008; 13 (6): Wound Care: S31-2, S34, S36.
59. Mc Manus J. Principles of skin and wound care: the palliative approach. *End of Life Care* 2007; 1(1) : 8-19
60. Grocott P. The palliative management of fungating malignant wounds. *J Wound Care* 2000; 9(1): 4-9
61. Naylor W. Part 2: Symptom self-assessment in the management of fungating wounds. *World Wide Wounds* 2002. Available from: <http://www.worldwidewounds.com/2002/july/Naylor-Part2/Wound-Assessment-Tool.html>
62. Le Bon B, Zeppetella G, Higgginson I. Effectiveness of topical administration of opioids in palliative care. A systematic review. *J Pain Symptom Manage* 2005; 37(5): 913-7.
63. Ribeiro M, Joel S, Zeppetella G. The bioavailability of morphine applied topically to cutaneous ulcers. *J Pain Symptom Manage* 2004; 27(5): 434-9.
64. Pillay E, Hon J. The use of a low-air loss pressure relieving surface in the management of epidermolysis bullosa. Poster Presentation. 2007; Wounds UK, Harrogate, UK.
65. Pereira J, Phan T. Management of bleeding in patients with advanced cancer. *Oncologist* 2004; 9(5): 561-70.